The anatomy of the quadrilateral space with reference to quadrilateral space syndrome

Damian McClelland, FRCSEd (Tr and Orth),[a] and Anastasios Paxinos, FRACS,[b]
Staffordshire, United Kingdom; and Windsor, Victoria, Australia

Quadrilateral space syndrome is a rare condition in which the contents of the quadrilateral space, the axillary nerve and the posterior circumflex humeral artery, are compressed, leading to vague symptoms of shoulder pain, tenderness over the quadrilateral space on palpation, and teres minor and deltoid denervation. Fibrous bands within the quadrilateral space are often cited in the literature as a cause of compression in quadrilateral space syndrome; however, Cahill and Palmer did not see these bands in cadaveric dissection. These are postulated to cause compression of the quadrilateral space contents in abduction and external rotation of the shoulder. To clarify the anatomic features that may predispose the development of quadrilateral space syndrome, 16 cadaveric shoulders were studied. Dissection revealed that fibrous bands are a common finding in the quadrilateral space, being present in 14 of 16 shoulders. The most common site for a fibrous band was between the teres major and the long head of the triceps. Where the bands were present, both internal and external rotation of the shoulder caused a reduction in the cross-sectional area of the quadrilateral space. (J Shoulder Elbow Surg 2008;17:162-164.)

Quadrilateral space syndrome was described by Cahill and Palmer[3] in 1983 as presenting as poorly localized pain and paresthesia affecting the shoulder and upper limb with discrete point tenderness, which was "always found" posteriorly over the quadrilateral space. They observed that abduction and external rotation or forward flexion aggravated the symptoms of pain and paresthesia. Although the true incidence of quadrilateral space syndrome is unknown, 0.8% of patients undergoing a shoulder magnetic resonance imaging (MRI) scan had evidence of findings consistent with a diagnosis of quadrilateral space syndrome.[6] The diagnosis of quadrilateral space syndrome, however, was an incidental finding in many patients presenting with shoulder pain but without symptoms of quadrilateral space syndrome.

The quadrilateral space is bounded by the teres minor superiorly, the surgical neck of the humerus laterally, the long head of triceps medially, and the upper border of teres major inferiorly. It contains the axillary nerve and the posterior circumflex humeral artery. The axillary nerve, after travelling along the anteroinferior aspect of the subscapularis muscle, winds around the neck of the humerus into the quadrilateral space. In this region, it divides into 2 trunks: an anterior trunk that supplies the middle and anterior fibers of the deltoid and the posterior trunk that carries a motor supply to the teres minor and the posterior fibers of the deltoid. A sensory branch travels with the posterior trunk and supplies the so-called regimental badge area over the lateral aspect of the upper arm. The posterior circumflex humeral artery usually divides, after entering the quadrilateral space, into similar branches to the nerve, with anterior and posterior branches following the anterior and posterior trunks of the axillary nerve.

Essentially, the quadrilateral space syndrome can be caused by any condition that reduces the cross-sectional area of the quadrilateral space and consequently causes compression of the contents and produces symptoms. Fibrous bands[3,8,11] are one of the most commonly cited causes of compression of the contents of the quadrilateral space. Cahill and Palmer[3] were the first to attribute compression of quadrilateral space contents to fibrous bands at surgery, but they stated that they were unable to identify any fibrous bands in cadaveric dissections. McKowen and Voorrhies[11] and Francel et al[8] have reported the presence of fibrous bands in-vivo during dissection of the quadrilateral space, and Mckowen and Voorrhies[11] noted that these bands of connective tissue were entrapping the neurovascular structures. The location of these fibrous bands is poorly described in the literature, however.[3,8,11] To further delineate the nature of the fibrous bands within the quadrilateral space, we performed a cadaveric dissection study.

From the [a]University Hospital of North Staffordshire; and [b]Melbourne Orthopaedic Group.

Reprint requests: D. McClelland, 39 Forge Lane, Norton-in-Hales, Shropshire,TF9 4QN United Kingdom (E-mail: *d.mcclelland@talk21.com*).

1058-2746/2008/$34.00
doi:10.1016/j.jse.2007.05.013

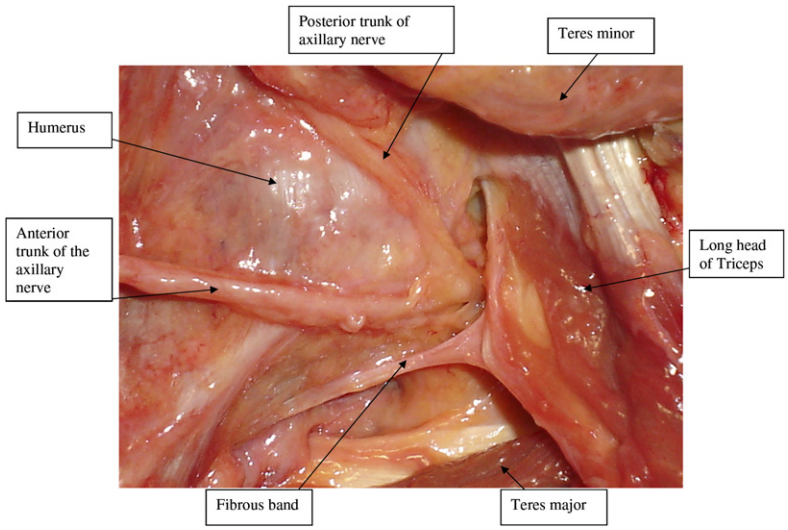

Figure 1 The photograph shows the quadrilateral space of a left shoulder viewed from the posterior aspect. The boundaries of the quadrilateral space are identifiable (the shaft of humerus, teres minor, long head of triceps and teres major). The fibrous sling can be seen arising from the long head of triceps and passing to the humerus. In this case, the sling is not intimately attached to teres major but lies just above it. The posterior trunk of the axillary nerve is visible supplying the teres minor.

MATERIALS AND METHODS

Permission for the study was obtained from the Department of Anatomy and Cell Biology at The University of Melbourne. Both shoulders of 8 fresh cadavers (3 men, 5 women) preserved by using cold storage at 4°C were dissected, which provided 16 dissection specimens. Age at time of death was unknown.

The cadavers were placed in a prone position, and a T-shaped incision was used to expose the posterior aspect of the shoulder and axilla. The incision began at the medial edge of the scapular spine and followed the posterior-inferior border of the deltoid muscle laterally, extending along the posterior border of the axilla. The skin and superficial fascia were dissected from the underlying muscle, and the cutaneous branch of the axillary nerve was identified as it emerged from deep to the posterior border of the deltoid. The posterior attachments of the deltoid were released from the spine of the scapula and the fascia overlying the infraspinatus. The posterior aspect of the deltoid was then elevated to reveal the motor branches of the axillary nerve. The motor branch to the teres minor was identified and followed proximally to the quadrilateral space.

In each case, the sex of the patient and the side of the limb were noted. The site of origin of the nerve to the teres minor was recorded, as was the relationship of the nerve to the posterior circumflex humeral artery within the space. The presence and position of any fibrous bands within the space were identified. The degree of quadrilateral space compression by the fibrous bands was noted during passive internal and external rotation with the shoulder abducted to 90°. Compression was noted by placing a fingertip into the quadrilateral space. Further quantification of compression was thought to add little because the cadaveric tissue had little or no resting tone, which made further quantification of compression unreliable. The presence of any additional lesion was sought. Finally, the teres minor and posterior fibers of the deltoid were transected and the presence or absence of macroscopic fatty degeneration noted.

RESULTS

The nerve to the teres minor was isolated in all cadavers and was found to have branched either in or before the quadrilateral space in 15 specimens; in the remaining shoulder, it branched after entering the quadrilateral space. The posterior circumflex artery was a single vessel within the space in 15 of the 16 shoulders. In only 1 shoulder did the posterior circumflex humeral artery divide before the quadrilateral space.

In one cadaver, no identifiable fascial thickening existed over the long head of triceps or between the long head of the triceps and the teres major in either arm. Fibrous bands were identifiable both visually and by palpation in 14 of the specimens. The fibrous bands were multiple in most cases and in different directions. In 11 shoulders, the most significant fibrous band consisted of a fascial thickening overlying the long head of the triceps, which ran from the proximal end of the long head of the triceps to the teres major and onto the humerus, forming a sling adjacent to the axillary nerve (Figure 1). If present on 1 side, the fibrous bands were present on the contralateral side in all cases.

Rotation of the shoulder was tested with the shoulder abducted to 90°. The quadrilateral space reduced in volume with rotation in 11 of 16 shoulders. The

fibrous sling between the teres major and the long head of the triceps (Figure 1) tightened in rotation in 11 of the 14 shoulders where a sling was present. This fibrous sling was tightest in external rotation in 7 of 16 shoulders and in internal rotation in 4 shoulders. No vascular abnormalities or other space occupying lesions were noted in any cadaver.

Macroscopic fatty change was noted in 3 shoulders. One of these shoulders did not have fascial bands within the quadrilateral space and 2 did.

DISCUSSION

The exact prevalence of quadrilateral space syndrome is unknown. The diagnostic criteria are debated, and which investigation is best to aid diagnosis is controversial.[6,7] The investigation of choice from the original report by Cahill and Palmers[3] was angiography. They suggested that a position of abduction and external rotation would demonstrate significant compression of the contents of the quadrilateral space.[3,5] However, subsequent investigation with magnetic resonance angiogram has shown that this position causes compression of the axillary contents in normal, asymptomatic individuals.[12] Nerve conduction studies and electromyography have also been used to investigate quadrilateral space syndrome[2,3,4] and are considered to be specific. The appearance of denervation changes on MRI affecting the teres minor muscle is considered to confirm the diagnosis of quadrilateral space syndrome.[6] The incidence of teres minor denervation is 0.8% in patients undergoing shoulder MRI scans.[6] However, it was noted that most of these patients had other shoulder pathology, in addition to their quadrilateral space syndrome, and that quadrilateral space syndrome was not suspected in most of these patients before MRI scan.

The long head of the triceps has a thick fascial layer proximally as it approaches the infraglenoid tubercle. In most dissections in this study, this fascial layer became a distinct fibrous band that ran across to the teres major, forming a sling. It was this sling that became tight in both internal and external rotation of the shoulder with the arm abducted to 90°. External rotation of the shoulder in 90° of abduction is said to provoke the symptoms of quadrilateral space syndrome.[3,4] In this study, however, internal rotation also tended to cause compression when the shoulder was in an abducted position. This is as one would expect, because the twisting of a structure causes it to shorten. If that structure surrounds a space, it is likely to cause a reduction in area of that space and potential compression.

Reported anatomic causes of quadrilateral space syndrome include glenoid labral cysts,[13] a ganglion,[10] muscle hypertrophy,[8] and a spike of bone after a scapular fracture[1]; however, the most commonly cited cause of compression is fibrous bands.[3,8,11] In contradiction to the findings of Cahill and Palmer,[3] this study has demonstrated that fibrous bands are present within the quadrilateral space in cadavers, suggesting that this is a normal finding. This study has also identified a relatively constant fibrous band, adjacent to the axillary nerve in the quadrilateral space, which may be responsible for compression of the axillary nerve in those individuals predisposed to developing quadrilateral space syndrome. In light of these findings, we suggest a provocation test for quadrilateral space syndrome: with the shoulder abducted to 90°, it is fully rotated first internally and then externally to provoke compression of the contents of the quadrilateral space and produce symptoms.

We would like to thank Ian Tew from Zimmer for his help with this project and Ian Bouch from the Department of Anatomy and Cell Biology at The University of Melbourne for his assistance during this study. We would also like to thank Mr PBM Thomas, and Mr R Wade Consultant Orthopaedic Surgeons at The University Hospital of North Staffordshire, UK for kindly reviewing the manuscript before submission.

REFERENCES

1. Amin MF, Berst M, el-Khoury GY. An unusual cause of the quadrilateral space impingement caused by a bone spike. Skeletal Radiol 2006;35:956-8.
2. Bredella MA, Tirman PFJ, Fritz RC, Wischer TK, Stork A, Genant HK. Denervation syndromes of the shoulder girdle: MR imaging with electrophysiologic correlation. Skeletal Radiol 1999; 28:567-72.
3. Cahill BR, Palmer RE. Quadrilateral space syndrome. J Hand Surg (Am) 1983;8:65-9.
4. Chautems RC, Glauser T, Waeber-Fey MC, Rostan O, Barraud GE. Quadrilateral space syndrome: case report and review of the literature. Ann Vasc Surg 2000;14:673-6.
5. Cormier P, Matalon T, Wolin P. Quadrilateral Space Syndrome: a rare cause of shoulder pain. Radiology 1988;167:797-8.
6. Cothran RL Jr, Helms C. Quadrilateral space syndrome: incidence of imaging findings in a population referred for MRI of the shoulder. AJR Am J Roentgenol 2005;184:989-92.
7. Dugas JR, Weiland AJ. Vascular pathology in the throwing athlete. Hand Clin 2000;16:477-85.
8. Francel TJ, Dellon AL, Campbell JN. Quadrilateral space syndrome: diagnosis and operative decompression technique. Plast Reconstr Surg 1991;87:911-6.
9. Hoskins WT, Pollard HP, McDonald AJ. Quadrilateral space syndrome: a case study and review of the literature. Br J Sports Med 2005;39:e9.
10. Ishima T, Usui M, Satoh E, Sakahashi H, Okamura K. Quadrilateral space syndrome caused by a ganglion. J Should Elb Surg 1998;7:80-2.
11. McKowen HC, Voorrhies RM. Axillary nerve entrapment in the quadrilateral space: a case report. J Neurosurg 1987;66:932-4.
12. Mochizuki T, Isoda H, Masui T, et al. Occlusion of the posterior humeral circumflex artery: detection with MR angiography in healthy volunteers and in a patient with quadrilateral space syndrome. AJR Am J Roentgenol 1994;163:625-7.
13. Robinson P, White LM, Lax M, Salonen D, Bell RS. Quadrilateral space syndrome caused by glenoid labral cyst. AJR Am J Roentgenol 2000;175:1103-5.
14. Sofka CM, Lin J, Feinberg J, Potter HG. Teres minor denervation on routine magnetic resonance imaging of the shoulder. Skeletal Radiol 2004;33:514-8.