

ADVERTISEMENT



J Brock [Account Settings](#) | [Log Out](#)

emedicine[®]
from WebMD

[HOME](#) | [SPECIALTIES](#) | [REFERENCE CENTERS](#)

Search: eMedicine Clinical Reference, Drug Reference, MEDLINE, and more

You are in: [eMedicine Specialties](#) > [Neurology](#) > [Introductory Topics](#)

[Email to a colleague](#)

Cauda Equina and Conus Medullaris Syndromes

Article Last Updated: Jan 17, 2007

AUTHOR AND EDITOR INFORMATION

Section 1 of 11

[Next](#) >

[Authors and Editors](#) [Introduction](#) [Clinical](#) [Differentials](#) [Workup](#) [Treatment](#) [Medication](#)
[Follow-up](#) [Miscellaneous](#) [Multimedia](#) [References](#)

Author: [Segun T Dawodu, MD, FAAPMR, FAANEM, CIME, DipMI\(RCSed\)](#), Former Clinical Instructor, Mount Sinai Medical School, Current Director, Pain and Injuries Rehabilitation Services, [PMRehab Pain & Sports Medicine Associates](#)

Segun T Dawodu is a member of the following medical societies: [American Academy of Physical Medicine and Rehabilitation](#), [American Association of Neuromuscular and Electrodiagnostic Medicine](#), [American College of Sports Medicine](#), [American Medical Association](#), [American Medical Informatics Association](#), [Association of Academic Physiatrists](#), [International Society of Physical and Rehabilitation Medicine](#), and [Royal College of Surgeons of England](#)

Coauthor(s): [Nicholas Y Lorenzo, MD](#), Chief Editor, eMedicine Neurology; Consulting Staff, Neurology Specialists and Consultants

Editors: [Milind J Kothari, DO](#), Professor and Vice-Chair for Education and Training, Department of Neurology, Pennsylvania State University College of Medicine; Consulting Staff, Department of Neurology, Hershey Medical Center; [Francisco Talavera, PharmD, PhD](#), Senior Pharmacy Editor, eMedicine; [James H Halsey, MD](#), Professor, Department of Neurology, University of Alabama Medical Center; [Selim R Benbadis, MD](#), Professor, Director of Comprehensive Epilepsy Program, Departments of Neurology and Neurosurgery, University of South Florida School of Medicine, Tampa General Hospital; [Nicholas Y Lorenzo, MD](#), Chief Editor, eMedicine Neurology; Consulting Staff, Neurology Specialists and Consultants

[Author and Editor Disclosure](#)

Synonyms and related keywords: lower spinal cord injury, compressive lumbosacral polyradiculopathy, cauda equina syndrome, conus medullaris syndrome, spinal cord compression, back pain, spinal cord injury, upper motor neuron symptoms, UMN symptoms, lower motor neuron symptoms, LMN symptoms, spinal cord syndromes

ADVERTISEMENT

Quick Find

[Authors & Editors](#)
[Introduction](#)
[Clinical](#)
[Differentials](#)
[Workup](#)
[Treatment](#)
[Medication](#)
[Follow-up](#)
[Miscellaneous](#)
[Multimedia](#)
[References](#)

Related Articles

[Acute Inflammatory Demyelinating Polyradiculoneuropathy](#)
[Alcohol \(Ethanol\) Related Neuropathy](#)
[Amyotrophic Lateral Sclerosis](#)
[Chronic Inflammatory Demyelinating Polyradiculoneuropathy](#)
[Dermatomyositis/Polymyositis](#)
[Diabetic Neuropathy](#)
[Femoral Mononeuropathy](#)
[HIV-1 Associated Distal Painful Sensorimotor Polyneuropathy](#)
[HIV-1 Associated Multiple Mononeuropathies](#)
[HIV-1 Associated Myopathies](#)
[HIV-1 Associated Neuromuscular Complications \(Overview\)](#)
[Multiple Sclerosis](#)
[Neurosarcoidosis](#)
[Pathophysiology of Chronic Back Pain](#)

[Spinal Cord Hemorrhage](#)

[Spinal Cord Infarction](#)

[Spinal Cord Trauma and Related Diseases](#)


[Spinal Epidural Abscess](#)

[Syringomyelia](#)

[Traumatic Peripheral Nerve Lesions](#)

[Tropical Myeloneuropathies](#)

ADVERTISEMENT



Review case studies discussing the onset of acquired hemophilia in middle-aged women

[Learn more](#)

| Patient Education |
|---|
| Erectile Dysfunction Center |
| Impotence/Erectile Dysfunction Introduction |
| Impotence/Erectile Dysfunction Causes |
| Impotence/Erectile Dysfunction Medical Treatment |
| Impotence/Erectile Dysfunction Surgical Treatment |
| Erectile Dysfunction FAQs |

INTRODUCTION

Section 2 of 11 [Back](#) [Top](#) [Next](#)

[Authors and Editors](#) [Introduction](#) [Clinical](#) [Differentials](#) [Workup](#) [Treatment](#) [Medication](#)
[Follow-up](#) [Miscellaneous](#) [Multimedia](#) [References](#)

Background

The spinal cord tapers and ends at the level between the first and second lumbar vertebrae in an average adult. The most distal bulbous part of the spinal cord is called the conus medullaris, and its tapering end continues as the filum terminale. The upper border of the conus medullaris is often not well defined. Distal to this end of the spinal cord is a collection of nerve roots, which are horsetail-like in appearance and hence called the cauda equina (Latin for horse's tail). These nerve roots constitute the anatomic connection between the central nervous system (CNS) and the peripheral nervous system (PNS). They are arranged anatomically according to the spinal segments from which they originated and are within the cerebrospinal fluid (CSF) in the subarachnoid space with the dural sac ending at the level of second sacral vertebra.

Pathophysiology

The conus medullaris part of the spinal cord obtains its blood supply primarily from 3 spinal arterial vessels—the anterior median longitudinal arterial trunk and 2 posterolateral trunks. Less prominent sources of blood supply include radicular arterial branches from the aorta, lateral sacral arteries, and the fifth lumbar, iliolumbar, and middle sacral arteries. The latter contribute more to the vascular supply of the cauda equina, although not in a segmental fashion, unlike the blood supply to the peripheral nerves. The nerve roots may also be supplied by diffusion from the surrounding CSF. Moreover, a proximal area of the nerve roots may have a zone of relative hypovascularity.

In understanding the pathological basis of any disease involving the conus medullaris, keep in mind that this structure constitutes part of the spinal cord (the distal part of the cord) and is in proximity to the nerve roots. Thus, injuries to this area often yield a combination of upper motor neuron (UMN) and lower motor neuron (LMN) symptoms and signs in the dermatomes and myotomes of the affected segments. On the other hand, a cauda equina lesion is a LMN lesion because the nerve roots are part of the PNS. Cauda equina and conus medullaris syndromes are classified as clinical syndromes of the spinal cord; epidemiological data on the 2 syndromes are often not available separately from the general data on spinal cord injury.

Frequency

United States

Frequency is determined by the underlying etiology. Multiple conditions can result in a cauda equina or conus medullaris syndrome as outlined later in this article.

Mortality/Morbidity

Morbidity and especially mortality rates are determined by the underlying etiology. Multiple conditions can result in cauda equina or conus medullaris syndrome, as outlined later in this article.

CLINICAL

Section 3 of 11 [\[Back Top Next\]](#)

[Authors and Editors](#) [Introduction](#) [Clinical](#) [Differentials](#) [Workup](#) [Treatment](#) [Medication](#)
[Follow-up](#) [Miscellaneous](#) [Multimedia](#) [References](#)

History

The history of onset, the duration of symptoms, and the presence of other features or symptoms could point to the possible causes. Patients can present with symptoms of isolated cauda equina syndrome, isolated conus medullaris syndrome, or a combination. The symptoms and signs of cauda equina syndrome tend to be mostly LMN in nature, while those of conus medullaris syndrome are a combination of LMN and UMN effects (Table 1).

Table 1. Symptoms and Signs of Conus Medullaris and Cauda Equina Syndromes

| | Conus Medullaris Syndrome | Cauda Equina Syndrome |
|----------------------------|--|---|
| Presentation | Sudden and bilateral | Gradual and unilateral |
| Reflexes | Knee jerks preserved but ankle jerks affected | Both ankle and knee jerks affected |
| Radicular pain | Less severe | More severe |
| Low back pain | More | Less |
| Sensory symptoms and signs | Numbness tends to be more localized to perianal area; symmetrical and bilateral; sensory dissociation occurs | Numbness tends to be more localized to saddle area; asymmetrical, may be unilateral; no sensory dissociation; loss of sensation in specific dermatomes in lower extremities with numbness and paresthesia; possible numbness in pubic area, including glans penis or clitoris |
| Motor strength | Typically symmetric, hyperreflexic distal paresis of lower limbs that is less marked; fasciculations may be | Asymmetric areflexic paraplegia that is more marked; fasciculations rare; atrophy more common |

| | | |
|-----------------------|--|---|
| | present | |
| Impotence | Frequent | Less frequent; erectile dysfunction that includes inability to have erection, inability to maintain erection, lack of sensation in pubic area (including glans penis or clitoris), and inability to ejaculate |
| Sphincter dysfunction | Urinary retention and atonic anal sphincter cause overflow urinary incontinence and fecal incontinence; tend to present early in course of disease | Urinary retention; tends to present late in course of disease |

Physical

The symptoms described in History are associated with corresponding signs pointing to an LMN or UMN lesion. Refer to [images 1-2](#) for assistance in examining the patient and documenting examination findings. In addition to the signs listed below, signs of other possible causes should be sought (eg, examination of the peripheral pulses to rule out possible vascular cause or ischemia of the conus medullaris).

- Signs of cauda equina syndrome include the following:
 - Muscle strength in the lower extremities is diminished. This may be specific to the involved nerve roots as listed below, with the lower lumbar and sacral roots more affected, leading to diminished strength in the glutei muscles, hamstring muscles (ie, semimembranosus, semitendinosus, biceps femoris), and the gastrocnemius and soleus muscles.
 - Sensation is decreased to pinprick and light touch in a dermatomal pattern corresponding to the affected nerve roots. This includes saddle anesthesia (sometimes including the glans penis or clitoris) and decreased sensation in the lower extremities in the distribution of lumbar and sacral nerves. Vibration sense may also be affected. Sensation of the glans penis or clitoris should be examined.
 - Muscle stretch reflexes may be absent or diminished in the corresponding nerve roots. Babinski reflex is diminished or absent.
 - Bulbocavernosus reflexes may be absent or diminished. This should always be tested.
 - Anal sphincter tone is patulous and should always be tested since it can define the completeness of the injury (with bulbocavernosus reflex); it is also useful in monitoring recovery from the injury.
 - Urinary incontinence could also occur secondary to loss of urinary sphincter tone; this may also present initially as urinary retention secondary to a flaccid bladder.
 - Muscle tone in the lower extremities is decreased, which is consistent with an LMN lesion.
- Signs of conus medullaris syndrome include the following:
 - Patients may exhibit hypertonicity, especially if the lesion is isolated and primarily UMN.
 - Signs are almost identical to those of the cauda equina syndrome, except that in conus medullaris syndrome signs are more likely to be bilateral; sacral segments occasionally show preserved bulbocavernosus reflexes and normal or increased anal sphincter tone; the muscle stretch reflex may be hyperreflexic, especially if the conus medullaris syndrome (ie, UMN lesion) is isolated; Babinski reflex may affect the extensors; and muscle tone might be increased (ie, spasticity).
 - Other signs include papilledema (rare, occurs in lower spinal cord tumors), cutaneous abnormalities (eg, cutaneous angioma, pilonidal sinus that may be present in dermoid or epidermoid tumors), distended bladder due to areflexia, and other spinal abnormalities (noted on lower back examination) predisposing the patient to the syndrome.
- Muscle strength of the following muscles should be tested to determine the level of lesion:

- L2 - Hip flexors (iliopsoas)
- L3 - Knee extensors (quadriceps)
- L4 - Ankle dorsiflexors (tibialis anterior)
- L5 - Big toe extensors (extensor hallucis longus)
- S1 - Ankle plantar flexors (gastrocnemius/soleus)
- In defining impairments associated with a spinal cord lesion, the American Spinal Cord Injury Association (ASIA) impairment scale is used in determining the level and extent of injury.
 - This scale should also be used in defining the extent of conus medullaris syndrome/cauda equina syndrome; the scale is as follows:
 - A - Complete; no sensory or motor function preserved in sacral segments S4-S5
 - B - Incomplete; sensory, but not motor, function preserved below the neurologic level and extends through sacral segments S4-S5
 - C - Incomplete; motor function preserved below the neurologic level, and the majority of key muscles below the neurologic level have a muscle grade less than 3
 - D - Incomplete; motor function preserved below the neurologic level, and the majority of key muscles below the neurologic level have a muscle grade greater than or equal to 3
 - E - Normal; sensory and motor function normal
 - The injury should be described using this scale, for example, ASIA class A. Most patients with cauda equina/conus medullaris syndrome are in ASIA class A or B initially and gradually improve to class C, D, or E.

Table 2. Root and Peripheral Nerve Innervation of the Lumbosacral Plexus

| Muscle | Nerve | Root |
|---------------------------|----------------------|-----------|
| Iliopsoas | Femoral | L2, 3, 4 |
| Adductor longus | Obturator | L2, 3, 4 |
| Gracilis | Obturator | L2, 3, 4 |
| Quadriceps femoris | Femoral | L2, 3, 4 |
| Anterior tibial | Deep peroneal | L4, 5 |
| Extensor hallucis longus | Deep peroneal | L4, 5 |
| Extensor digitorum longus | Deep peroneal | L4,5 |
| Extensor digitorum brevis | Deep peroneal | L4, 5, S1 |
| Peroneus longus | Superficial peroneal | L5, S1 |
| Internal hamstrings | Sciatic | L4, 5, |

| Internal hamstrings | Sciatic | S1 |
|---------------------------------|-----------------------------|--------------|
| External hamstrings | Sciatic | L5, S1 |
| Gluteus medius | Superior gluteal | L4, 5, S1 |
| Gluteus maximus | Inferior gluteal | L5, S1, 2 |
| Posterior tibial | Tibial | L5, S1 |
| Flexor digitorum longus | Tibial | L5, S1 |
| Abductor hallucis brevis | Tibial (medial plantar) | L5, S1, 2 |
| Abductor digiti quinti pedis | Tibial (lateral plantar) | S1, 2 |
| Gastrocnemius lateral | Tibial | L5, S1, 2 |
| Gastrocnemius medial | Tibial | S1, 2 |
| Soleus | Tibial | S1, 2 |

Causes

The most common causes of cauda equina and conus medullaris syndromes are the following:

- Lumbar stenosis (multilevel)
- Spinal trauma including fractures
- Herniated nucleus pulposus (cause of 2-6% of cases of cauda equina syndrome)
- Neoplasm, including metastases, astrocytoma, neurofibroma, and meningioma: Twenty percent of all spinal tumors affect this area.
- Spinal infection/abscess, such as tuberculosis, herpes simplex virus, meningitis, meningovascular syphilis, cytomegalovirus, or schistosomiasis
- Idiopathic, eg, spinal anesthesia: These syndromes may occur as complications of the procedure or of the anesthetic agent (eg, hyperbaric lidocaine, tetracaine).
- Spina bifida and tethered cord syndrome
- Other, rare causes
 - Spinal hemorrhage, especially subdural and epidural hemorrhage causing compression within the spinal canal
 - Intravascular lymphomatosis
 - Congenital anomalies of the spine/filum terminale including tethered cord syndrome

- Conus medullaris lipomas
- Multiple sclerosis
- Spinal arteriovenous malformations
- Late-stage ankylosing spondylitis
- Neurosarcoidosis
- Deep venous thrombosis of the spinal veins (propagated)

DIFFERENTIALS

Section 4 of 11 [\[Back Top Next\]](#)

[Authors and Editors](#) [Introduction](#) [Clinical](#) [Differentials](#) [Workup](#) [Treatment](#) [Medication](#)
[Follow-up](#) [Miscellaneous](#) [Multimedia](#) [References](#)

[Acute Inflammatory Demyelinating Polyradiculoneuropathy](#)
[Alcohol \(Ethanol\) Related Neuropathy](#)
[Amyotrophic Lateral Sclerosis](#)
[Chronic Inflammatory Demyelinating Polyradiculoneuropathy](#)
[Dermatomyositis/Polymyositis](#)
[Diabetic Neuropathy](#)
[Femoral Mononeuropathy](#)
[HIV-1 Associated Distal Painful Sensorimotor Polyneuropathy](#)
[HIV-1 Associated Multiple Mononeuropathies](#)
[HIV-1 Associated Myopathies](#)
[HIV-1 Associated Neuromuscular Complications \(Overview\)](#)
[Multiple Sclerosis](#)
[Neurosarcoidosis](#)
[Pathophysiology of Chronic Back Pain](#)
[Spinal Cord Hemorrhage](#)
[Spinal Cord Infarction](#)
[Spinal Cord Trauma and Related Diseases](#)
[Spinal Epidural Abscess](#)
[Syringomyelia](#)
[Traumatic Peripheral Nerve Lesions](#)
[Tropical Myeloneuropathies](#)

Other Problems to be Considered

Abdominal aortic aneurysm
 Amyloidosis with deposits in the spinal cord
 Ankylosing spondylitis and other spondyloarthropathy
 Charcot-Marie-Tooth disease (types 1 and 3)
 Guillain-Barré syndrome
 Herniated lumbar or sacral disk
 Intravascular lymphomatosis
 Lipomas within the spine
 Lumbar stenosis (multilevel)
 Neoplasm in the spine
 Paget disease of the spine
 Peripheral neuropathy and its various causes
 Retroperitoneal mass, including neoplasm and hematoma
 Sacral plexus injury (eg, after surgery, such as abdominal-perineal resection, sacral excision, or radical hysterectomy)
 Spinal infection/abscess and meningitis
 Spina bifida/congenital anomalies of the spine/filum terminale
 Spinal degenerative diseases

Spinal hemorrhage
Spondylolisthesis
Tethered cord syndrome/short filum terminale
Vascular intermittent claudication
Back pain

WORKUP

Section 5 of 11 [\[Back Top Next\]](#)

[Authors and Editors](#) [Introduction](#) [Clinical](#) [Differentials](#) [Workup](#) [Treatment](#) [Medication](#)
[Follow-up](#) [Miscellaneous](#) [Multimedia](#) [References](#)

Lab Studies

- These studies may help to define possible causes and any associated pathology, especially other causes of lesions in the lower spinal cord or cauda equina.
 - CBC count, blood glucose, electrolytes, blood urea nitrogen (BUN), and creatinine - As part of the workup to rule out associated anemia, infection, and renal dysfunction, especially in associated retroperitoneal mass
 - Elevated erythrocyte sedimentation rate (ESR) - May point to an inflammatory pathology
 - Syphilitic serology to rule out meningovascular syphilis

Imaging Studies

- MRI with contrast of the lumbosacral spine is the diagnostic test of choice and provides a more complete radiographic assessment of the spine than other tests. Gadolinium contrast MRI is currently the most sensitive imaging for detecting intradural neoplasms. It also may be able to rule out abdominal aneurysm, which could be the source of emboli causing conus medullaris infarction. See [Images 3-5](#) for representative MR images.
- CT scan myelogram may reveal an intradural or extradural mass or lesions affecting the conus medullaris.
- Plain radiographs of the lumbosacral spine are still useful and may depict early changes in vertebral erosions secondary to tumors and spina bifida. Chest radiography is indicated to rule out a pulmonary source of pathology that could affect the lumbosacral spine (eg, malignant tumor, tuberculosis). Follow-up chest CT may be required.
- Bone scan may detect malignant tumor or metastases and inflammatory conditions affecting the vertebrae.

Other Tests

- Needle electromyography (EMG) may show evidence of acute denervation, especially in cauda equina lesions and multilevel lumbar spinal stenosis. EMG studies also could help in predicting prognosis and monitoring recovery. Performing needle EMG of the bilateral external anal sphincter muscles is recommended.
- Nerve conduction studies, especially of the pudendal nerve, may rule out more distal peripheral nerve lesions.
- Somatosensory evoked potentials (SSEPs) could be done as part of the workup to rule out multiple sclerosis, which could present initially as a lower spinal cord syndrome.
- Duplex ultrasound of peripheral vessels may rule out compromised vasculature as a possible cause of associated claudication.

Procedures

- Lumbar puncture - Examination of the CSF to rule out inflammatory disease of the meninges or spinal cord

| |
|--|
| <p>TREATMENT</p> <p>Section 6 of 11 Back Top Next</p> <p>Authors and Editors Introduction Clinical Differentials Workup Treatment Medication Follow-up Miscellaneous Multimedia References</p> |
|--|

Medical Care

Specific treatment is directed at the primary cause; these are discussed in other articles. As discussed below, the general treatment goals are to minimize the extent of injury and to treat ensuing general complications.

- Acute care: In an acute setting, treatment options entail minimizing possible inflammation and preventing further trauma that might cause worsening of the injury. This is of even greater importance if the cause is trauma.
 - Maintenance of adequate airway, cardiopulmonary resuscitation, fluid management, and initial immobilization (using a molded thoracolumbosacral orthosis) are necessary to limit further damage.
 - Methylprednisolone should be administered as indicated in [Medication](#). This treatment must be started within 8 hours of injury. No evidence exists of any benefit if it is started more than 8 hours after injury; on the contrary, late treatment may have detrimental effects.
 - Administration of GM1 ganglioside sodium salt beginning within 72 hours of injury may be beneficial; the dose is 100 mg IV qd for 18-32 days.
 - Tirilazad mesylate (a nonglucocorticoid 21-aminosteroid) has been proven to be of benefit in animals and is currently under investigation. It inhibits lipid peroxidation and hydrolysis in the same manner as glucocorticoids.
- Any specific causal factor should be treated as soon as it has been identified.
- Treatment/prevention of possible complications should begin immediately, including the following:
 - Deep venous thrombosis/pulmonary embolism: Patients should use antiembolic compression stockings and subcutaneous heparin for 3 months as prophylaxis. Low-molecular-weight heparin also has been approved for prophylaxis. Ultrasound of the lower extremities may need to be done as an initial screening test with follow-up later.
 - Neurogenic bladder: Patients may require bladder catheterization.
 - Pressure ulcers: These may be prevented by eliminating pressure, optimizing wound-healing environment, and debriding if necessary.
 - Impotence: Use of sildenafil (Viagra) is becoming popular. Other drugs include yohimbine, papaverine, and alprostadil. Methods to promote coitus and/or ejaculation could also be used; these include implantable penile prostheses or vibrator stimulation.
 - Fecal incontinence: Patients may require use of stool softener or manual evacuation.
 - Heterotopic ossification: Heterotopic ossification (HO) can be confirmed by a triple-bone scan with associated elevated alkaline phosphatase and phosphate, especially in the early stage. Treatment includes stretching exercises, disodium etidronate (20 mg/kg qd x 2 wk, then 10 mg/kg for as long as 12 wk), radiation, and surgical excision. Surgery is done only when the HO has matured or stabilized, which is

evident by stable plain x-ray, normal alkaline phosphatase level, and decline in triple-phase bone scan activity.

- Pain: Pain should be treated appropriately based on its origin; treatment may include narcotics in the acute setting and tricyclic antidepressants later. Patient education, biofeedback, and relaxation techniques may also be used.
- Spasticity: Use of orthoses is advised to prevent contractures. Use of antispasticity medications also is encouraged. Other medications include dantrolene, diazepam, clonidine, and tizanidine. Nerve blocks also could be done to relieve spasticity; appropriate agents include phenol, botulinum toxin, or local anesthetics.

Surgical Care

In acute compression of the conus medullaris or cauda equina, surgical decompression as soon as possible (preferably within 6 h of injury) becomes mandatory. In a more chronic presentation with less severe symptoms, decompression could be performed when medically feasible and should be delayed to optimize the patient's medical condition; with this precaution, decompression is less likely to lead to irreversible neurological damage.

- Surgical treatment may be necessary for decompression or tumor removal, especially if the patient presents with acute onset of symptoms. Surgical treatment may include any of the following:
 - Laminectomy and instrumentation/fusion for stabilization
 - Discectomy
- Other surgical care may entail wound care, eg, debridement, skin graft, and skin flap/myocutaneous flap.

Consultations

Consultations to different specialties are needed for acute care and follow-up care.

- Urgent consults for follow-up and advice of the following specialists may be required:
 - Neurosurgery/spinal orthopedics - To assess the need for urgent surgical spinal decompression
 - Plastic surgery - May be needed if severe skin breakdowns occur
 - Rehabilitation - For initial consultation to prevent possible complications, including contractures and advising on bladder/bowel management, wound management, and prescribing the required physical therapy/occupational therapy and assistive devices; this would include follow-up, involvement of social workers, and vocational rehabilitation experts for home adaptation (needed on discharge).
 - Dietitian - To advise on optimizing the diet to ensure adequate calorie and protein intake. Patients with these syndromes often have an increase in metabolism associated with the healing process.

Diet

See [Consultations](#).

Activity

The rehabilitation team, especially the spinal cord injury rehabilitation physician and occupational and physical therapists, should be involved as soon as possible.

- This entails setting goals in the rehabilitation unit toward maintaining and improving endurance, with the ability to be independent in activities of daily living on discharge from the hospital or long-term care facility.

- The rehabilitation goals are to maximize the medical, physical, psychological, educational, vocational, and social function of the patient. This involves the following rehabilitation modalities:
 - Medical - Ensure adequate prevention and treatment of possible medical complications already discussed, especially deep venous thrombosis, bladder and bowel problems, and decubitus ulcers
 - Physical therapy - Range of motion and strengthening exercises, sitting balance, transfer training, and tilt table as tolerated (because of tendency to orthostatic hypotension). Tilt table should start at 15 degrees, progressing by 10 degrees every 15 minutes up to about 80 degrees with the necessary precautions. Other activities include wheelchair propulsion training, standing table exercises, functional electrical stimulation for increased muscle tone, use of lower extremity orthoses to aid balance and walking, along with ambulation exercises, family training and community skills, and a home exercise program.
 - Occupational therapy - Wheelchair training, especially for advanced wheelchair activities; transfer training; activities of daily living program with assistive devices for dressing, feeding, grooming, bathing, and toileting; motor coordination skills training; shower program; upper extremities training to increase strength for the increased demands of wheelchair propulsion and walking with assistive devices; home evaluation; family training; and a home exercise program.
 - Orthotic/assistive devices - May be needed for functional household ambulation and, if possible, community ambulation.
 - This entails prescribing and training in proper use of knee-ankle-foot orthoses (KAFO) with forearm crutches for support; for lower lesions, KAFOs or AFOs with canes or crutches may be needed.
 - In addition to the above, bathtub bench, transfer boards, pressure-relieving seats, and wheelchairs are devices that may be needed. The patient should be assessed for these needs prior to discharge from the acute rehabilitation setting.

Management of Acquired Hemophilia in the Emergency Department

eMedicine invites you to participate in a series of **free, interactive, case-based** activities on the treatment of acquired hemophilia

A 54-Year-Old Woman with Rheumatoid Arthritis, Bruising, Swelling, and Pain

Barbara M—, a 54-year-old white woman, presents to the emergency department with complaints of fatigue, bruising, and increasing pain and swelling in her left posterior thigh, hip, and buttock. (This activity is approved for *AMA PRA Category 1 Credit™*.)



[Take this course now](#)

MEDICATION

Section 7 of 11 [Back](#) [Top](#) [Next](#)

[Authors and Editors](#) [Introduction](#) [Clinical](#) [Differentials](#) [Workup](#) [Treatment](#) [Medication](#)
[Follow-up](#) [Miscellaneous](#) [Multimedia](#) [References](#)

The rationale for the medications listed in this section was outlined in [Medical Care](#).

Drug Category: *Corticosteroids*

These agents have anti-inflammatory properties and cause profound and varied metabolic effects. Corticosteroids modify the body's immune response to diverse stimuli.

| | |
|--------------------------|--|
| Drug Name | Methylprednisolone sodium succinate (Adlone, Medrol, Solu-Medrol) |
| Description | Decreases inflammation by suppressing migration of polymorphonuclear leukocytes and reversing increased capillary permeability. This prevents further worsening of injury. Treatment must be started within 8 h of injury; apparently has no benefit if started > 8 h after injury. Late treatment may have detrimental effects. |
| Adult Dose | 30 mg/kg IV over 15 min followed by a 45-min break, then restart IV infusion at 5.4 mg/kg/h for 23 h; medication must be started within 8 h after injury; starting after 8 h may have detrimental effect |
| Pediatric Dose | 0.5-1.7 mg/kg/d or 5-25 mg/m ² /d PO/IV/IM divided q6-12h |
| Contraindications | Documented hypersensitivity; viral, fungal or tubercular skin infections |
| Interactions | Digoxin may increase digitalis toxicity secondary to hypokalemia; estrogens may increase levels; phenobarbital, phenytoin and rifampin may decrease levels (adjust dose); monitor patients for hypokalemia when taking concurrent diuretics |
| Pregnancy | C - Safety for use during pregnancy has not been established. |
| Precautions | Hyperglycemia, edema, osteonecrosis, peptic ulcer disease, hypokalemia, osteoporosis, euphoria, psychosis, growth suppression, myopathy, and infections are possible complications of glucocorticoid use |

Drug Category: *Anticoagulants*

These agents are taken as prophylaxis for deep venous thrombosis and/or pulmonary embolism.

| | |
|--------------------------|--|
| Drug Name | Heparin |
| Description | Augments activity of antithrombin III and prevents conversion of fibrinogen to fibrin. Does not actively lyse but is able to inhibit further thrombogenesis. Prevents re-accumulation of clot after spontaneous fibrinolysis. Administer low dose. |
| Adult Dose | 5000 U SC q8-12h |
| Pediatric Dose | Not established |
| Contraindications | Documented hypersensitivity; subacute bacterial endocarditis; active bleeding; history of heparin-induced thrombocytopenia |
| Interactions | Digoxin, nicotine, tetracycline, and antihistamines may decrease effects; NSAIDs, aspirin, dextran, dipyridamole, and hydroxychloroquine may increase toxicity |
| Pregnancy | C - Safety for use during pregnancy has not been established. |
| Precautions | In neonates, preservative-free heparin recommended to avoid possible toxicity (gaspig syndrome) by benzyl alcohol, which is used as preservative; caution in severe hypotension and shock |

Drug Category: *Skeletal muscle relaxants*

These agents are thought to work centrally by suppressing conduction at the spinal level.

| | |
|------------------|---------------------|
| Drug Name | Baclofen (Lioresal) |
|------------------|---------------------|

| | |
|--------------------------|--|
| Description | May induce hyperpolarization of afferent terminals and inhibit both monosynaptic and polysynaptic reflexes at spinal level. |
| Adult Dose | 5 mg PO bid, with gradual increase q3d as tolerated to 30-80 mg qd in divided doses (tid/qid) Intrathecal: Test dose 50-100 mcg, doses >50 mcg should be given in 25-mcg increments separated by 24h; maintenance: after positive response to test dose, initial dose (via intrathecal pump) is twice test dose, given over 24-h period |
| Pediatric Dose | Generally not recommended for children <12 y for safety reasons <12 years: 2.5 to 5 mg PO bid with gradual increase q3d as tolerated <8 years: Not to exceed 30 mg/d 8-12 years: Not to exceed 60 mg/d >12 years: Administer as in adults |
| Contraindications | Documented hypersensitivity |
| Interactions | Opiate analgesics, benzodiazepines, alcohol, TCAs, guanabenz, MAOIs, clindamycin, and hypertensive agents may increase effects |
| Pregnancy | C - Safety for use during pregnancy has not been established. |
| Precautions | Caution in patients with history of autonomic dysreflexia and when spasticity is utilized to obtain increased function; autonomic dysreflexia can result from withdrawal of this medication |

| | |
|--------------------------|---|
| Drug Name | Dantrolene (Dantrium) |
| Description | Stimulates muscle relaxation by modulating skeletal muscle contractions at site beyond myoneural junction and acting directly on muscle itself. Prevents calcium release from sarcoplasmic reticulum. |
| Adult Dose | Begin with 25 mg PO qd; increase to 25 mg bid/qid, then by 25-mg increments to as high as 100 mg, bid/qid prn |
| Pediatric Dose | Start with 0.5 mg/kg PO bid, increase to 0.5 mg/kg bid/qid, then by increments of 0.5 mg/kg to 3 mg/kg bid/qid prn; not to exceed 100 mg qid |
| Contraindications | Documented hypersensitivity; active hepatic disease (hepatitis and cirrhosis) |
| Interactions | Toxicity may increase with coadministration of clofibrate and warfarin; coadministration with estrogen may increase hepatotoxicity in women older than 35 y |
| Pregnancy | C - Safety for use during pregnancy has not been established. |
| Precautions | May cause hepatotoxicity (use only for recommended indications); caution in impaired pulmonary function and severe cardiac insufficiency; may cause photosensitivity with exposure to sunlight |

Drug Category: *Benzodiazepines*

These agents may act in the spinal cord to induce muscle relaxation.

| | |
|--------------------|---|
| Drug Name | Diazepam (Diastat, Diazemuls, Valium) |
| Description | Depresses all levels of CNS (eg, limbic and reticular formation), possibly by increasing activity of GABA. Individualize dosage and increase cautiously to avoid adverse effects. |
| | Mild spasms: 5-10 mg PO q4-6h prn |

| | |
|--------------------------|--|
| Adult Dose | Moderate spasms: 5-10 mg IV prn Severe spasms: Mix 50-100 mg in 500 mL D5W and infuse at 40 mL/h |
| Pediatric Dose | Mild spasms: 0.1-0.8 mg/kg/d PO divided tid/qid Moderate or severe spasms: 0.1-0.3 mg/kg IV q4-8h |
| Contraindications | Documented hypersensitivity; narrow-angle glaucoma |
| Interactions | Phenothiazines, barbiturates, alcohols, and MAOIs increase CNS toxicity when administered concurrently |
| Pregnancy | D - Unsafe in pregnancy |
| Precautions | Caution with other CNS depressants, low albumin levels, or hepatic disease (may increase toxicity) |

Drug Category: Alpha 2-adrenergic agonist agents

May reduce sympathetic outflow, which may produce a reduction in muscle tone.

| | |
|--------------------------|--|
| Drug Name | Clonidine (Catapres) |
| Description | Stimulates alpha2-adrenoreceptors in brain stem, activating an inhibitory neuron, which in turn results in reduced sympathetic outflow. |
| Adult Dose | 1 mg PO bid; titrate to effect; not to exceed 2.4 mg/d |
| Pediatric Dose | 5-30 mcg/kg/d PO |
| Contraindications | Documented hypersensitivity |
| Interactions | Tricyclic antidepressants inhibit hypotensive effects of clonidine; coadministration of clonidine with beta-blockers may potentiate bradycardia; tricyclic antidepressants may enhance hypertensive response associated with abrupt clonidine withdrawal; hypotensive effects of clonidine are enhanced by narcotic analgesics |
| Pregnancy | C - Safety for use during pregnancy has not been established. |
| Precautions | Caution in cerebrovascular disease, coronary insufficiency, sinus node dysfunction, and renal impairment |

| | |
|--------------------------|---|
| Drug Name | Tizanidine (Zanaflex) |
| Description | Centrally acting muscle relaxant metabolized in the liver and excreted in urine and feces. |
| Adult Dose | 4-8 mg PO q8h prn; not to exceed 36 mg/d |
| Pediatric Dose | Not established |
| Contraindications | Documented hypersensitivity |
| Interactions | May interact with alcohol (increase somnolence, stupor) and oral contraceptives (which decrease its clearance), and can cause increased hypotensive effects when administered concurrently with diuretics |
| Pregnancy | C - Safety for use during pregnancy has not been established. |
| Precautions | Caution in renal impairment |

Drug Category: Neuromuscular Blocker Agent, Toxin

These agents inhibit transmission of impulses in neuromuscular tissue.

| | |
|------------------|--|
| Drug Name | Botulinum Toxin Type A (BOTOX®) |
| | Binds to receptor sites on motor nerve terminals and inhibits release of acetylcholine, which in turn inhibits transmission of impulses in neuromuscular tissue. |

| | |
|--------------------------|--|
| Description | Most useful for treating spasticity in the gastrocnemius and soleus muscles; less effective in larger muscles such as quadriceps. Re-examine patients 7-14 d after initial dose, to assess for response. May be repeated q3-4mo. |
| Adult Dose | 1.25-2.5 U (0.05-0.1 mL) IM injection into most active muscles; give q3-4mo |
| Pediatric Dose | <12 years: Not established >12 years: Administer as in adults |
| Contraindications | Documented hypersensitivity |
| Interactions | Aminoglycosides or drugs that interfere with neuromuscular transmission may potentiate effects of botulinum toxin |
| Pregnancy | C - Safety for use during pregnancy has not been established. |
| Precautions | Do not exceed recommended dosages and frequencies of administration; presence of antibodies to botulinum toxin type A may reduce effects of therapy; when used for cervical dystonia it may cause dysphagia, upper respiratory infection, neck pain, or headache; ptosis may occur when used for blepharism or strabismus When used cosmetically for glabellar lines may cause headache, respiratory infection, flu syndrome, blepharoptosis, or nausea |

Drug Category: *Bisphosphonate derivatives*

Analogs of pyrophosphate and act by binding to hydroxyapatite in bone-matrix, thereby inhibiting the dissolution of crystals. Prevent osteoclast attachment to the bone matrix and osteoclast recruitment and viability.

| | |
|--------------------------|--|
| Drug Name | Etidronate disodium (Didronel) |
| Description | Inhibits normal and abnormal bone resorption. Appears to inhibit bone resorption without inhibiting bone formation and mineralization. |
| Adult Dose | 20 mg/kg PO qd for 2 wk, then 10 mg/kg for as long as 12 wk |
| Pediatric Dose | Not established |
| Contraindications | Documented hypersensitivity; hypocalcemia, renal impairment |
| Interactions | Coadministration with calcium containing products and other multivalent cations decrease absorption |
| Pregnancy | B - Usually safe but benefits must outweigh the risks. |
| Precautions | Monitor hypercalcemia-related parameters (eg, serum levels of calcium, phosphate, magnesium and potassium); maintain adequate intake of calcium and vitamin D to prevent severe hypocalcemia; caution if active upper GI problems; do not administer with alendronate for osteoporosis in postmenopausal women |

Drug Category: *Phosphodiesterase (type 5) enzyme inhibitors*

These agents increase vasodilatory effects of nitric oxide by inhibiting the enzyme phosphodiesterase type 5, which in turn increases sensitivity for erections.

| | |
|--------------------|---|
| Drug Name | Sildenafil (Viagra) |
| Description | Phosphodiesterase type 5 (PDE5) selective inhibitor. Inhibition of PDE5 increases cGMP activity, which increases vasodilatory effects of nitric oxide. Effective in men with mild-to-moderate ED. Take on an empty stomach about 1 h before sexual activity. Sexual stimulation is necessary to activate response. The increased sensitivity for erections may last 24 h. Available |

| | |
|--------------------------|--|
| | as 25-, 50-, and 100-mg tabs. |
| Adult Dose | 25-100 mg PO 1 h before sexual activity |
| Pediatric Dose | Not established |
| Contraindications | Documented hypersensitivity; concurrent or intermittent using of organic nitrates in any form |
| Interactions | Potentiates vasodilatory effect of NO, resulting in potentially fatal drop in blood pressure; coadministration with ketoconazole, erythromycin, or cimetidine increases plasma sildenafil concentrations; coadministration with rifampin decreases plasma levels of sildenafil |
| Pregnancy | B - Usually safe but benefits must outweigh the risks. |
| Precautions | Adverse effects include headaches (16%), flushing (10%), upset stomach (7%), nasal congestion (4%), and a blue haze at the periphery of vision (3%); adverse effects occur more often in men taking the 100-mg dose; serious adverse effects occur in patients with severe heart disease and those who are taking nitrates; rates of MI were 1.7 and 1.4 per 100 man-years for sildenafil and placebo groups |

| | |
|--------------------------|---|
| Drug Name | Vardenafil (Levitra) |
| Description | Phosphodiesterase type 5 (PDE5) selective inhibitor. Inhibition of PDE5 increases cGMP activity, which increases vasodilatory effects of nitric oxide. Effective in men with mild-to-moderate ED. Take on empty stomach about 1 h before sexual activity. Sexual stimulation is necessary to activate response. Increased sensitivity for erections may last 24 h. Available as 2.5-mg, 5-mg, 10-mg, and 20-mg tabs. |
| Adult Dose | 10 mg PO 1 h before sexual activity; may increase to maximum recommended dose of 20 mg or decreased to 5 mg based on efficacy and side effects Concurrent administration with ritonavir: Not to exceed 2.5 mg PO q72h Concurrent administration with indinavir, ketoconazole (400 mg PO qd), or itraconazole (400 mg PO qd): Not to exceed 2.5 mg PO q24h Concurrent administration with ketoconazole (200 mg PO qd), itraconazole (200 mg PO qd), or erythromycin: Not to exceed 5 mg PO q24h |
| Pediatric Dose | Not established |
| Contraindications | Documented hypersensitivity; concurrent or intermittent use of alpha-blockers or organic nitrates in any form |
| Interactions | CYP3A4 inhibitors (eg, erythromycin, ketoconazole, itraconazole, indinavir, ritonavir) may significantly increase levels of vardenafil; vardenafil potentiates hypotensive effect of nitrates or alpha-blockers; avoid coadministration with other drugs that prolong QT interval (eg, quinidine, procainamide, amiodarone, sotalol) |
| Pregnancy | B - Usually safe but benefits must outweigh the risks. |
| Precautions | Common adverse effects include headache, flushing, rhinitis, dyspepsia, or indigestion; assess cardiovascular status before use; caution with left ventricular outflow obstruction or conditions aggravated by hypotension or prolonged QT interval; caution with hepatic impairment (decrease dose); may cause prolonged or painful erection (<2%) |

| | |
|------------------|---|
| Drug Name | Tadalafil (Cialis) |
| | Phosphodiesterase type 5 (PDE5) selective inhibitor. Inhibition |

| | |
|--------------------------|---|
| Description | of PDE5 increases cGMP activity, which increases vasodilatory effects of nitric oxide. Sexual stimulation is necessary to activate response. Increased sensitivity for erections may last 36 h. Available as 5-mg, 10-mg, and 20-mg tabs. |
| Adult Dose | 10 mg PO before sexual activity; may increase to maximum recommended dose of 20 mg or decreased to 5 mg based on efficacy and adverse effects; not to exceed 1 dose per day; may be taken without regard to food Concurrent administration with potent CYP3A4 inhibitors (eg, ketoconazole, ritonavir): Not to exceed 10 mg PO q72h prn Moderate renal impairment (CrCl 30-50 mL/min): 5 mg PO qd prn initially; may increase to 10 mg PO q48h prn Severe renal impairment (CrCl <30 mL/min): Do not exceed 5 mg PO qd prn Mild-to-moderate hepatic impairment: Do not exceed 10 mg PO qd prn |
| Pediatric Dose | <18 years: Not established |
| Contraindications | Documented hypersensitivity; concurrent or intermittent use of alpha-blockers (eg, doxazosin, terazosin, prazosin) or organic nitrates in any form |
| Interactions | CYP3A4 inhibitors (eg, erythromycin, ketoconazole, itraconazole, indinavir, ritonavir) may significantly increase levels of vardenafil; vardenafil potentiates hypotensive effect of nitrates or alpha-blockers; concurrent alcohol consumption may increase orthostatic hypotension risk |
| Pregnancy | B - Usually safe but benefits must outweigh the risks. |
| Precautions | Common adverse effects include headache, flushing, rhinitis, dyspepsia, or indigestion; assess cardiovascular status before use; caution with left ventricular outflow obstruction or conditions aggravated by hypotension; caution with hepatic or renal impairment (decrease dose); may cause prolonged or painful erection; may cause back pain or myalgias |

FOLLOW-UP

Section 8 of 11 [Back](#) [Top](#) [Next](#)

[Authors and Editors](#) [Introduction](#) [Clinical](#) [Differentials](#) [Workup](#) [Treatment](#) [Medication](#)
[Follow-up](#) [Miscellaneous](#) [Multimedia](#) [References](#)

Further Inpatient Care

- Rehabilitation - Physical therapy and occupational therapy for muscle strengthening, endurance, mobility, activities of daily living, gait/balance, use of assistive devices, and adaptation to home environment
- Surgical follow-up for postoperative spinal care, depending on the cause
- Urology - Cystometrography to define bladder pathology. Patients should undergo regular follow-up on discharge for any renal or bladder complications and impotence, because they have an increased tendency for recurrent urinary tract infection and calculi
- Dietitian

Further Outpatient Care

- Follow-up with consulting physicians within a week after discharge
- Follow-up with a primary care physician to monitor posthospital medications and other laboratory tests
- Yearly cystoscopy for patients with suprapubic catheters to help detect early bladder malignancies
- Regular follow-up urodynamic studies, renal ultrasound, and general cancer screening
- Follow-up with the rehabilitation team, including the spinal cord injury rehabilitation physician, physical therapist, and occupational therapist. These professionals are responsible for monitoring community and home integration and following improvements in the patient's strength, coordination, transfer, activities of daily living, and ambulation.

In/Out Patient Meds

- This includes continuation of anticoagulation medications (if necessary), antispasticity medications, and other medications being given to ameliorate possible complications, including bladder and bowel problems and heterotopic ossifications. If a patient is on warfarin, one of the team physicians looking after the patient must be designated to monitor the international normalized ratio (INR) at regular intervals.

Transfer

- On discharge from the surgical ward, patients often are transferred to an acute rehabilitation unit, from which they may be discharged, transferred to a subacute unit, or transferred to long-term care depending on the level of long-term disability.

Complications

- Thromboembolic phenomena
- Neurogenic bladder/bowel
- Erectile dysfunction
- Pressure ulcers
- Heterotopic ossification
- Osteoporosis
- Chronic neuropathic pain
- Spasticity/contractures
- Recurrent urinary tract infections
- Urethral stricture
- Bladder calculi
- Depression

Prognosis

- Prognosis can be predicted based on the ASIA impairment scale.
 - ASIA A: Ninety percent of patients remain neurologically complete and unable to have functional ambulation.
 - ASIA B: Seventy-two percent of patients are unable to attain functional ambulation.
 - ASIA C/D: Thirteen percent are unable to attain functional ambulation (reciprocal gait of 200 feet or more) 1 year after injury.
- Ambulatory motor index also is used to predict ambulatory capability, it is calculated using a 4-point scale (0=absent, 1=trace/poor, 2=fair, 3=good or normal) and then calculating hip flexion, hip abduction, hip extension, knee extension, and knee flexion on both sides; the score is expressed as a percentage of the maximum score of 30.
 - A score of 60% or more shows a good chance for community ambulation with no more than one knee-ankle-foot orthosis (KAFO).
 - A patient with a score of 79% or higher may not need an orthosis.
 - A patient with a score of 40% or less may require 2 KAFOs for community ambulation.

Patient Education

- Training in self-catheterization and finger fecal disimpaction, if required
- Use of measures to prevent pressure ulcers, such as skin inspection/care, positioning, turning and transferring tactics, use of skin protectors, or pressure-reducing support surfaces
- Maintenance of endurance and strength-training exercises
- Regular follow-up by the consulting teams who treated the patient in the hospital
- Instructions on how and when medications should be taken and when follow-up laboratory tests should be performed
- For excellent patient education resources, visit eMedicine's [Erectile Dysfunction Center](#) and [Brain and Nervous System Center](#). Also, see eMedicine's patient education articles [Impotence/Erectile Dysfunction](#), [Erectile Dysfunction FAQs](#), and [Cauda Equina Syndrome](#).

MISCELLANEOUS

Section 9 of 11 [Back](#) [Top](#) [Next](#)

[Authors and Editors](#) [Introduction](#) [Clinical](#) [Differentials](#) [Workup](#) [Treatment](#) [Medication](#)
[Follow-up](#) [Miscellaneous](#) [Multimedia](#) [References](#)

Medical/Legal Pitfalls

- Physical examination for cauda equina or conus medullaris syndromes would be incomplete without tests for sensation of the saddle and perineal areas, bulbocavernosus reflex, cremasteric reflex, and anal sphincter tone, findings for all of which are likely to be abnormal.
- MRI with gadolinium contrast of the lumbosacral area is the diagnostic test of choice to define pathology in the areas of the conus medullaris and cauda equina. Plain x-rays and CT scan may be normal.

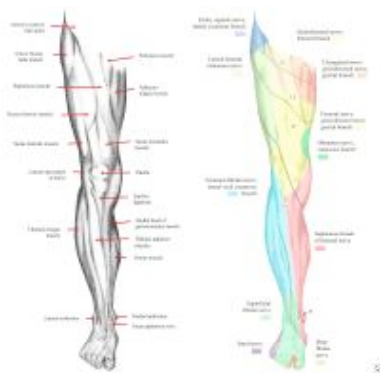- Conus medullaris infarction should be considered in the differential diagnosis, and a source of emboli should be sought by ultrasound to rule out an abdominal aortic aneurysm.
- HO should be ruled out by triple-bone scan in a patient with pain and swelling of the lower extremity in whom deep venous thrombosis (DVT) has been ruled out. In other words, HO should always be considered as a differential diagnosis of DVT in these patients.
- Spinal, metastatic malignant neoplasms should be ruled out and the primary source sought as part of the workup in any patient presenting with any of the symptoms listed in [Clinical](#).

MULTIMEDIA

Section 10 of 11 [Back](#) [Top](#) [Next](#)

[Authors and Editors](#) [Introduction](#) [Clinical](#) [Differentials](#) [Workup](#) [Treatment](#) [Medication](#)
[Follow-up](#) [Miscellaneous](#) [Multimedia](#) [References](#)

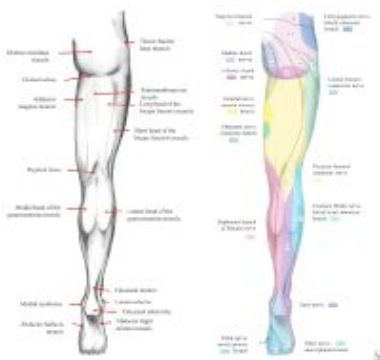Media file 1: [Muscle groups, surface anatomy, peripheral sensory innervation, and dermatomes of the anterior lower limb.](#) This image should be correlated with Tables 1 and 2 in the text. Image courtesy of Nicholas Y. Lorenzo, MD.



 [View Full Size Image](#)

Media type: Image

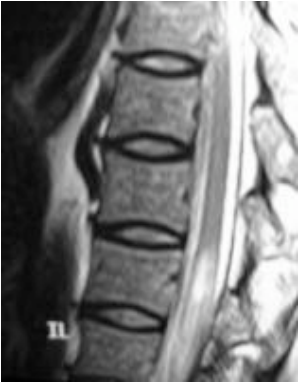Media file 2: [Muscle groups, surface anatomy, peripheral sensory innervation, and dermatomes of the posterior lower limb.](#) This image should be correlated with Tables 1 and 2 in the text. Image courtesy of Nicholas Y. Lorenzo, MD.



 [View Full Size Image](#)

Media type: Image

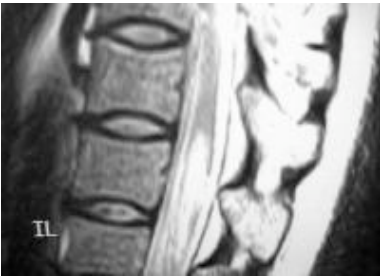Media file 3: [Conus/epiconus infarction in the setting of sickle cell crisis.](#) Image courtesy of Matthew J. Baker, MD.



[View Full Size Image](#)

Media type: MRI

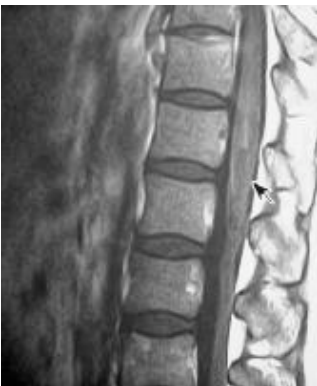Media file 4: [Conus/epiconus infarction in the setting of sickle cell crisis in the same patient shown in Image 3. Image courtesy of Matthew J. Baker, MD.](#)



[View Full Size Image](#)

Media type: MRI

Media file 5: [Conus/epiconus infarction in the setting of sickle cell crisis in the same patient shown in Images 3 and 4. Image courtesy of Matthew J. Baker, MD.](#)



[View Full Size Image](#)

Media type: MRI

REFERENCES

Section 11 of 11 [Back](#) [Top](#)

[Authors and Editors](#) [Introduction](#) [Clinical](#) [Differentials](#) [Workup](#) [Treatment](#) [Medication](#)
[Follow-up](#) [Miscellaneous](#) [Multimedia](#) [References](#)

- Biesek D, Ksiazkiewicz B, Wanat-Slupska E. [Conus medullaris and cauda equina infarct in the course of thrombosis of deep veins of lower extremities]. *Pol Merkur Lekarski*. Sep 2004;17(99):273-4. [\[Medline\]](#).
- Butefisch C, Gutmann L, Gutmann L. Compression of spinal cord and cauda equina in Charcot-Marie-Tooth disease type 1A. *Neurology*. Mar 10 1999;52(4):890-1. [\[Medline\]](#).
- Canale S. Circulation of spinal cord. In: *Campbell's Operative Orthopaedics. Vol 9. St. Louis, Mo: Mosby; 1998. 2683.*

- Coscia M, Leipzig T, Cooper D. Acute cauda equina syndrome. Diagnostic advantage of MRI. *Spine*. Feb 15 1994;19(4):475-8. [\[Medline\]](#).
- Delamarter RB, Sherman JE, Carr JB. 1991 Volvo Award in experimental studies. Cauda equina syndrome: neurologic recovery following immediate, early, or late decompression. *Spine*. Sep 1991;16(9):1022-9. [\[Medline\]](#).
- Fujisawa H, Igarashi S, Koyama T. Acute cauda equina syndrome secondary to lumbar disc herniation mimicking pure conus medullaris syndrome--case report. *Neurol Med Chir (Tokyo)*. Jul 1998;38(7):429-31. [\[Medline\]](#).
- Gellido CL, Onesti S, Llana J. Spinal schistosomiasis. *Neurology*. Jan 25 2000;54(2):527. [\[Medline\]](#).
- Gleave JR, MacFarlane R. Prognosis for recovery of bladder function following lumbar central disc prolapse. *Br J Neurosurg*. 1990;4(3):205-9. [\[Medline\]](#).
- Kaiboriboon K, Olsen TJ, Hayat GR. Cauda equina and conus medullaris syndrome in sarcoidosis. Case report and literature review. *Neurology*. 2005;11(3):179-183. [\[Medline\]](#).
- Kostuik JP, Harrington I, Alexander D, et al. Cauda equina syndrome and lumbar disc herniation. *J Bone Joint Surg Am*. Mar 1986;68(3):386-91. [\[Medline\]](#).
- Kothbauer K, Seiler RW. [Tethered spinal cord syndrome in adults]. *Nervenarzt*. Apr 1997;68(4):285-91. [\[Medline\]](#).
- Ku A, Lachmann E, Tunkel R. Neurosarcoidosis of the conus medullaris and cauda equina presenting as paraparesis: case report and literature review. *Paraplegia*. Feb 1996;34(2):116-20. [\[Medline\]](#).
- Mascalchi M, Salvi F, Pirini MG. Transthyretin amyloidosis and superficial siderosis of the CNS. *Neurology*. Oct 22 1999;53(7):1498-503. [\[Medline\]](#).
- Mathew P, Todd NV. Diagnosis of intradural conus and cauda equina tumours. *Br J Hosp Med*. Aug 18-31 1993;50(4):169-70, 172-4. [\[Medline\]](#).
- Michelson DJ, Ashwal S. Tethered cord syndrome in childhood: diagnostic features and relationship to congenital anomalies. *Neurol Res*. 2004;26(7):745-753. [\[Medline\]](#).
- Nascone JW, Lauerman WC, Wiesel SW. Cauda Equina Syndrome: Is it a surgical emergency?. *Univ Pennsylvania Orthoped J*. 1999;12:73-6.
- Podnar S. Electromyography of the anal sphincter: which muscle to examine?. *Muscle Nerve*. Sep 2003;28(3):377-9. [\[Medline\]](#).
- Podnar S. Bilateral vs. unilateral electromyographic examination of the external anal sphincter muscle. *Neurophysiol Clin*. Oct 2004;34(3-4):153-7. [\[Medline\]](#).
- Rydevik B. Neurophysiology of cauda equina compression. *Acta Orthop Scand Suppl*. 1993;251:52-5. [\[Medline\]](#).
- Schizas C, Ballesteros C, Roy P. Cauda equina compression after trauma: an unusual presentation of spinal epidural lipoma. *Spine*. Apr 15 2003;28(8):E148-51. [\[Medline\]](#).
- Spencer TS, Campellone JV, Maldonado I, et al. Clinical and magnetic resonance imaging manifestations of neurosarcoidosis. *Semin Arthritis Rheum*. 2005;34(4):649-661. [\[Medline\]](#).
- Waters JH, Watson TB, Ward MG. Conus medullaris injury following both tetracaine and lidocaine spinal anesthesia. *J Clin Anesth*. Dec 1996;8(8):656-8. [\[Medline\]](#).

[Cauda Equina and Conus Medullaris Syndromes excerpt](#)

Article Last Updated: Jan 17, 2007

[About Us](#) | [Privacy](#) | [Terms of Use](#) | [Contact Us](#) | [Advertising](#) | [Institutional Subscribers](#)



We subscribe to the
[HONcode principles](#) of the
[Health On the Net Foundation](#)



© 1996-2008 by WebMD.
[All Rights Reserved.](#)

Medicine is a constantly changing science and not all therapies are clearly established. New research changes drug and treatment therapies daily. The authors, editors, and publisher of this journal have used their best efforts to provide information that is up-to-date and accurate and is generally accepted within medical standards at the time of publication. However, as medical science is constantly changing and human error is always possible, the authors, editors, and publisher or any other party involved with the publication of this article do not warrant the information in this article is accurate or complete, nor are they responsible for omissions or errors in the article or for the results of using this information. The reader should confirm the information in this article from other sources prior to use. In particular, all drug doses, indications, and contraindications should be confirmed in the package insert. [FULL DISCLAIMER](#)