



## Electrodiagnostic approach to the patient with suspected motor neuron disease

David A. Chad, MD\*

*University of Massachusetts Medical School  
UMass Memorial Health Care*

*Department of Neurology, University of Massachusetts Medical Center,  
55 Lake Ave., North Worcester, MA 01605, USA*

Amyotrophic lateral sclerosis (ALS) is a relentlessly progressive, neurodegenerative disorder involving motor neurons in the cerebral cortex, brainstem, and spinal cord. Specifically targeted are the giant Betz cells of the motor cortex and the motor neurons of the brainstem and spinal cord with the exception of the oculomotor nuclei and the nucleus of the sacral spinal cord (nucleus of Onuf) that controls the external urethral and anal sphincters [1]. The clinical findings that develop over time comprise a combination of upper motor neuron (UMN) signs (loss of dexterity, spasticity, hyperreflexia, and pathological reflexes), and lower motor neuron (LMN) signs (muscle weakness, atrophy, and fasciculations) in a widespread distribution. The annual incidence is 1 to 2 per 100,000 population and the prevalence is about 6 per 100,000 [2,3]. There is a slight male predominance of approximately 1.5 men to 1 woman. The disease occurs throughout adult life with the peak occurring between 55 and 70 years of age. Age is the most significant risk factor for ALS. Most cases are sporadic but approximately 5% to 10% are familial and the majority is inherited in an autosomal dominant fashion. About 10% to 20% of these cases have been attributed to mutations in the gene coding for Cu/Zn-superoxide dismutase (SOD1). The average survival after onset of ALS symptoms is approximately 3 years but about 25% of patients survive (without intervention for respiratory support) for at least 5 years and more than 10% have a survival in excess of 10 years [2]. Patients with longer survival display a poorly understood “resistance” to ALS [4] and may have a more benign form of the disease.

The diagnosis of ALS per se may be challenging because there is no single diagnostic test for ALS (with the exception of finding a mutation in the

---

\* E-mail address: [chadd@ummhc.org](mailto:chadd@ummhc.org) (D.A. Chad).

SOD1 gene). Additionally, the disease may begin focally and resemble a variety of other neurologic disorders that share clinical features with ALS. This latter point emphasizes an important imperative for the clinician—the need to consider a broad range of peripheral and central nervous system disorders in the process of differential diagnosis of ALS, especially when the disease is in its early stages. We review the diagnostic criteria for ALS and discuss which features to consider in determining the degree of certainty or level of confidence in the diagnosis. We then enumerate the important differential diagnostic possibilities that emerge from a careful consideration of the clinical features and comment on neuroimaging studies and laboratory tests employed in the diagnostic process. Next, we turn our attention to the important role played by electrophysiologic studies in the diagnostic evaluation of the patient with suspected ALS. We then return to a focused consideration of selected disorders in the differential diagnosis of ALS, and conclude with a summary of our diagnostic approach for this disease.

## Diagnosis of ALS

ALS is almost always a pure motor disorder without clinically significant sensory impairment, ocular palsy, or bladder and bowel dysfunction [5]. In fact, the presence of these latter features would argue against the diagnosis of ALS. Dementia occurs rarely, in about 1% to 2% of cases.

To make the diagnosis of ALS, a combination of upper and lower motor neuron signs with evidence of spread within a region or to other CNS regions is required (Table 1) [6]. Additionally, there must be no electrophysiologic, or neuropathologic evidence of other disease processes that might explain the clinical signs of neuronal degeneration, and in turn, no neuroimaging evidence of other disease processes to explain the clinical or electro-

Table 1  
Revised World Federation of Neurology requirements for the diagnosis of ALS

Features present	Features absent
Evidence of lower motor neuron degeneration by clinical, electrophysiological or neuropathological examination	Electrophysiological or pathological evidence of other disease processes that might explain signs of lower motor neuron or upper motor degeneration or both
Evidence of upper motor neuron degeneration by clinical examination	Neuroimaging evidence of other disease processes that might explain the observed clinical and electrophysiological signs
Progressive spread of signs within a region, or to other regions as determined by history or examination	

*Data from Brooks BR, Miller RG, Swash M, et al. El Escorial revisited: revised criteria for the diagnosis of amyotrophic lateral sclerosis. Amyotroph Lateral Scler Other Motor Neuron Disord* 2000; 1:293–9.

physiologic signs. According to the revised El Escorial criteria the clinical diagnosis of ALS (without pathological confirmation) may be made with varying degrees or levels of certainty by clinical assessment alone. These levels of certainty (Table 2) are determined by the extent to which upper and lower motor neuron signs are distributed in four cardinal topographical anatomic regions of the central nervous system—the brainstem, and three spinal cord regions, cervical, thoracic, and lumbosacral.

Clinically definite ALS is defined on clinical evidence alone by the presence of UMN as well as LMN signs, in the bulbar region and at least two spinal regions, or the presence of UMN and LMN signs in three spinal regions. *Clinically probable ALS* is defined on clinical evidence alone by UMN and LMN signs in at least two regions with some UMN signs necessarily rostral to the LMN signs. *Clinically probable ALS—laboratory supported*, is defined when clinical signs of UMN and LMN dysfunction are in only one region, or when UMN signs alone are present in one region and LMN signs defined by electrophysiologic criteria are present in at least two regions. Additionally, there must be proper application of neuroimaging and clinical laboratory protocols to exclude other causes. The addition of the category, “clinically probable ALS—laboratory supported,” marks a key difference from the first set of El Escorial criteria [7] because the combination of EMG and clinical findings is used in the diagnostic assessment. The rationale for this criterion is discussed in detail later. Finally, *clinically possible ALS* is defined when clinical signs of UMN and LMN dysfunction are found together in only one region, or UMN signs are found in two or more regions, or LMN signs are found rostral to UMN signs. The diagnosis of clinically possible ALS

Table 2  
Levels of certainty in the clinical diagnosis of ALS

Level of certainty	Characteristic features
Definite ALS	UMN as well as LMN signs, in the bulbar region and at least two spinal regions; or,
Probable ALS	UMN and LMN signs in three spinal regions UMN and LMN signs in at least two regions with some UMN signs necessarily rostral to the LMN signs
Probable ALS—Laboratory Supported	Clinical signs of UMN and LMN dysfunction are in only one region; or, UMN signs alone are present in one region; and, LMN signs defined by electrophysiologic criteria are present in at least two regions
Possible ALS	Clinical signs of UMN and LMN dysfunction are found together in only one region; or, UMN signs are found in two or more regions; or, LMN signs are found rostral to UMN signs

*Data from Brooks BR, Miller RG, Swash M, et al. El Escorial revisited: revised criteria for the diagnosis of amyotrophic lateral sclerosis. Amyotroph Lateral Scler Other Motor Neuron Disord* 2000; 1:293–9.

infers that EMG criteria for LMN involvement as established for clinically probable ALS–laboratory supported have not yet been met, but that other conditions that could mimic ALS have been excluded.

### **Differential diagnosis**

A variety of neurological disorders may mimic some aspect of ALS and a major goal of the diagnostic process is to exclude them systematically. Stated another way, the clinician's responsibility is to entertain the diagnosis of any possible ALS "look alike," however superficial the resemblance may be, so as not to overlook a potentially treatable disorder, or at least one more manageable than ALS. For example, ALS may present with differing patterns of weakness: a focal onset (restricted to bulbar muscles or to a single limb), a bibrachial paresis, hemiparesis, or paraparesis. Moreover, the weakness seen in ALS may be exclusively LMN in type at the outset. In this instance the disease might simulate a disorder of anterior horn cells other than ALS, or an abnormality of nerve roots, plexuses or multiple peripheral nerves, even neuromuscular junction and muscle [8]. Alternatively, the initial presentation of ALS might be predominantly upper motor neuron in type, suggesting a lesion in the cerebrum, brainstem, or spinal cord. Accordingly, the differential diagnosis by anatomic site is presented in Table 3; further comment is presented later in this article.

### **Diagnostic testing**

The four components of diagnostic testing are clinical laboratory studies, neuroimaging, neuropathology, and electrophysiology [6]. Except for an elevated CK of mild-to-moderate degree found in many ALS patients, clinical laboratory testing is expected to be normal. In general, in the context of suspected ALS, we look for evidence of treatable or reversible metabolic, autoimmune, neoplastic, infectious, or vasculitic disorders [9]. For example, a multiple motor mononeuropathic presentation would prompt us to look for anti-ganglioside (GM1) autoantibodies seeking supporting evidence of multifocal motor neuropathy. A bulbar-onset presentation might lead us to test for the acetylcholine receptor antibody for evidence of myasthenia gravis, or to a search for the DNA abnormality of Kennedy's syndrome (see later discussion)

Neuroimaging of the brain and spinal cord are critically important to exclude structural pathology of the brain, brainstem, cervicomedullary junction, spinal cord, and nerve roots that might explain UMN findings or LMN findings or both. For example, before the diagnosis of ALS is accepted in instances of LMN findings in the arms and UMN in the legs, cervical spondylotic myelopathy must be excluded.

Table 3  
The differential diagnosis of ALS classified anatomically

Anatomic site	Possible disorder
Muscle	Inclusion body myositis, distal myopathy, adult nemaline myopathy, neck extensor myopathy, oculopharyngeal dystrophy
Neuromuscular junction	Myasthenia gravis, Lambert-Eaton myasthenic syndrome
Roots, plexus, nerve	Spondylotic polyradiculopathy, diabetic polyradiculopathy, infectious polyradiculopathy, plexopathies, mononeuropathies, multifocal motor neuropathy
Anterior horn cells	Spinal muscular atrophy, bulbosplinal neuronopathy, monomelic amyotrophy, paraneoplastic motor neuronopathy, post-polio muscular atrophy, hexosaminidase deficiency
Spinal cord	Spondylotic radiculomyelopathy, syringomyelia, adrenomyeloneuropathy, familial spastic paraparesis, HTLV-1 myelopathy
Central nervous system	Parkinson's disease, Creutzfeldt-Jacob disease, Huntington's disease, brainstem stroke, brainstem glioma, foramen magnum tumor
Systemic disorder	Hyperthyroidism, hyperparathyroidism

*From* Mitsumoto H, Chad DA, Piro EP. The differential diagnosis of ALS. In *Amyotrophic lateral sclerosis*. Philadelphia: FA Davis; 1998:87–121; with permission.

On rare occasions when the diagnosis of ALS proves difficult to establish, a muscle biopsy may be performed to confirm the presence of acute and chronic denervation and to rule out evidence for inflammatory or toxic myopathy that might simulate ALS.

### Electrophysiologic evaluation

Electrophysiology is the centerpiece of the diagnostic evaluation. According to the El Escorial revised criteria [6], there are three reasons for performing the EMG in the patient with suspected ALS: (1) to confirm LMN dysfunction in clinically affected regions; (2) to detect electrophysiological evidence of LMN dysfunction in clinically uninvolved regions; and (3) to exclude other pathophysiological processes.

There are two major components of the electrophysiologic assessment of the peripheral nervous system in the patient with suspected ALS: nerve conduction studies and the concentric needle electrode examination (NEE). Motor nerve conduction and sensory studies are considered first.

#### *Nerve conduction studies*

Sensory studies comprise conventional assessments of sensory nerve action potential amplitudes, distal latencies, conduction velocities and H reflexes. Motor studies comprise conventional assessments of evoked motor response amplitudes (with careful attention to the possibility of partial

conduction block), distal latencies, nerve conduction velocities, F-wave latencies, and sequential evoked motor amplitudes with repetitive nerve stimulation. An additional technique used to monitor motor neuron degeneration in ALS is motor unit number estimation (MUNE) that attempts to estimate the number of motor units innervating a given muscle.

The revised El Escorial criteria [6] pertaining to nerve conduction studies for the diagnosis of ALS indicate that both sensory and motor studies “should generally be normal or near normal.” They indicate further “that the studies are required principally to define and exclude other disorders of peripheral nerve, neuromuscular junction and muscle that may mimic or confound the diagnosis of ALS.” The next few sections discuss nerve conduction study findings in greater detail.

### *Sensory conduction studies*

Because ALS is essentially a pure motor disorder, it is expected that routine sensory studies will be normal. In fact, a normal sensory nerve action potential in the face of severe muscle atrophy is the hallmark of a motor neuronopathy or neuropathy. Nonetheless, there are instances of abnormal sensory electrophysiology that may be encountered in ALS. Some elderly patients with ALS may be expected to lose sensory responses in the legs (sural and superficial peroneal responses may be attenuated or absent) and have absent H-reflexes bilaterally because of the effects of aging. Entrapment neuropathies commonly coexist with ALS and the involved nerves may have abnormalities in one or more parameters. Finally, mild axonal sensory polyneuropathies may also occur in ALS patients. Indeed, two kinds of subtle sensory abnormality have been found in some clinically definite ALS patients without risk factors for a peripheral sensory disorder [10]. First, the amplitude of the sensory action potential may be reduced. Second, the conduction velocity of the slowest conducting component of the sensory fiber action potential (known as the minimum conduction velocity) may be reduced. The latter may reflect a mild “dying back” axonopathy of peripheral sensory fibers in ALS [11]. In a prospective clinical and electrophysiological study, Gregory et al [12] found that sensory nerve dysfunction progresses in parallel with motor decline.

Excluding the aging effect, the H-reflex is usually obtainable in ALS since the sensory component (IA spindle afferent fibers) remains intact and the excitability of the motor neuron pool that can be activated by the H-reflex pathway is increased [13]. This latter phenomenon, relating to clinical signs of upper motor neuron involvement, increases the H response amplitude and thus tends to increase the ratio of the H to the M maximum amplitudes (Hmax/Mmax) [14].

If substantially reduced or absent sensory action potentials are elicited in the patient with suspected ALS, particularly in the early stages, and aging and entrapment have been excluded as causes, then consideration should

turn to diagnoses other than ALS. These include a sensory axonopathy or neuronopathy in the context of bulbospinal neuronopathy (Kennedy's syndrome) as well as other neuromuscular disorders such as polyradiculoneuropathies including chronic inflammatory demyelinating polyneuropathy [13].

### *Motor conduction studies*

Evoked motor responses are usually normal in the early stages of ALS, although sometimes there are asymmetric reductions of the evoked compound muscle action potentials (CMAPs) at initial presentation, reflecting early focal or multifocal, predominantly distal limb muscle weakness and atrophy. As the disease progresses with its attendant progressive loss of motor units, one typically finds CMAP amplitude reductions to be widespread.

When CMAP amplitudes are normal or only mildly decreased, motor conduction velocities and distal latencies are typically normal, but as muscle weakness and atrophy progress and spread, there is a mild increase in distal motor latencies, a mild decrease of motor conduction velocities, and a mild prolongation of F-wave latencies. This association of low CMAP with reduced motor nerve conduction velocity stems from the loss of the motor units with the fastest conducting myelinated motor fibers. Accordingly, the myelinated motor fibers that remain conduct relatively slowly, but their minimum velocity is 35 meters/second or approximately 75% of the lower limit of normal [15]. Velocities slower than this fall in the range of acquired demyelination and with occasional exceptions (see below) are inconsistent with the diagnosis of ALS.

Lambert and Mulder [16] observed that the changes in motor conduction velocity in 100 ALS patients were generally minor compared to findings in "chronic peripheral neuropathy or polyneuropathies such as the Guillain-Barré syndrome or Charcot-Marie-Tooth disease." They noted that the conduction velocity of the ulnar nerve was within the normal range in 90% of the 100 patients and was seldom less than 75% of the average conduction velocity in a group of normal patients. In a larger study of 322 ALS patients, Lambert [17] showed that the mean conduction velocity of the ulnar nerve in the forearm segment was 55 meters/second, 8% below the normal mean; and, for the peroneal nerve in the foreleg segment, 44 meters/second, 16% below the normal mean. As the ulnar CMAP amplitudes fell in the ALS patient group, the ulnar motor conduction velocities gradually declined; CMAP amplitudes less than 1 mV were associated with a mean conduction velocity of 48 meters/second. In only 2.5% of all subjects did the mean values fall below 40 meters/second, the lowest being 33 meters/second. Also, the distal latency prolongation correlated inversely with the CMAP amplitude.

Cornblath et al. [18] sought to determine the limits of abnormality in motor nerve conduction parameters for the ulnar, median and peroneal nerves evoked from atrophic muscles in a group of 61 patients who met a

strict clinical definition of ALS. They related conduction velocity, distal latency and F-wave latency to distal CMAP in the three nerves. They found that distal latency was rarely greater than 125% of the upper limit of normal and that higher values occurred in only 4% of measurements. Motor nerve conduction velocity was never less than 70% of the lower limit of normal and was rarely (1% of observations) below 80% of the lower limit of normal. For the F-wave, Cornblath et al. [18] found that only 1% of values was greater than 125% of the upper limit of normal.

The experience with F-waves in ALS is that their response frequency is usually reduced with 50% of delivered stimuli failing to elicit an F-wave [19]. Ultimately, with progressive loss of motor units and the resulting reduction of CMAP amplitudes, F-wave responses cannot be elicited.

Felice [20] reported that comparisons between 13 ALS and 10 normal subjects did not disclose a significant difference in median distal motor latencies and motor conduction velocities. However, using automated F-wave analysis for the investigation of single thenar motor unit conduction velocity, he found significant reductions in ALS units compared to controls. He postulated that the motor nerve slowing occurred at proximal sites and was related possibly to impairment of axonal transport due to neurofilament accumulation and axonal swelling that have been described at these proximal levels [21].

Behnia and Kelly [22] caution that interpretation of motor conduction velocity may be difficult in limbs with low CMAP amplitudes recorded from atrophic muscles. First, motor conduction is likely to be excessively slowed by the presence of degenerating or regenerating, thinly myelinated axons. Second, despite warming, the reduced muscle mass and lack of movement may lead to erroneously slowed conduction velocity because of difficulty maintaining ideal temperature in deeper tissues, in the vicinity of the nerve. Accordingly, these authors suggest that accurate determination of motor conduction parameters should be performed on nerves with relatively well preserved CMAP amplitudes of at least 50% of the lower limit of normal. Likewise, F-wave latencies should be performed in nerves with similar CMAP amplitudes.

Care must also be taken in the interpretation of prolonged distal motor latencies in the setting of pronounced muscle atrophy with attendant low CMAPs [19]. Distal motor latencies may also be prolonged out of proportion to the degree of conduction slowing because of cool atrophic extremities, local entrapments and nerve terminal sprouting; the latter associated with incompletely myelinated new collateral sprouts conducting nerve impulses inefficiently, thereby increasing distal latency.

The issue of whether or not definite partial conduction block is present in the patient with suspected ALS is complex, yet critically important from the diagnostic standpoint. There are two aspects to consider. First, patients with a relatively benign or potentially treatable disorder—multifocal motor neuropathy with conduction block—may present clinically in a fashion that



may strongly resemble ALS with a lower motor neuron onset ([23–25] (see later discussion) and patients with ALS per se may demonstrate a greater amplitude difference between distal and proximal stimulating sites than is seen in individuals without ALS, simulating partial conduction block. The latter phenomenon results from phase cancellation and the mild slowing of motor conduction velocity that is common in ALS when CMAP amplitude is reduced to less than 50% [26]. Consensus criteria for probable and definite partial conduction block have been developed and the reader should consult this document [27] for a full treatment of the subject. To highlight just one among several consensus criteria—probable partial conduction block over a segment of 3 cm or less requires reduction in amplitude and area by 10% without significant temporal dispersion.

#### *Repetitive nerve stimulation*

Abnormalities may also be found in repetitive nerve stimulation (RNS) studies in ALS patients. Bernstein and Antel [28] found a significant decrement of the CMAP recording the abductor digiti minimi in response to 2-Hz RNS of the ulnar nerve at the wrist in patients with rapidly progressive disease, not in patients with slowly developing ALS. Subsequent studies have found some decrement in more than half of patients with ALS, usually less than 10%, with the same characteristics of the decrement seen in myasthenia gravis [26,29]. The pathogenesis of the decrement is likely related to the reduced safety factor in neuromuscular junctions of reinnervated muscle fibers. The more pronounced decrement in rapidly progressive disease may correlate with instability of neuromuscular transmission in collateral nerve terminal sprouts in this form of ALS [22,26] (see later discussion).

Table 4 reviews the key points pertaining to routine conduction studies, and Table 5 summarizes the changes in nerve conduction study parameters at different stages of ALS.

#### *Motor unit number estimate*

Motor unit number estimate (MUNE) is an electrophysiological technique that measures the approximate number of LMNs innervating a single muscle or a small group of muscles [30]. The MUNE count is determined through division of the supramaximal CMAP amplitude or area by the mean surface-recorded motor unit potential amplitude or area. Gooch and Harati [31] point out that the technique enables a quantitative estimate of the number of functional motor units and allows tracking of the progressive loss of motor units over months to years. In a longitudinal study of ALS the decrease in MUNE over a 6-month interval was significantly greater than the decrease in CMAP (or grip strength) [32]. This result indicates that following MUNE over time provides a more sensitive measure of the rate of progression of ALS than monitoring CMAP or grip strength over time. Although not employed routinely in the electrodiagnostic process, MUNE

Table 4  
Nerve conduction studies in ALS

Features consistent with ALS	Features inconsistent with ALS
Motor conduction times should be normal, unless the CMAP is small	Evidence of motor conduction block
Sensory nerve conduction studies can be abnormal in the presence of entrapment syndromes and coexisting peripheral nerve disease	Motor conduction velocities lower than 70%, and distal motor latencies over 30%, of the lower and upper limit of normal values, respectively
Lower extremity sensory nerve responses can be difficult to elicit in the elderly	Abnormal sensory nerve conduction studies <sup>a</sup> F-wave or H-wave latencies more than 30% above established normal values Decrements greater than 20% on repetitive nerve stimulation at 2 Hz

<sup>a</sup> With the exception of age, entrapments, and coexisting sensory polyneuropathy (see text). CMAP = compound muscle action potential.

Data from Brooks BR, Miller RG, Swash M, et al. El Escorial revisited: revised criteria for the diagnosis of amyotrophic lateral sclerosis. *Amyotroph Lateral Scler Other Motor Neuron Disord* 2000; 1:293–9.

has potential in studies of the natural history of ALS and of the response to experimental treatment [30].

### Needle electrode examination

We now turn to a consideration of the needle electrode examination (NEE) in the patient with suspected ALS. It is the most important diagnostic method for providing evidence of generalized motor neuron degeneration, even early in the course of the illness in apparently unaffected limbs

Table 5  
Nerve conduction study changes at different stages of ALS

Study	Stage		
	Early	Clinically obvious	Advanced
<i>Motor NCS</i>			
CMAP amplitude	N or ↓	↓ or ↓↓	↓ or ↓↓
Conduction velocity	N	N	N or ↓
Distal latency	N	N or ↑	N or ↑
<i>Sensory NCS</i>			
SNAP amplitude	N	N	N or ↓
Conduction velocity	N	N	N or ↓
H-reflex	N	N or ↓	N or ↓↓

*Abbreviations:* NCS = nerve conduction studies; N = normal; ↓/↑ = decreased/increased; one arrow = mild; two arrows = moderate.

From Mitsumoto H, Chad DA, Pioro EP. Electrodiagnosis. In *Amyotrophic lateral sclerosis*. Philadelphia: FA Davis; 1998. p. 65–86; with permission.

[33]. The revised El Escorial criteria [6] note that “features of LMN dysfunction in a particular muscle are defined by electromyographic concentric needle examination to provide evidence of active and chronic denervation including fibrillations and fasciculations.” The revised criteria further delineate the signs of active denervation—fibrillation potentials and positive sharp waves, and of chronic denervation—large motor unit potentials, reduced recruitment, and unstable motor unit potentials (Table 6). As we have seen, nerve conduction studies are required to recognize peripheral neuropathy, mononeuropathy, and polyradiculopathy all of which could produce the NEE findings seen in ALS [26]. Indeed these NEE signs are nonspecific, shared by “every subacute lesion of motor neurons or axons” [33]. It is the distribution of these acute and chronic signs in the patient with suspected ALS beyond the innervation territory of single nerve roots or peripheral nerves, or outside of a purely distal polyneuropathic pattern that raises the index of suspicion for the disease.

The revised El Escorial criteria describe the topography of active and chronic denervation required to support a diagnosis of ALS—that is, EMG signs of LMN dysfunction should be found in at least two of the four CNS regions (brainstem, cervical, thoracic, or lumbosacral) (Table 7). For the brainstem region to be involved, EMG signs may be found in one muscle (e.g., the tongue, facial or jaw muscle). For the thoracic spinal cord region to be considered positive, EMG signs must be found in either paraspinal muscles at or below T6 or in the abdominal muscles. (Because the thoracic region is rarely affected by spondylotic disease, the NEE of the thoracic paraspinal muscles is especially valuable electrodiagnostically; in fact it is deemed “strategic in the diagnosis of ALS” [34]. Findings of active and chronic denervation

Table 6  
Electrophysiological features of LMN dysfunction in ALS

Electrophysiological sign	Description
Active denervation	Fibrillation potentials Positive sharp waves
Chronic denervation	Large MUPs: increased duration, amplitude, and phases/turns Reduced interference pattern (reduced recruitment) with firing rates >10 Hz (unless there is a significant UMN component when rates may be <10 Hz) Unstable MUPs
Fasciculation potentials	Tend to be of long duration and polyphasic and almost always detectable

LMN = lower motor neuron; MUP = motor unit potential.

Data from Brooks BR, Miller RG, Swash M, et al. El Escorial revisited: revised criteria for the diagnosis of amyotrophic lateral sclerosis. *Amyotroph Lateral Scler Other Motor Neuron Disord* 2000; 1:293–9.

Table 7

Topography of active and chronic denervation in ALS: *Signs of LMN dysfunction should be found in at least 2/4 regions to support diagnosis of ALS*

Region of CNS	Considered positive when
Brainstem	One muscle is involved (eg, tongue)
Thoracic spinal cord	Paraspinal muscles at or below T6 or abdominal muscles are involved
Cervical spinal cord	At least two muscles innervated by different roots and peripheral nerves are involved
Lumbosacral spinal cord	At least two muscles innervated by different roots and peripheral nerves are involved

*Data from Brooks BR, Miller RG, Swash M, et al. El Escorial revisited: revised criteria for the diagnosis of amyotrophic lateral sclerosis. Amyotroph Lateral Scler Other Motor Neuron Disord* 2000; 1:293–9.

in thoracic paraspinal muscles are strongly supportive of anterior horn cell involvement.) Finally, for the cervical and lumbosacral spinal cord regions to be deemed affected by the disease process, EMG signs must be demonstrated in two muscles innervated by different roots and peripheral nerves.

In the next few sections of this review, we explore the development of and rationale for these criteria and discuss further the abnormal electrophysiologic signs in ALS. Table 8 depicts the NEE changes at different stages of ALS.

#### *Electrophysiologic diagnostic criteria: an historical perspective*

There is a tension inherent in the diagnostic approach to the patient with suspected ALS. On one hand is the reluctance to make a diagnosis of an incurable disease unless there is a high level of certainty in the diagnosis

Table 8

Needle electrode examination changes at different stages of ALS

Study	Stage		
	Early	Clinically obvious	Advanced
<i>At rest</i>			
Fasciculations	N or +	N to ++	N to ++
Insertional PSWs	+ or ++	+ to +++	+ to +++
Fibrillations	N or +	+ to +++	+ to +++
<i>MUPs</i>			
Recruitment	N or ↓	↓ or ↓↓	↓↓ or ↓↓↓
Duration	N or ↑	↑ or ↑↑	↑↑ or ↑↑↑
Amplitude	N	↑ or ↑↑	↑↑ or ↑↑↑
Complexity	N	+ or ++	+ or ++

MUPs = motor unit potentials; N = normal/none; ↓/↑ = decreased/increased; one arrow = mild; two arrows = moderate, three arrows = marked. + = mild; ++ = moderate; +++ = marked.

From Mitsumoto H, Chad DA, Pioro EP. *Electrodiagnosis*. In: amyotrophic lateral sclerosis. Philadelphia: FA Davis; 1998. p. 65–86; with permission.

and every other condition that could in any way resemble ALS has been excluded. On the other hand, however, for several reasons there is the need to establish the diagnosis as expeditiously as possible. First, it is difficult to live with uncertainty; from the patient's perspective, the unknown may be as stressful as the fact of diagnosis itself. Second, today patients may be treated with current and emerging therapies that might be most efficacious when instituted in the initial stages of the illness. Third, because in the initial phases of the disease nutritional status is good and neurological/respiratory function are still relatively well preserved, early diagnosis facilitates the enrollment of patients into increasingly available treatment trials [35].

The first topographic criteria for the diagnosis of ALS elaborated by Lambert and Mulder [16] were demanding. In an era without clinical trials or therapy for ALS there was little pressure to make the diagnosis early in the course of the illness; the overriding concern was to achieve diagnostic certainty and to rule out ALS-mimics. Lambert and Mulder [16] stipulated that the NEE findings comprise “fibrillation and fasciculation potentials in muscles of the lower as well as the upper extremities or in the extremities as well as the head.” Over the years it has become customary to consider the NEE component of the “Lambert criteria” satisfied if there are fibrillation potentials in at least three extremities or two extremities and cranial muscles (the head and neck considered an extremity) [26,36,37]. Table 9 lists the full “Lambert criteria” (including the requirements for nerve conduction studies discussed earlier) that have been used for the electrophysiologic assessment of the patient with suspected ALS for nearly 50 years [38].

In 1991 Behnia and Kelly [22] reviewed the role of electrodiagnostic testing in 133 patients with the clinical diagnosis of ALS and found that 30% of the patients did not fulfill the Lambert NEE criteria. Typically, these

Table 9  
Lambert criteria for the EMG diagnosis of ALS

Needle electrode examination criteria	Nerve conduction study criteria
Fibrillation and fasciculation potentials in muscles of the lower and the upper extremities, or in the extremities and the head	Normal electrical excitability of the remaining fibers of motor nerves
Reduction in number and increase in amplitude and duration of motor unit action potentials	Motor fiber conduction velocity within the normal range in nerves of relatively unaffected muscles Motor fiber conduction velocity not less than 70% of the average normal value according to age in nerves of more severely affected muscles Normal excitability and conduction velocity of sensory nerve fibers even in severely affected extremities

EMG = electromyography.

patients were found to have active denervation in one or two limbs or the bulbar muscles but not elsewhere; the findings were at least indicative of focal motor neuron disease, but not a generalized denervating disorder. Yet 37% of these patients had evidence of widespread chronic denervation, suggesting the presence of a diffuse disease. The authors proposed accepting the presence of “enlarged, polyphasic motor unit potentials with reduced recruitment (chronic denervation) as evidence of denervation with compensatory reinnervation if conduction studies in these limbs were normal” [22]. With this modification of the Lambert criteria, the non-diagnostic rate was reduced from 38% to 27%.

In 1990, in El Escorial, Spain, electrophysiologic features required for the diagnosis of ALS were proposed (in the context of a broad array of clinical and laboratory criteria) to enhance clinical studies and therapeutic trials [7]. These features required that confirmation of the diagnosis of ALS “depends on finding electrophysiologic evidence of LMN degeneration in at least two muscles of different root or spinal nerve and different cranial or peripheral nerve innervation in two or more of the four regions.” Additionally, for each muscle examined there were NEE requirements to qualify for the diagnosis of definite, probable, or possible ALS. Wilbourn [38] later highlighted selected aspects of these criteria for reappraisal, including the alteration in motor unit potential firing pattern in the case of UMN involvement, the usefulness of detecting fasciculation potentials, and the requirements for the distribution of NEE abnormalities.

This brings us to the revised ALS criteria developed at Airlie House in 1998, described earlier in this review (see earlier discussion, Table 2). The consensus document was reviewed and posted on the World Federation of Neurology ALS web site and was recently published [6]. The diagnostic criteria take into consideration some of the criticisms alluded to above, and they also include a new level of diagnostic certainty not present in 1994: “probable ALS—laboratory supported.” For this level, NEE findings qualify as evidence of LMN involvement as we explain later.

This new level of diagnostic certainty derives from the experience of Ross and colleagues [35]. They were motivated to relax the 1994 El Escorial criteria for establishing the diagnosis of ALS so that patients might have the opportunity to participate in clinical trials (in this instance, ciliary neurotrophic factor) in the early phases of their illness. They noted that early diagnosis might not be possible if it required widespread UMN and LMN disease since the clinical manifestations of ALS are often focal in the early stages. They cited the work of Chaudhuri et al. [39] who observed that when clinical features were correlated with postmortem neuropathologic findings that 25% of ALS patients died of the illness without meeting El Escorial criteria for definite or probable ALS.

To facilitate early diagnosis, less restrictive criteria were created: UMN signs were required in at least one region, and EMG signs of LMN involvement (fibrillation potentials) in at least two limbs. The fibrillation potential

activity was supposed to be found in at least two muscles innervated by different peripheral nerves and nerve roots. In addition, the “Ross et al. criteria” incorporated neuroimaging, electrodiagnostic, and laboratory studies to further define ALS and exclude alternative diagnoses. All patients who met the criteria were given the diagnosis of ALS without further division into subcategories. Using these criteria, the diagnosis of ALS was made at a mean time of 9.7 months from onset of symptoms, which compared favorably with the 12-month period cited in the literature. At the end of the clinical trial, the authors believed that based on clinical grounds the diagnosis of ALS was accurate in every patient, but there was no pathological confirmation. Therefore, confidence in these criteria appeared to be justified and led to “probable ALS–laboratory supported” being added to the revised WFN criteria [40].

#### *Active denervation changes*

Active denervation changes, also known as pathological or abnormal spontaneous activity (Table 6)—fibrillation potentials and positive sharp waves—have long been regarded as the hallmark of acute neurogenic disease and their presence is essential for the diagnosis of ALS (Fig. 1). They are however nonspecific, found in necrotizing myopathic disorders and rarely in long-standing disease of the neuromuscular junction. In the context of the evaluation for suspected ALS, fibrillation potentials and positive sharp waves are reliable indicators of ongoing loss of the anterior horn cell, representing the spontaneous discharge of single muscle fibers that have lost their innervation [26]. Fig. 2 depicts the morphological correlate of acute denervation—the angulated atrophic muscle fiber. Insertional positive sharp waves are probably the earliest indicators of denervation [19]. Fibrillation potentials are short in duration (0.5–2.0 msec) and low in amplitude (50–150  $\mu$ V) compared to motor unit potentials [13]. Lambert [16] noted that in ALS, fibrillation potentials are found in almost all muscles with less than normal strength but also in about 25% of clinically unaffected muscles. Troger and Dengler [33] observe that in the early stages of ALS, fibrillation potentials and positive sharp waves are often found focally and asymmetrically, generalizing as the disease progresses. They describe an especially high probability of finding fibrillation potentials and positive sharp waves in the tibialis anterior, first dorsal interosseous, abductor pollicis brevis, deltoid, and thoracic paraspinal muscles. Yet, the probability of finding pathologic spontaneous activity in the biceps brachii or vastus lateralis muscles was only 50%.

#### *Chronic denervation changes*

The revised criteria list three signs of chronic denervation (Table 6): large motor unit potentials, reduced interference pattern, and unstable motor unit potentials. We begin with a consideration of the pathophysiology underlying

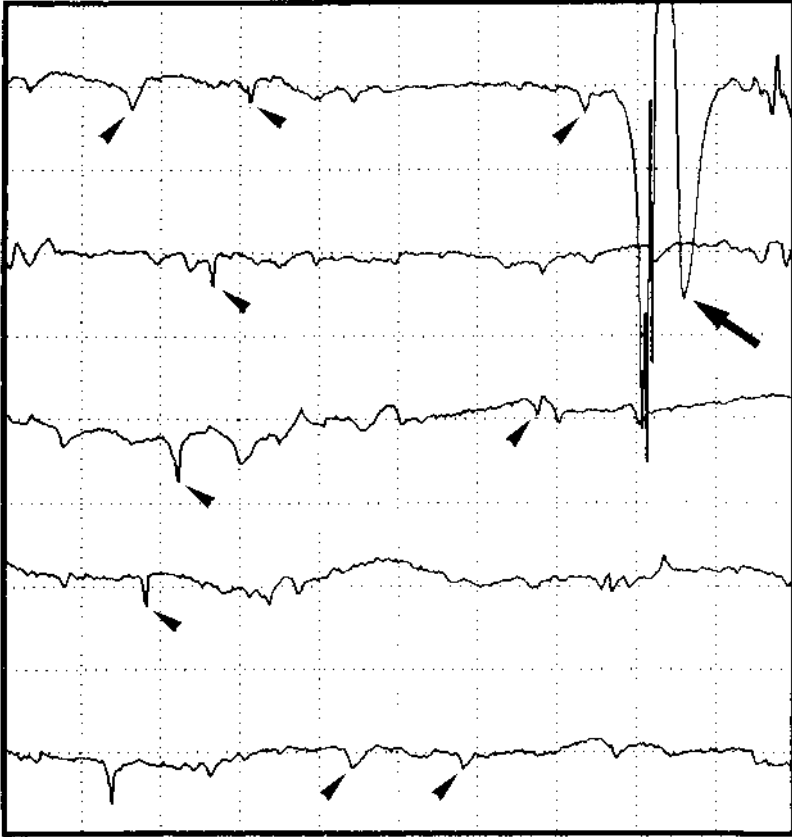


Fig. 1. Abnormal spontaneous activity in the denervating pronator teres muscle of a patient with moderately advanced ALS with frequent fibrillation potentials (*arrowheads*) and a fasciculation (*arrow*). Note that the fibrillation potentials are 50 to 100  $\mu\text{V}$  in amplitude. Each division represents gain = 200  $\mu\text{V}$ , sweep speed = 10 ms. (Courtesy of EP Piro, MD, D Phil, FRCP. © Cleveland Clinic Foundation; from Mitsumoto H, Chad DA, Piro EP. Amyotrophic lateral sclerosis. Philadelphia: FA Davis; 1998. p. 65–86, with permission.)

the development of large, sometimes unstable motor units (so-called motor unit potential remodeling) followed by discussion of changes in interference pattern (or recruitment).

*Motor unit potential remodeling.* Early on in the course of the illness, or in patients with slowly progressive ALS, fibrillation potentials, and positive sharp waves may be “limited in number and scattered in distribution” [26]. In fact, up to one half of the anterior horn cells can be lost before prominent fibrillation potentials develop. This presumably relates to reinnervation [41]: the effect of collateral sprouts from surviving motor units making contacts with denervated muscle fibers before they begin to fibrillate [26].



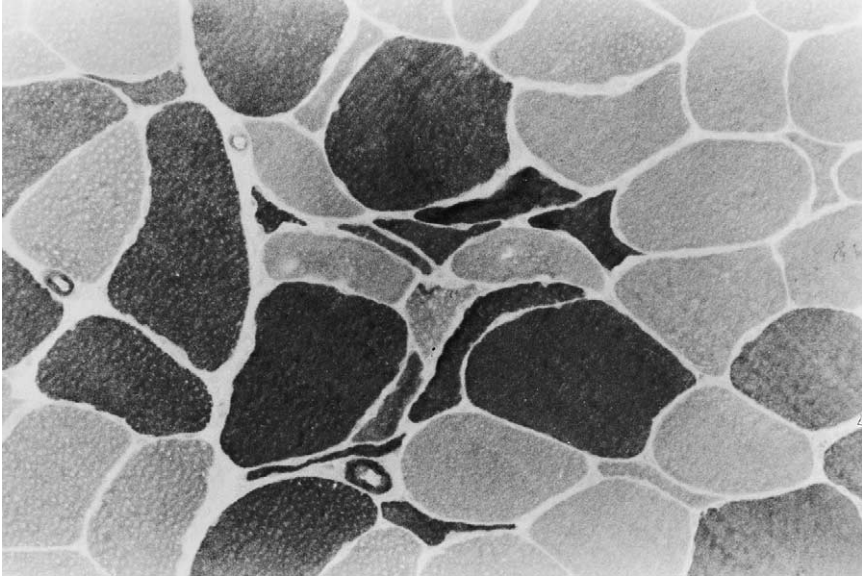


Fig. 2. Muscle biopsy showing early denervation. There are small groups of angulated, atrophic muscle fibers of both histochemical types. Type II fibers are darkly staining, and type I fibers are lightly staining. ATPase (pH 9.4)  $\times$  215 (before reduction). (Courtesy of TW Smith, MD, University of Massachusetts Medical Center; from Mitsumoto H, Chad DA, Pioro EP. Amyotrophic lateral sclerosis. Philadelphia: FA Davis; 1998. p. 122–33, with permission.)

This compensatory physiologic process, initiated by the loss of anterior horn cells, leads to enlarged motor unit potentials; the clinical correlate of this process is preserved muscle strength. This process continues until the capacity for terminal collateral sprouting has been exhausted [42]. Dengler [43] has shown in studies of the contraction force of the motor units in ALS that more than 50% of motor units can be compensated for by collateral sprouting. Presumably, as anterior horn cell loss continues beyond this point, the process of reinnervation by remaining motor neurons cannot keep up with denervation and muscle strength decreases [42].

The incorporation of previously denervated muscle fibers into an established motor unit may be referred to as motor unit remodeling [19]. The enlargement of surviving motor units is reflected in motor unit potentials of increased duration, increased amplitude and often an increased number of phases (four or more). This latter phenomenon (the development of polyphasic motor unit potentials) is secondary to the asynchrony of firing of new muscle fiber components belonging to the reinnervated motor unit and is an early finding in virtually all patients with ALS [26]. There are two reasons for this asynchronous activation [26,42]: first, because nerve conduction velocity will be slowed along immature sprouts that are incompletely myelinated; and

second, because the conduction velocity of muscle action potentials will be slowed along the atrophic muscle fibers of the reinnervated motor unit.

Polyphasic motor unit potentials may also be low in amplitude. There are two scenarios in which one encounters these potentials in ALS: in the rapidly progressive form of the disease, and late in the course of the illness. In the first instance, there may be insufficient time for collateral reinnervation, and in the latter case, when there are few residual anterior horn cells, the remaining motor units may decompensate [42]. These low-amplitude, polyphasic, sometimes short duration (“spikey”) potentials resemble the motor units seen in myopathic disorders, and in the company of fibrillation potentials might suggest a necrotizing myopathy, one form of which (inclusion body myositis) may simulate ALS (see later discussion).

Another phenomenon that results from reinnervation by an immature sprout is moment-to-moment variation in the appearance of a motor unit potential, also designated an unstable motor unit potential. There are two reasons for this EMG sign that results from the action potentials of certain muscle fibers coming in and out of the summated motor unit action potential: first, intermittent conduction block along an incompletely myelinated collateral sprout; second, inadequate release of acetylcholine at newly formed neuromuscular junctions. The presence of unstable motor unit potentials even after sufficient time (3 months) has elapsed for improvements in myelination and neuromuscular transmission is indicative of active disease and points to more rapidly progressive course [19,26]. Unstable motor unit potentials correlate with increased jitter and blocking measured in single fiber EMG studies. Jitter is the interval between action potentials of two repeatedly firing muscle fibers that belong to the same motor unit [19]. Increased jitter and blocking are electrophysiological manifestations of tenuous and failed neuromuscular transmission, respectively (Fig. 3).

When the disease is less aggressive (more slowly evolving), the collateral sprouts have the opportunity to mature, and reinnervated muscle fibers are able to regain their size. This leads to an increase in terminal nerve fiber conduction velocity and a more robust conduction velocity of muscle action potentials, respectively. As a result, there is greater synchrony of firing of individual muscle fiber components of the motor unit. With the reinnervated motor unit having gained more muscle fibers than it had originally, the result is an increase in both its amplitude and duration. As expected, fiber density, or the packing density of muscle fibers, assessed by single fiber EMG and measuring the number of muscle fibers innervated by one anterior horn cell increases because of collateral sprouting [44]. When studied longitudinally, fiber density was significantly increased in those patients with longer survival, suggesting that the capability for greater collateral sprouting is associated with better prognosis [32]. In advanced cases, decline in fiber density has been noted, possibly reflecting decompensation of the reinnervation process in the later phases of ALS [26].

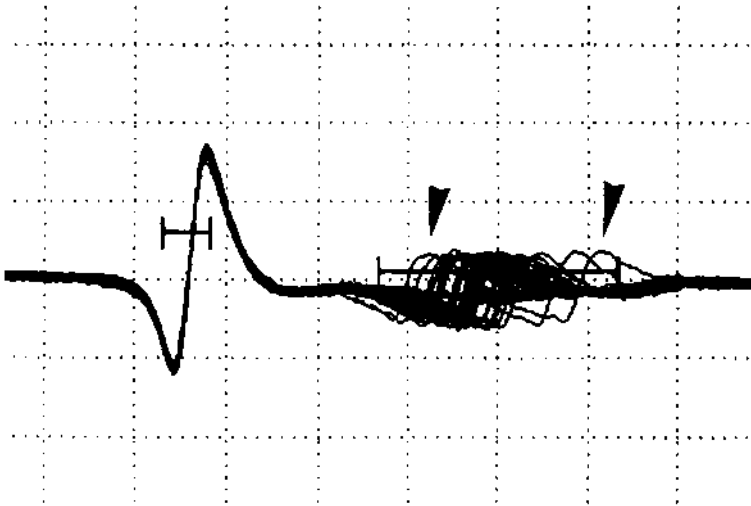


Fig. 3. Single fiber EMG recording of the brachioradialis muscle in a 59-year-old patient with rapidly progressive ALS revealing increased jitter between two muscle fibers innervated by the same motor unit. Firing of the muscle fiber used as the trigger is stable (*left*), but that of the nearby muscle fiber (*right*) is markedly variable (between *arrowheads*), indicating inefficient conduction through newly sprouted nerve terminals and related neuromuscular junctions. Approximately 10% of the motor units are blocked and do not fire (seen as the *flat line* through the region of increased jitter). Each division represents gain = 500  $\mu$ V. (Courtesy of EP Piro, MD, D Phil, FRCP. © Cleveland Clinic Foundation; from Mitsumoto H, Chad DA, Piro EP. Amyotrophic lateral sclerosis. Philadelphia: FA Davis; 1998. p. 65–86, with permission.)

*Altered interference pattern (changes in recruitment).* Normal recruitment refers to the orderly activation of more motor units as the effort and firing rate of individual units increases [26]. Recruitment frequency, or firing rate, is “the frequency of firing of a unit when the next unit is recruited or begins to discharge” [45]. This rate is typically 5–15 Hz for motor units in a normal muscle during mild contraction. The progressive loss of anterior horn cells during the course of ALS leads to a reduction in the number of motor units that may be activated during voluntary muscle contraction (reduced recruitment) along with an increase in firing rate of surviving motor unit potentials (Fig. 4). As the disease progresses, the NEE of weakened muscles might disclose a marked decrease in motor unit potential number with an considerable increase in firing rate; in advanced cases, two or three motor units firing at frequencies of 20 Hz [26].

Another description of the alteration in motor unit potential firing pattern in ALS, and one used in the El Escorial criteria [6], is “reduced interference pattern,” which has the same significance as reduced recruitment [46]. It indicates that some of the individual motor unit potentials can be clearly identified from the electrical activity recorded during full voluntary effort.

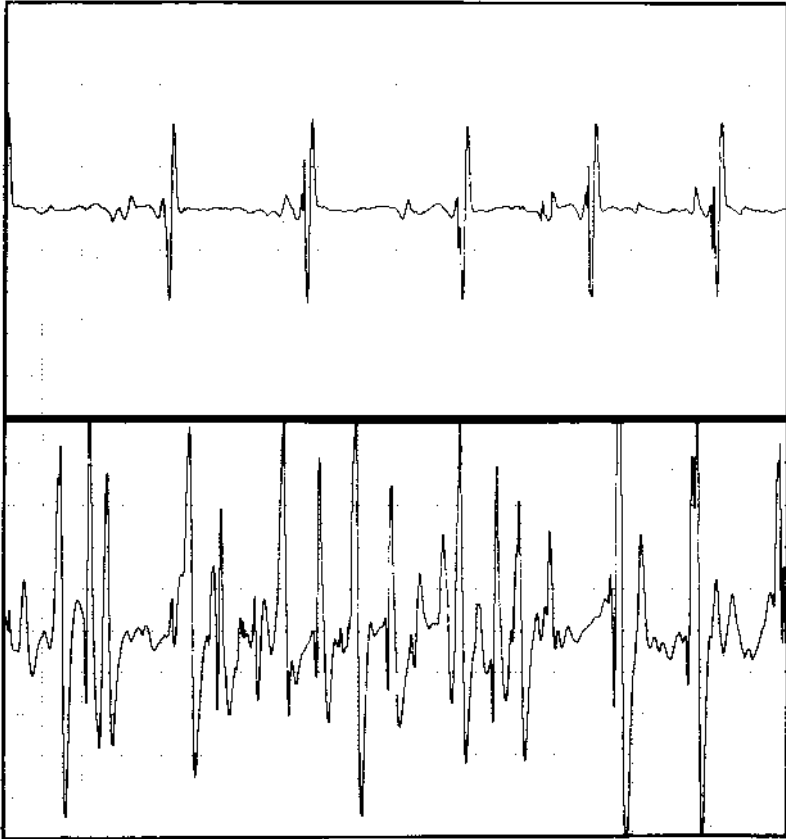


Fig. 4. Firing patterns of motor unit potentials at maximal effort of contraction in the abductor pollicis brevis muscles of a 50-year-old patient with rapidly progressive ALS. Recruitment is markedly impaired in the severely denervated left abductor pollicis brevis (*top*), whereas the interference pattern is full in the relatively normal muscle on the right (*bottom*). Note that the increased firing pattern of the remaining single motor unit potential in the denervated muscle (*top*) is approximately 30 Hz. Each division represents gain = 500  $\mu$ V, sweep speed = 10 ms. (Courtesy of EP Pioro, MD, D Phil, FRCP. © Cleveland Clinic Foundation; from, Mitsumoto H, Chad DA, Pioro EP. Amyotrophic lateral sclerosis. Philadelphia: FA Davis, 1998. p. 65–86, with permission.)

In contrast, the description “full interference pattern” refers to the electrical pattern in normal muscle wherein no individual motor unit potential can be clearly identified because there has been no drop out in motor units.

If the only target of the disease process in ALS were the anterior horn cell, then motor unit potential firing might be reliably described as “reduced interference pattern with firing rates higher than 10 Hz” as noted in Table 6. The normal basal firing rate is 5–10 Hz and if firing exceeds this window, it indicates a drop out of motor units. By definition, however, “ALS has an

UMN component that causes both a reduction in number of motor unit potentials because fewer units can be recruited, but also a reduction in the firing frequency of those motor units that can be activated” [38]. Willbourn points out that in the setting of both UMN and LMN pathology, the UMN component dictates the motor unit potential firing pattern. Accordingly, the revised criteria (Table 6) stipulate that “firing rate may be lower than 10 Hz if there is a significant UMN component.”

### *Fasciculation potentials*

Fasciculation potentials are spontaneous, irregularly discharging motor unit potentials that are often associated with a visible muscle twitch [19]. (In the clinical context, they are found in nearly all ALS patients, but are an uncommon presenting manifestation.) Except for motor neuropathy and amyloid polyneuropathy, diffuse fasciculation potential activity is strongly suggestive of disordered function of the motor neuron cell body [47]. In fact Lambert [17] observed that “fasciculations occur so regularly in ALS that one rarely accepts the diagnosis unless fasciculations are demonstrated.” Fasciculation potentials also occur in otherwise healthy individuals, as so-called “benign fasciculations.” Benign fasciculations are an isolated NEE finding without accompanying fibrillation potential activity, enlarged or unstable motor unit potentials; and clinically, weakness and wasting are conspicuously absent.

Fasciculation potentials in ALS are typically more complex and less stable than similar discharges in healthy individuals (Fig. 1) [48,49]. It is likely that these potentials become enlarged in the process of denervation and reinnervation, as described in the discussion of chronic denervation (see earlier discussion in this article). The origin of fasciculation potentials has been debated, but they can probably arise from the anterior horn cell, nerve trunk, and distal nerve terminals [5,49]. It is possible that they arise in the more proximal portion of the motor unit early in the disease and in more distal motor axons in the later stages [48,49].

### **Differential diagnostic highlights**

We turn now to some of the disorders, and their electrophysiological signatures, that tend to come up for consideration with some regularity in the differential diagnosis of ALS [5].

### *Spondylotic myelopathy*

Spondylotic myelopathy may lead to spinal cord compression with or without nerve root compromise. Neck pain is a common but not invariable clinical feature. Some patients with myelopathy develop UMN signs in the legs and if there is coexisting central gray matter or nerve root involvement

or both a subset of patients may have additional LMN signs in the arms, simulating ALS. In fact, in the experience of the Eleanor and Lou Gehrig Center at the New York Institute, Rowland reports that 5% of patients with ALS have had cervical (or lumbar) laminectomies early in their course [47]. Although the NEE may disclose active and chronic denervation in both arms in cervical spondylosis (and the legs if there is coexisting lumbosacral spondylosis), the NEE of bulbar and thoracic paraspinal muscles should be normal, in contrast to the frequent abnormal NEE findings in ALS.

The presence of lower and upper extremity proprioceptive loss and sphincter abnormalities often accompanies the clinical picture of motor weakness in spondylotic myelopathy, however, and suggest a structural abnormality of the cervical spine. Neuroimaging of the cervical cord is necessary to help establish the diagnosis.

### *Bulbospinal neuronopathy*

Bulbospinal neuronopathy or Kennedy's syndrome is an X-linked disorder that results in slowly progressive, symmetric, bulbar and proximal limb muscle weakness, cramps and atrophy without UMN features. Fasciculations are prominent in perioral facial muscles and the tongue. Deep tendon reflexes are depressed or absent. In more than 50% of patients, there are signs of partial androgen deficiency like gynecomastia and infertility. The creatine kinase is typically elevated to a higher degree than would be seen in a purely denervating disorder. The NEE shows evidence of a LMN disorder (active and chronic denervation) but the sensory evoked potentials are reduced or even absent suggesting involvement of sensory axons or dorsal root ganglia neurons [50], a finding that raises serious questions about the validity of the diagnosis of ALS. The diagnosis may be established definitively by genetic testing, demonstrating an expansion of the cytosine-adenine-guanine trinucleotide repeat within the translated portion of the androgen receptor gene.

### *Benign monomelic amyotrophy*

Benign monomelic amyotrophy is a sporadic disorder that presents with focal weakness involving a single limb and affects men five times more frequently than women. The age of onset is between 15 and 30 years and most of the patients described have been from Japan and India. Most often, weakness begins in the hand intrinsic muscles and then spreads centripetally for 1 to 2 years to involve the forearm flexors and extensors. After this slow progression the condition usually stabilizes. Deep tendon reflexes are usually normal or reduced. UMN signs and bulbar involvement are not encountered. The electrophysiologic findings parallel the clinical signs in revealing evidence for a restricted LMN disorder. Routine nerve conduction studies are generally normal except for the presence of low motor amplitudes when recording from atrophic hand muscles. Modest reductions in sensory potentials are found in 30% of cases. The NEE reveals fibrillation potentials and

positive sharp waves in less than half the patients, whereas recruitment is invariably reduced in a pattern corresponding to areas of weakness and atrophy [51]. The NEE of muscles in the limb that appears to be uninvolved typically discloses features of chronic denervation, suggesting more widespread LMN disease than is apparent clinically. Magnetic resonance imaging (MRI) of the cervical spine may disclose focal atrophy of the spinal cord.

### *Multifocal motor neuropathy with conduction block*

Multifocal motor neuropathy with conduction block (MMNCB) is arguably the most important condition in the differential diagnosis of ALS [47]. This is because it “can simulate ALS clinically but differs because it is responsive to immunotherapy” [47]. The disorder affects men primarily at a relatively young age (<45 years) and usually presents as slowly progressive, painless, remarkably focal weakness and amyotrophy involving the small hand muscles [24,25]. Weakness begins typically unilaterally, progresses for a number of years, and then appears in the contralateral limb. Clinical deficits correspond to individual peripheral nerves and remain restricted in their anatomic distribution for years. The examination discloses marked atrophy of the intrinsic hand and forearm muscles; the humeral and shoulder girdle muscles are less frequently affected. Lower extremity weakness is infrequent and cranial nerve involvement is rare. Fasciculations and cramps are common. Deep tendon reflexes may be attenuated, especially in weak limbs, but occasionally they are normally active or unexpectedly brisk for the degree of muscle atrophy and weakness. Most remarkable is the preservation of sensation, even in regions where muscles are markedly atrophic. Diagnosis rests on the findings from electrophysiologic study that show evidence of a LMN disorder, but in contrast to ALS, the defining abnormality is partial conduction block (Fig. 5) along focal segments of motor fibers in regions not usually susceptible to compression [52]. Additional features of multifocal motor demyelination are also found including temporal dispersion, segmentally reduced motor nerve conduction velocity, prolonged distal motor latency, and prolonged F-wave latency. In some series, conduction block per se is found only in 30% of patients, but virtually all patients have nerve conduction study evidence for demyelination [53]. Fifty to sixty percent of patients have high titers of antibody reacting with the GM1 ganglioside, whereas in the vast majority of patients with ALS this autoantibody is either not detected or is present in low titer. As noted, the condition is responsive to immunotherapy including cyclophosphamide and intravenous gamma globulin.

### *Diseases of the neuromuscular junction*

When myasthenia gravis presents with dysarthria, dysphagia, drooling, and head drop with no ocular symptoms or signs it may simulate bulbar onset ALS. When Lambert-Eaton myasthenic syndrome (LEMS) presents with limb girdle weakness and fatigability, it may suggest ALS with a

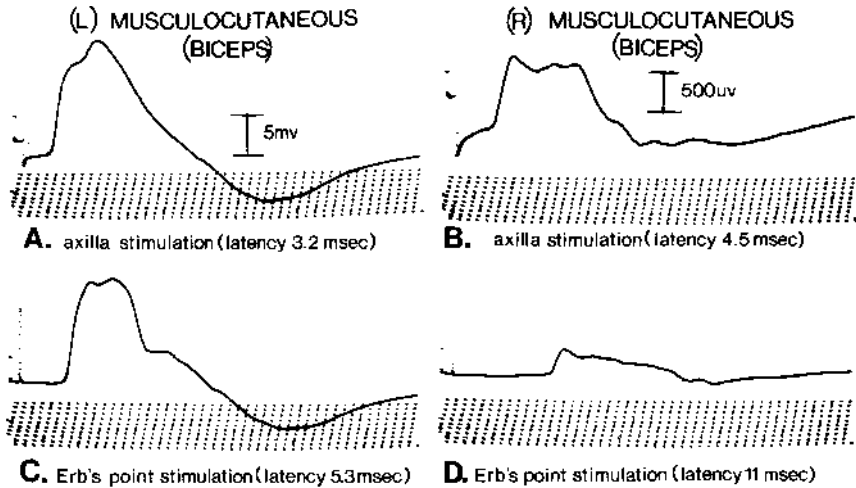


Fig. 5. A 26-year-old man with multifocal motor weakness. (A and C) Compound muscle action potential (CMAP) recorded from the left biceps after stimulating the left musculocutaneous nerve at the axilla (A) and Erb's point (C). Latency, amplitude, and form of the responses are normal. (B and D) CMAPs recorded from right biceps after stimulating the right musculocutaneous nerve at the axilla (B) and Erb's point (D). Note the low-amplitude response in B (in contrast to A) and the further loss of amplitude and severely prolonged latency in D, indicating partial conduction block. Time scale: each ramp = 1 ms. (From, Chad DA, Hammer K, Sargent J. Slow resolution of multifocal weakness and fasciculation: a reversible motor neuron syndrome. *Neurology* 1986;36:1260–3, with permission.)

LMN onset. These diseases of the neuromuscular junction have well known abnormal serological test results (acetylcholine receptor antibody positivity and voltage-gated calcium channel antibody positivity for myasthenia gravis and LEMS, respectively) and characteristic electrophysiologic findings that help make the distinction from ALS. In myasthenia gravis there is typically a decremental motor response of >10% as well as an increase in jitter between two muscle fibers innervated by the same motor unit. Although these findings may be encountered in weakened muscles of patients with ALS, electrophysiologic evidence for LMN degeneration is lacking in myasthenia gravis. In LEMS, the diagnostic finding is very low initial motor evoked responses that increase by more than 200% after a brief (15-second) period of exercise. Although initial motor evoked responses are also low in ALS, the post-activation facilitation response does not occur.

### *Inclusion body myositis*

Inclusion body myositis (IBM) is an inflammatory myopathy most often seen in older men. It tends to present in an asymmetric, patchy fashion with a predilection for weakness and atrophy of the forearm flexors, triceps,



biceps, and quadriceps. It may resemble a limb onset LMN form of ALS [54]. The CK is typically elevated to a modest degree and the muscle biopsy is diagnostic. The electrophysiologic findings usually suggest a necrotizing myopathy (evidence for active denervation with early recruited low-amplitude, short duration, polyphasic motor unit potentials), but when IBM is in its later discussion phases, the NEE may show motor unit potentials and recruitment characteristics of chronic denervation, features seen in the context of ALS. Complicating the diagnostic process is the NEE finding of fasciculation potentials in some patients with IBM [54].

Helping to make the distinction between ALS and IBM are specific clinical features in the latter disorder, especially early weakness of finger flexors, weakness of the quadriceps, slow progression, lack of UMN signs, and rarity of clinically visible fasciculations. Quantitative electromyography may provide evidence for a myopathic disorder even when routine NEE does not show a myogenic disorder [54]. A muscle biopsy should be obtained in circumstances that are diagnostically ambiguous looking for evidence of an inflammatory myopathy with rimmed vacuoles, the morphological hallmark of IBM.

### **Overview of the electrodiagnostic approach to the patient with suspected ALS**

As we have seen, the electrodiagnostic study is important for several reasons, most notably to confirm the diagnosis and to exclude diseases of the peripheral nervous system that might mimic some clinical aspect of ALS. The study also assists in defining the severity, rate of progression, and prognosis of ALS [19,26]. In this concluding section of the review we summarize the parts of the electrophysiologic study most often employed in the evaluation of the patient.

We typically begin with *sensory conduction studies*—median, ulnar, radial, sural, and superficial peroneal—evaluating sensory amplitudes, distal latencies, and conduction velocities, ensuring maintainance of skin temperature at (33°C hand; 30°C foot) a challenge in the patient with thin, atrophic limbs [36]. As already described, the expectation is for essentially normal sensory evoked responses, distal latencies, and conduction velocities (Table 4) until the advanced stages of the disease (Table 5). Although a disorder of peripheral nerves might well co-exist with ALS (most commonly focal nerve entrapments), significant and generalized abnormalities must increase the index of suspicion for a peripheral neuropathy or neuronopathy and cast doubt on the diagnosis of ALS. In the face of such sensory abnormalities, we raise our diagnostic antennae to detect a peripheral neuropathy (specifically chronic inflammatory demyelinating polyneuropathy) during the remainder of the study.

The next step is to evaluate *motor conduction parameters* (amplitudes, distal latencies, conduction velocities, and F-wave latencies) for upper and lower extremity nerves comprising the median, ulnar, peroneal, and posterior tibial (Table 4). A critically important task is to look for partial motor conduction block and other electrophysiologic signatures for acquired demyelination, such as one might encounter in multifocal motor neuropathy with conduction block. Although reductions in motor amplitudes are expected as the disease progresses, low CMAPs in a widespread distribution especially in the early stages of the disease, coupled with essentially normal sensory studies should suggest several possibilities [13,19]. First, we consider Lambert-Eaton myasthenic syndrome, a diagnosis that may be corroborated by showing post-exercise facilitation of evoked motor responses. Second is the possibility of severe polyradiculopathy (in the setting of combined cervical and lumbar spinal stenosis with root involvement), which typically spares thoracic roots and lead to an essentially normal NEE of paraspinal or abdominal muscles. The third possibility is a severe myopathy whose NEE signature is abnormal in affected limb and paraspinal muscles (early recruitment of short duration, low amplitude polyphasic motor unit potentials) but is typically normal in bulbar muscles.

We then turn to the *NEE* taking care to evaluate muscles in the most clinically involved limb first, testing proximal and distal muscles innervated by different nerve roots and peripheral nerves [26]. A region is considered involved when reduced recruitment, large motor unit potentials, and fibrillation potentials are found in one muscle (for the bulbar or thoracic regions) or two limb muscles with different innervation (for the cervical and lumbosacral regions) (Table 7). From the most involved limb we move to other limb or thoracic paraspinal muscles reserving the bulbar region for last (because it is more difficult to evaluate and interpret) and typically necessary only if the diagnosis cannot be supported from the findings referable to non-bulbar regions.

For the upper extremity examination, suggested muscles include [19] the first dorsal interosseus, abductor pollicis brevis, extensor proprius indicis (C8/T1 roots; ulnar, median, radial nerves, respectively); flexor pollicis longus, pronator teres (C7 root; median nerve); biceps (C5/C6 roots; musculocutaneous nerve); triceps (C6/C7/C8; radial nerve); and low cervical paraspinals (C6/C7/C8/T1 roots). In the lower extremity, suggested muscles include the extensor digitorum brevis, (L5 root; peroneal nerve); abductor hallucis, gastrocnemius (S1 root; tibial nerve); tibialis anterior, flexor digitorum longus (L4/L5 roots; peroneal and tibial nerves, respectively); vastus lateralis, vastus medialis (L2/L3/L4 roots; femoral nerve); gluteus medius (L5 roots; superior gluteal nerve); and high sacral paraspinals (L4/L5/S1 roots). For the bulbar region suitable muscle selections include the tongue (cranial nerve XII), frontalis and orbicularis oculi muscles (cranial nerve VII); and the masseter (cranial nerve V). The thoracic region is best evaluated by examination of thoracic paraspinal muscles. To support the diagnosis of

ALS, signs of LMN dysfunction should be found in at least two of four regions (Table 7).

## References

- [1] Mitsumoto H, Chad DA, Pioro EP. Neuropathology. In: Amyotrophic lateral sclerosis. Philadelphia: A Davis;1998.p. 179–96
- [2] Mitsumoto H, Chad DA, Pioro EP. Epidemiology. In: Amyotrophic lateral sclerosis. Philadelphia: A Davis;1998 p. 18–33.
- [3] Ross MA. Acquired motor neuron disorders. *Neurol Clin* 1997;15:481–99.
- [4] Mulder DW, Howard FM. Patient resistance and prognosis in amyotrophic lateral sclerosis. *Mayo Clin Proc* 1976;51:537–41.
- [5] Mitsumoto H, Chad DA, Pioro EP. Clinical features: signs and symptoms. In: Amyotrophic lateral sclerosis. Philadelphia: FA Davis; 1998. p. 47–64.
- [6] Brooks BR, Miller RG, Swash M, Munsat TL, for the World Federation of Neurology Group on Motor Neuron Diseases. El Escorial revisited: revised criteria for the diagnosis of amyotrophic lateral sclerosis. *Amyotroph Lateral Scler Other Motor Neuron Disord* 2000;1:293–9.
- [7] Brooks BR. El Escorial World Federation of Neurology Criteria for the Diagnosis of Amyotrophic Lateral Sclerosis. *J Neurol Sci* 1994;124(Suppl):96–107.
- [8] Mitsumoto H, Chad DA, Pioro EP. The differential diagnosis of ALS. In: Amyotrophic lateral sclerosis. Philadelphia: FA Davis; 1998. p. 87–121.
- [9] Mitsumoto H, Chad DA, Pioro EP. Diagnostic investigation of ALS. In: Amyotrophic lateral sclerosis. Philadelphia: FA Davis; 1998. p. 122–33.
- [10] Shefner JM, Tyler HR, Krarup C. Abnormalities in the sensory action potentials in patients with amyotrophic lateral sclerosis. *Muscle Nerve* 1991;14:1242–6.
- [11] Bradley WG, Good P, Rasool CG, Adelman LS. Morphometric and biochemical studies of peripheral nerves in amyotrophic later discussional sclerosis. *Ann Neurol* 1983;14: 267–77.
- [12] Gregory R, Mills K, Donaghy M. Progressive sensory nerve dysfunction in amyotrophic lateral sclerosis: a progressive clinical and neurophysiological study. *J Neurol* 1993;240:309–14.
- [13] Pioro EP. Motor neuron disorders. In: Comprehensive clinical neurophysiology. Levin KH, Luders HO, editors. Philadelphia: WB Saunders; 2000. p. 235–49.
- [14] Mazzini L, Balzarini C. An overview of H-reflex studies in amyotrophic lateral sclerosis. *Amyotroph Lateral Scler Other Motor Neuron Disord* 2000;1:313–8.
- [15] Preston D, Shapiro B. Electromyography and neuromuscular disorders. Clinical-electro-physiological correlations. Boston: Butterworth-Heinemann; 1997.
- [16] Lambert EH, Mulder DW. Electromyographic studies in amyotrophic lateral sclerosis. *Mayo Clin Proc* 1957;32:441–6.
- [17] Lambert EH. Electromyography in amyotrophic lateral sclerosis. In: Norris FH, Jr, Kurland LT, editors. Motor neuron diseases. New York: Grune and Stratton; 1969. p. 135–53.
- [18] Cornblath DR, Kuncel RW, Mellits ED, Quaskey SA, Clawson L, Pestronk A, Drachman DB. Nerve conduction studies in amyotrophic lateral sclerosis. *Muscle Nerve* 1992;15:1111–5.
- [19] Mitsumoto H, Chad DA, Pioro EP. Electrodiagnosis. In: Amyotrophic lateral sclerosis. Philadelphia: FA Davis; 1998. p. 65–86.
- [20] Felice KJ. Nerve conduction studies of single thenar motor axons based on the automated analysis of F waves in amyotrophic lateral sclerosis. *Muscle Nerve* 1998;21:756–61.
- [21] Carpenter S. Proximal axonal enlargement in motor neuron disease. *Neurology* 1968; 18:841–51.
- [22] Behnia M, Kelly JJ. Role of electromyography in amyotrophic later discussional sclerosis. *Muscle Nerve* 1991;14:1236–41.

- [23] Chad DA, Hammer K, Sargent J. Slow resolution of multifocal weakness and fasciculation: a reversible motor neuron syndrome. *Neurology* 1986;36:1260–3.
- [24] Parry GJ, Sumner AJ. Multifocal motor neuropathy. *Neurol Clin* 1992;10:671–84.
- [25] Pestronk A. Invited review. Motor neuropathies, motor neuron disorders, and anti-glycolipid antibodies. *Muscle Nerve* 1991;14:927–36.
- [26] Daube JR. Electrodiagnostic studies in amyotrophic lateral sclerosis and other motor neuron disorders. *Muscle Nerve* 2000;23:1488–502.
- [27] Olney RK. Consensus criteria for the diagnosis of partial conduction block. *Muscle Nerve* 1999;8:S225–9.
- [28] Bernstein LP, Antel JP. Motor neuron disease: decremental response to repetitive nerve stimulation. *Neurology* 1981;31:202–4.
- [29] Dumitru D. Central nervous system disorders. In: *Electrodiagnostic medicine*. Philadelphia: Hanley and Belfus, Inc.; 1994. p. 453–521.
- [30] Olney RK, Lomen-Hoerth C. Motor unit number estimation (MUNE): how may it contribute to the diagnosis of ALS? *Amyotroph Lateral Scler Other Motor Neuron Disord* 2000;(Suppl 2):S41–S44.
- [31] Gooch CL, Harati Y. Motor unit number estimation, ALS and clinical trials. *Amyotroph Lateral Scler Other Motor Neuron Disord* 2000;1:71–82.
- [32] Yuen EC, Olney RK. Longitudinal study of fiber density and motor unit number estimate in patients with amyotrophic lateral sclerosis. *Neurology* 1997;49:573–8.
- [33] Troger M, Dengler R. The role of electromyography (EMG) in the diagnosis of ALS. *Amyotroph Lateral Scler Other Motor Neuron Disord* 2000;1(Suppl 2):S33–40.
- [34] Kuncel RW, Cornblath DR, Griffin JW. Assessment of thoracic paraspinal muscles in the diagnosis of ALS. *Muscle Nerve* 1988;11:484–92.
- [35] Ross MA, Miller RG, Berchert L, Parry MD, Barohn RJ, Armon C. Toward earlier diagnosis of amyotrophic lateral sclerosis: revised criteria. *rhCNTF ALS Study Group*. *Neurology* 1996;39:256–60.
- [36] Denys EH. Amyotrophic lateral sclerosis. *Muscle Nerve* 1994;17:263–8.
- [37] Swash M. Shortening the time to diagnosis in ALS: the role of electrodiagnostic studies. *Amyotroph Lateral Scler Other Motor Neuron Disord* 2000;1(Suppl 1):S67–72.
- [38] Wilbourn AJ. Clinical neurophysiology in the diagnosis of amyotrophic lateral sclerosis: the Lambert and El Escorial criteria. *J Neurol Sci* 1998;160(Suppl 1):S25–9.
- [39] Chaudhuri KR, Crump SJ, Al-Sarraj S, Anderson V, Cavanaugh J, Leigh PN. The validation of El Escorial criteria for the diagnosis of amyotrophic lateral sclerosis: a clinicopathological study. *J Neurol Sci* 1995;129(Suppl):11–2.
- [40] Bromberg M. Accelerating the diagnosis of amyotrophic later discussional sclerosis. *The Neurologist* 1999;5:63–74.
- [41] Wohlfart G. Collateral regeneration from residual motor nerve fibers in amyotrophic lateral sclerosis. *Neurology* 1957;7:124–34.
- [42] Bromberg MB. Electrodiagnostic studies in clinical trials for motor neuron disease. *J Clin Neurophys* 1998;15:117–28.
- [43] Dengler R. Current treatment pathways in ALS: a European perspective. *Neurology* 1999;53(Suppl 5):S4–S10.
- [44] Stalberg E, Schwartz MS, Trontelj JV. Single fiber electromyography in various processes affecting the anterior horn cell. *J Neurol Sci* 1975;24:403–15.
- [45] Daube JR. AAEM Minimonograph #11: Needle examination in clinical electromyography. *Muscle Nerve* 3–14, 1991
- [46] Jablecki CK, Bolton CF, Bradley WG, Buchthal F, Cracco RQ, Johnson EW. AAEE glossary of terms in clinical electromyography. *Muscle Nerve* 1987;10(Suppl 8):13.
- [47] Rowland LP. Diagnosis of amyotrophic lateral sclerosis. *J Neurol Sci* 1998;160(Suppl 1):S6–S24.
- [48] de Carvalho M. Pathophysiological significance of fasciculations in the early diagnosis of ALS. *Amyotroph Lateral Scler Other Motor Neuron Disord* 2000;1(Suppl 1):S43–6.

- [49] Desai J, Swash M. Fasciculations: what do we know of their significance? *J Neurol Sci* 1997;152:S43–8.
- [50] Olney RK, Aminoff MJ, So YT. Clinical and electrodiagnostic features of X-linked recessive bulbospinal neuronopathy. *Neurology* 1991;41:823–8.
- [51] Donofrio PD. Monomelic amyotrophy. *Muscle Nerve* 1994;17:1129–34.
- [52] Chaudhry V, Corse A, Cornblath DR, Kunel R, Freimer ML, Griffin J. et al. Multifocal motor neuropathy: electrophysiological features. *Muscle Nerve* 1994;17:198–205.
- [53] Katz JS, Wolfe GI, Bryan WW, Jackson CE, Amato AA, Barohn RJ. Electrophysiologic findings in multifocal motor neuropathy. *Neurology* 1997;48:700–7.
- [54] Dabby R, Lange DJ, Trojaborg W, et al. Inclusion body myositis mimicking motor neuron disease. *Arch Neurol* 2001;58:1253–6.