

# Nerve Compression Syndromes of the Upper Extremity: Diagnosis, Treatment, and Rehabilitation

P. KAVEH MANSURIPUR, MD; MATTHEW E. DEREN, MD; ROBIN KAMAL, MD

## ABSTRACT

Nerve compression syndromes of the upper extremity, including carpal tunnel syndrome, cubital tunnel syndrome, posterior interosseous syndrome and radial tunnel syndrome, are common in the general population. Diagnosis is made based on patient complaint and history as well as specific exam and study findings. Treatment options include various operative and nonoperative modalities, both of which include aspects of hand therapy and rehabilitation.

**KEYWORDS:** Upper extremity, nerve compression, rehabilitation, carpal tunnel, cubital tunnel

## INTRODUCTION

Upper extremity compression syndromes, including carpal tunnel syndrome, cubital tunnel syndrome, and radial tunnel syndrome, are common in the general population. Although they differ in the anatomic distribution of their symptoms, they share a similar pathophysiology and treatment.

As the nerves that control the upper extremity traverse the arm towards the hand, they pass through relatively fixed anatomical structures, or tunnels, usually as the nerve passes a joint. For instance, the carpal tunnel is bounded on three sides by the carpal bones of the wrist and on the fourth by the transverse carpal ligament; it marks the transition from the forearm to the hand. These tunnels are unable to accommodate swelling, which can occur due to renal failure, diabetes, thyroid disease, rheumatoid arthritis, and alcoholism; fractures at the site of the tunnel; and conditions involving physiologic fluid shifts, including pregnancy; most swelling, however, is idiopathic.<sup>1</sup> When swelling occurs within the limited volume of the tunnel, the nerve is compressed, which compromises the microvascular blood supply and leads to focal ischemia of the nerve. This in turn leads to demyelination, which disrupts nerve signal transmission; prolonged compression can lead to more permanent damage to the neurons themselves, including degeneration distal to the point of compression. The inflammation and ischemia also leads to fibrosis, which can further tether the nerve and lead to more traction injury during motion. This pathophysiologic process is experienced by the patient as pain, paresthesias, loss of sensation, and muscle weakness in the distri-

bution of the affected nerve. It is important to note that the presentation of cervical radiculopathy resembles that of peripheral nerve compression, and care must be taken to make the correct diagnosis. In some cases, the peripheral nervous system is compromised in both areas, a condition known as the double crush syndrome,<sup>2</sup> which also complicates the diagnosis and treatment.

## Carpal Tunnel Syndrome

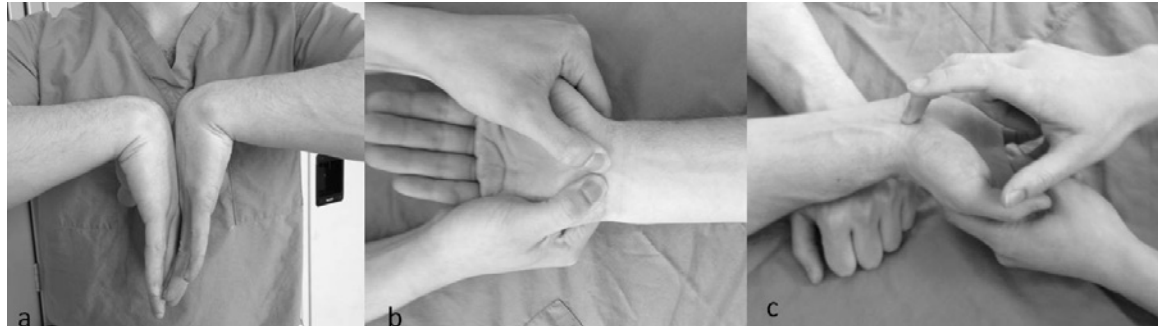Carpal tunnel syndrome (CTS) is the most common nerve compression syndrome of the upper extremity, with an incidence of 3% to 5% in the general population.<sup>3</sup> It is caused by compression of the median nerve as it crosses through the fibroosseous carpal tunnel at the wrist, along with the nine extrinsic flexor tendons. Most cases are idiopathic and work related, with a significantly proportion coming from occupations that involve manual force, repetition, and vibratory tools.<sup>4</sup>

Symptoms include loss of sensation and paresthesias in the distribution of the median nerve (thumb, index finger, middle finger, and radial half of the ring finger); a weak grip, clumsiness, and hand pain that awakens the patient at night. The clinical examination may reveal thenar atrophy, decreased sensation, and positive responses to provocative tests, including Phalen's, Durkan's, and Tinel's (Figure 1). Decreased two-point discrimination may be more prevalent in the advanced stages of the disease.<sup>5</sup> Electrodiagnostic testing also has typical findings including increased motor and sensory latencies and decreased conduction velocities across the carpal tunnel.<sup>1</sup> Electromyography reveals signs of denervation, such as fibrillations and positive sharp waves.

Conservative management of CTS begins with splinting, as multiple studies have shown improvement with both night splints and full-time splints.<sup>6</sup> Other studies have shown benefits from ultrasound treatments, yoga, and carpal bone mobilization.<sup>7</sup> Corticosteroid injections into the tunnel also provide symptomatic relief; 20% of patients remain symptom-free at one year. Steroid injections may also help make the diagnosis if it remains unclear, and can serve as a useful prognostic tool, as patients that experience no initial relief after injection may not experience symptomatic relief with surgery.<sup>1</sup>

Surgery is usually successful in treating CTS, with a 90% success rate.<sup>8</sup> All surgical techniques divide the transverse carpal ligament, release the volar border of the carpal tunnel,

**Figure 1.** Provocative testing in Carpal Tunnel Syndrome (a) Phalen's test, wrist hyperflexion; (b) Durkan's test, direct compression of the median nerve; (c) Tinel's sign, tapping over the course of the nerve elicits paresthesias



and decompress the nerve in the carpal tunnel. Endoscopic techniques have a faster recovery time and higher patient satisfaction within the first several weeks when compared to traditional open approaches, but these differences are undetectable at one year of follow-up.<sup>8</sup>

**Cubital Tunnel Syndrome**

Cubital tunnel syndrome (CuTS) is the second most common nerve compression syndrome, affecting roughly 25 out of every 100,000 people.<sup>9</sup> It is caused by compression of the ulnar nerve as it crosses the elbow. The cubital tunnel is formed by Osborne's ligament and the medial collateral ligament of the elbow, but the ulnar nerve passes through other structures around the elbow, each a potential site of nerve compression: the arcade of Struthers, the medial intermuscular septum, the medial head of the triceps, the anconeus epitrochlearis, the two heads of the flexor carpi ulnaris (FCU), and the proximal edge of the flexor digitorum superficialis.<sup>1</sup>

Patients present with numbness and paresthesias in the distribution of the ulnar nerve (the small finger and ulnar half of the ring finger); they also experience weakness of the intrinsic hand muscles (interossei, medial lumbricals), but rarely have pain.<sup>10</sup> Advanced disease is accompanied by atrophy and progressive weakness, giving rise to a host of eponymous hand deformities, including Duchenne's sign and Wartenburg's sign (Figure 2).<sup>11</sup>

As in carpal tunnel syndrome, the examination includes

many provocative maneuvers that reproduce the patient's symptoms. These include a Tinel's sign (tapping over the nerve at the elbow) and the elbow flexion test (in which the wrist is also extended, putting the ulnar nerve on maximum stretch).<sup>12</sup> Electrodiagnostic testing is less reliable in cubital tunnel syndrome, as the nerve compression is more intermittent than in carpal tunnel.<sup>13</sup>

Conservative treatment of CuTS consists of splinting the elbow in minimal flexion to take tension off the nerve, along with activity modification. Corticosteroid injections, nerve gliding, and ultrasound treatments are controversial.<sup>13</sup>

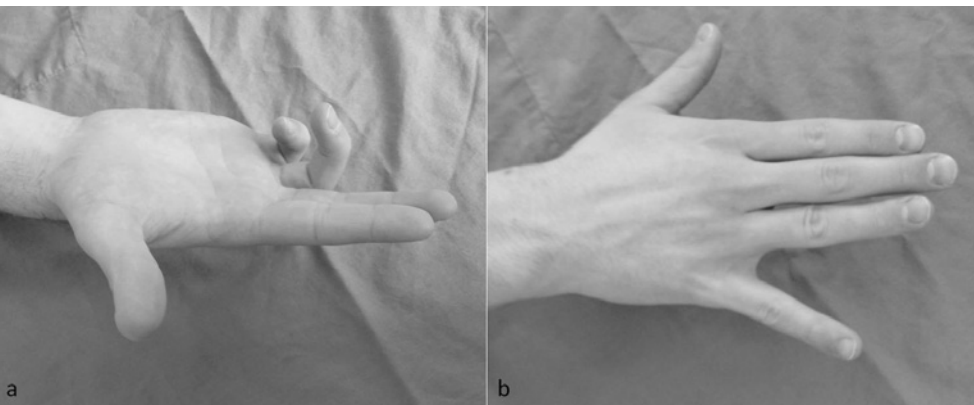
There are two surgical techniques used in the treatment of cubital tunnel syndrome. In situ decompression involves releasing the structures overlying the nerve, with the nerve left in place. With decompression and transposition, the ulnar nerve is moved anterior to the medial epicondyle. In theory, this leads to less stretching of the nerve during elbow flexion; however, studies have failed to show a significant difference in outcomes between the two techniques.<sup>14</sup>

**Posterior Interosseous Nerve Compression**

Radial Tunnel Syndrome (RTS) and Posterior Interosseous Syndrome (PIS) both refer to compression of the posterior interosseous nerve (PIN). The PIN branches from the radial nerve three to five centimeters distal to the lateral epicondyle; the nerve then dives under the arcade of Frohse (proximal edge of the supinator) and into the radial tunnel, consisting of the radiocapitellar capsule, supinator, and extensor carpi radialis brevis (ECRB). The vascular Leash of Henry, which is composed of branches of the recurrent radial artery, is yet another potential sites of compression of the PIN.<sup>1,15</sup> It is important to note that while the PIN does have afferent fibers that transmit pain signals from the wrist, it does not carry any cutaneous sensory information, which can help distinguish a PIN palsy from cervical radiculopathy.

RTS is a controversial diagnosis, with some doubting its very existence. It is typified by point tenderness over the mobile extensor wad, without motor or sensory symptoms, and without any findings on

**Figure 2.** Hand deformities resulting from ulnar nerve injury (a) Duchenne's sign, clawing of the two ulnar digits resulting from loss of interossei and ulnar lumbricals; (b) Wartenburg's sign, increased passive abduction of small finger



electrodiagnostic testing. Pain can sometime be elicited by resisted forearm supination or resisted middle finger extension, but these provocative tests are not well established.<sup>16</sup> The posterior interosseous syndrome (PIS), on the other hand, is a more conventional compression syndrome; it causes weakness in the distribution of the PIN and may yield abnormal electrodiagnostic findings.

Treatment for both syndromes is similar, beginning with splints, nonsteroidal drugs and activity modification; progressing to corticosteroid injections; and finally requiring surgical release of the proximal PIN for refractory cases. Patients with PIN syndrome tend to undergo surgical release earlier, partially because its motor symptoms lead to an easier diagnosis. Studies show generally good outcomes after release for PIN syndrome, with better outcomes for earlier releases.<sup>17</sup> Surgical release for RTS has poorer outcomes; much of this may be due to poor patient selection in view of the difficulty in making the diagnosis.<sup>18</sup>

### Rehabilitation

Occupational therapy plays an important role in the management of upper extremity nerve compression syndromes. Skillful hand therapy may help avoid surgery altogether. Conservative management includes activity modification as well as splinting the affected nerve. For patients who undergo surgical treatment, hand therapy is crucial in postoperative rehabilitation for appropriate return to normal function.

After surgery for any of the above syndromes, the basic principles of rehabilitation remain the same. Surgeries that involve any period of postoperative splint or sling immobilization of a joint (i.e, the elbow in cubital and radial tunnel releases) require therapy for range of motion. Many nerve compression syndromes have some element of weakness or atrophy preoperatively; therapy should therefore also focus on strengthening.<sup>19</sup>

Scar massage can help with collagen remodeling and with desensitization; similarly, nerve-gliding exercises are employed to prevent fibrotic adhesions from reforming around the released nerves.

### CONCLUSION

Nerve compression syndromes of the upper extremity are common afflictions. The diagnosis can usually be made with a careful history and physical examination, but supplemental diagnostic studies can be useful. Conservative treatment often suffices; for refractory cases, surgical release is usually definitive. Therapists play an important role both in initial management as well as postoperative rehabilitation.

### References

1. Brunton LM, Chhabra AB. Hand, Upper Extremity, and Microvascular Surgery. In: Miller M, Thompson SR, Hart JA, Cosker T, Elsayed S, eds. *Review of Orthopaedics*. Philadelphia, PA: Elsevier; 2012:517-587.
2. Osterman AL. The double crush syndrome. *Orthop Clin North Am*. Jan 1988;19(1):147-155.

3. Atroshi I, Englund M, Turkiewicz A, Tagil M, Petersson IF. Incidence of physician-diagnosed carpal tunnel syndrome in the general population. *Arch Intern Med*. May 23 2011;171(10):943-944.
4. Barcenilla A, March LM, Chen JS, Sambrook PN. Carpal tunnel syndrome and its relationship to occupation: a meta-analysis. *Rheumatology (Oxford)*. Feb 2012;51(2):250-261.
5. Nowak M, Noszczyk B. Simple clinical tests in severe carpal tunnel syndrome. *Pol Przegl Chir*. Dec 1 2012;84(10):502-508.
6. Muller M, Tsui D, Schnurr R, Biddulph-Deisroth L, Hard J, MacDermid JC. Effectiveness of hand therapy interventions in primary management of carpal tunnel syndrome: a systematic review. *J Hand Ther*. Apr-Jun 2004;17(2):210-228.
7. O'Connor D, Marshall S, Massy-Westropp N. Non-surgical treatment (other than steroid injection) for carpal tunnel syndrome. *Cochrane Database Syst Rev*. 2003(1):CD003219.
8. Trumble TE, Diao E, Abrams RA, Gilbert-Anderson MM. Single-portal endoscopic carpal tunnel release compared with open release : a prospective, randomized trial. *J Bone Joint Surg Am*. Jul 2002;84-A(7):1107-1115.
9. Mondelli M, Giannini F, Ballerini M, Ginanneschi F, Martorelli E. Incidence of ulnar neuropathy at the elbow in the province of Siena (Italy). *J Neurol Sci*. Jul 15 2005;234(1-2):5-10.
10. Huang JH, Samadani U, Zager EL. Ulnar nerve entrapment neuropathy at the elbow: simple decompression. *Neurosurgery*. Nov 2004;55(5):1150-1153.
11. Palmer BA, Hughes TB. Cubital tunnel syndrome. *J Hand Surg Am*. Jan 2010;35(1):153-163.
12. Buehler MJ, Thayer DT. The elbow flexion test. A clinical test for the cubital tunnel syndrome. *Clin Orthop Relat Res*. Aug 1988;233:213-216.
13. Lund AT, Amadio PC. Treatment of cubital tunnel syndrome: perspectives for the therapist. *J Hand Ther*. Apr-Jun 2006;19(2):170-178.
14. Caliandro P, La Torre G, Padua R, Giannini F, Padua L. Treatment for ulnar neuropathy at the elbow. *Cochrane Database Syst Rev*. 2012;7:CD006839.
15. Awantang MN, Sherrill JM, Thomson CJ, Hunt TR. Radial Nerve Decompression. In: Wiesel SW, ed. *Operative Techniques in Orthopaedic Surgery*. Vol 3. Philadelphia, PA: Lippincott, Williams, and Wilkins; 2011:2685-2690.
16. Naam NH, Nemani S. Radial tunnel syndrome. *Orthop Clin North Am*. Oct 2012;43(4):529-536.
17. Hashizume H, Nishida K, Nanba Y, Shigeyama Y, Inoue H, Morito Y. Non-traumatic paralysis of the posterior interosseous nerve. *J Bone Joint Surg Br*. Sep 1996;78(5):771-776.
18. Dang AC, Rodner CM. Unusual compression neuropathies of the forearm, part II: median nerve. *J Hand Surg Am*. Dec 2009;34(10):1915-1920.
19. Diao E. Carpal Tunnel Release: Endoscopic, Open, and Revision. In: Wiesel SW, ed. *Operative Techniques in Orthopaedic Surgery*. Vol 3. Philadelphia, PA: Lippincott, Williams, and Wilkins; 2011:2657-2665.

### Authors

P. Kaveh Mansuripur, MD; Matthew E. Deren, MD; Robin Kamal, MD, are affiliated with Rhode Island Hospital and the Department of Orthopaedics, Alpert Medical School of Brown University.

### Disclosures

The authors have no financial disclosures to report.

### Correspondence

P. Kaveh Mansuripur, MD  
Resident, Department of Orthopaedics,  
Rhode Island Hospital  
593 Eddy Street, Providence RI 02903  
401-444-4030  
Fax 401-444-6182  
pmansuripur@lifespan.org