

# Chapter 1 - The Neurologic Examination

HOME

AAN.COM

©2013 American Academy of  
Neurology - All Rights Reserved

FOR MORE INFORMATION

 [memberservices@aan.com](mailto:memberservices@aan.com)

OR

 (800) 870-1960 • (612) 928-6000

## Section 2

In this section the following systems will be reviewed in greater detail:

- Cranial Nerves
- Mental Status Examination
- Sensory System
- Extrapyramidal System
- Pyramidal System
- Cerebellum
- Peripheral Nervous System
- Individual Muscle Testing
- Evaluation of Speech and Language

## System Review

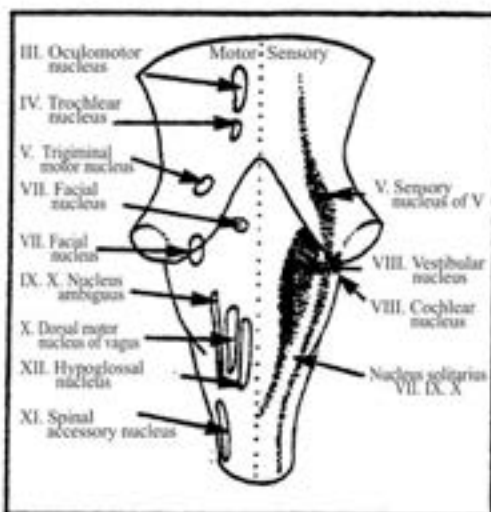
### Cranial Nerves

There are 12 cranial nerves; knowledge of the location and course of the cranial nerves is important in localizing lesions. (Figure 2.1)

Each of the cranial nerves will be reviewed individually for anatomy, tests of function, and potential pathology.

### Cranial Nerve I—Olfactory Nerve (Video)

The olfactory nerve passes through the cribriform plate of the ethmoid bone and synapses onto the olfactory bulb, which traverse posteriorly and terminate in the ipsilateral hippocampal gyrus, with complex connections with multiple nuclei of the limbic system.



**Figure 2-1:** Dorsal view of cranial nerve nuclei in the brainstem and upper cervical cord. Cranial nerve motor nuclei are on the left and sensory nuclei on the right.

To examine the olfactory nerve, the patient is asked to close his/her eyes while compressing each nostril separately. A tube containing a common substance with a strong odor, such as coffee, cinnamon or peppermint, is then placed below the nostril. The patient is asked if he can smell the substance and, if so, recognize it. The patient's ability to simply smell the substance eliminates **anosmia** (absence of smell).

The most common causes of anosmia are the common cold and allergic rhinitis. Tumors of the frontal lobe, such as meningioma, may compress the olfactory nerve or bulb and produce anosmia. Smell, like other sensations, may diminish with age. In the setting of head trauma the olfactory nerve is the

most commonly injured cranial nerve due to shearing injuries that may or may not be associated with fractures of the cribriform plate. If rhinorrhea occurs after head trauma, nasal drip should be checked for the presence of glucose with a Dextrostix? or urine test strip. A positive test for glucose suggests cribriform plate fracture with cerebrospinal fluid leak as discharge from nasal mucosa does not contain glucose.

### Cranial Nerve II—Optic nerve

(see Chapter on the **Visual System** for a separate discussion)

Cranial nerve II, the optic nerve, is composed of axons that originate in the ganglion cell layer of the retina. The optic disk of the fundus corresponds to the attachment of the optic nerve to the retina. The absence of rods and cones, the fundamental organs of sight, at the optic disk accounts for the blind spot in one's visual field. The optic nerve traverses posteriorly from the orbit through the optic foramen (which also contains the ophthalmic artery) and merges with the contralateral optic nerve to form the optic chiasm. A partial decussation of the optic nerves at the **optic chiasm** results in the formation of the **optic tracts**. Each tract contains axons from both retina, and project around the cerebral peduncles to synapse at the **lateral geniculate body**. Some fibers from the lateral geniculate body project to the midbrain to participate in the pupillary

light reflex. From the lateral geniculate body arise the **optic radiations** which hug the lateral ventricles as they traverse posteriorly and then medially to the **primary visual cortex** in the occipital lobe.

The optic nerve is a special sensory nerve that can be assessed by testing for visual acuity, visual fields, and funduscopic examination of the retina. Visual **acuity** reflects central vision or vision subserved by the **macula** where cones are in highest concentration. Monocular vision is tested by having the patient cover one eye, hold a pocket-sized Snellen chart at arm's length, and read the smallest numbers on the chart that can be read. Visual acuity is graded from 20/20 to 20/800. Corrective lens, if available, should be worn during testing. In the event that visual acuity is so severely impaired that a miniature Snellen chart is not useful, ask the patient to count fingers placed about 14 inches in front. Failing this, check for perception of movement, then light. Poor visual acuity may be associated with lesions involving the lens (cataracts), anterior optic chamber (glaucoma), retina (macular degeneration) or optic nerve (optic neuritis).



**Figure 2-2:** Examination of the patient's left eye visual fields by confrontation. The patient is asked to identify the number of fingers, which the examiner raises in each quadrant while centering his gaze on the examiner's right eye.

HOME

AAN.COM

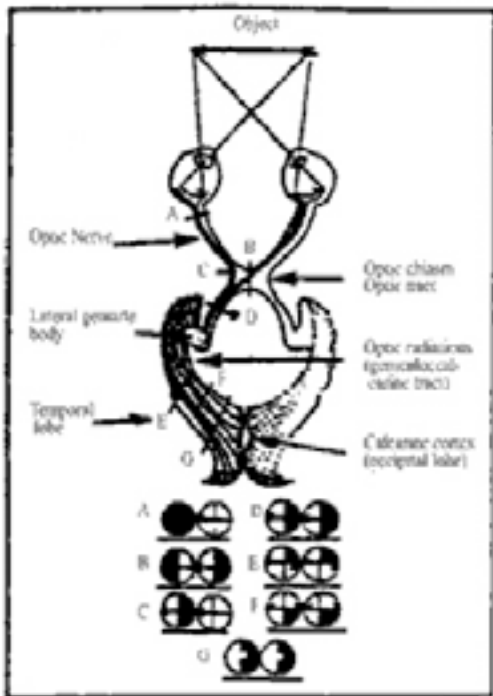
©2013 American Academy of  
Neurology - All Rights Reserved

FOR MORE INFORMATION

memberservices@aan.com

OR

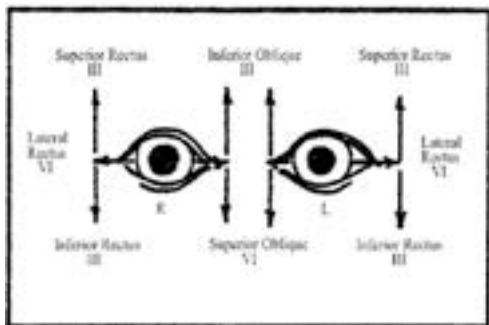
(800) 870-1960 • (612) 928-6000



**Figure 2-3:** Lesions of the optic nerve, optic chiasm, optic tract, optic radiations and primary visual cortex produce characteristic visual field deficits.

of a visual field (while cautiously avoiding movement of air that can result in a corneal blink reflex) and observing for a blink to threat.

Monocular visual field deficits are often due to lesions **anterior** to the optic chiasm, ipsilateral to the field cut as may be seen with **lens dislocation**, or **retinal infarction** from occlusion of the ophthalmic artery. **Homonymous visual field deficits** (toward the same side, e.g., left temporal, right nasal = left homonymous hemianopsia) imply a lesion **posterior** to the optic chiasm (**Figure 2-3**). The more **congruous**, (looks the same for each eye), the homonymous field cut; the more posterior the lesion is along the optic radiations. If **macular sparing**, or sparing of the center of vision, is detected with a homonymous hemianopsia, the lesion is most likely in the occipital lobe, as the macular area of the visual cortex is kept viable after a posterior cerebral artery infarct by terminal branches of the middle cerebral artery.



**Figure 2-4:** The action and nerve supply of the extraocular muscles is demonstrated.

Visual field testing assesses the integrity of the optic pathways as it comes from the retina, optic nerves, optic chiasm, optic tracts, and optic radiations to the primary visual cortex. It is most commonly performed by confrontation (**Figure 2-2**). The patient faces the examiner while covering one eye so that he fixates on the opposite eye of the examiner, directly in front of him.

Testing is performed by covering one of the patient's eyes and having the patient fixate on the examiner's nose. One to three fingers are then shown to the patient in each of the four visual quadrants of each uncovered eye and the patient asked to state the number of fingers seen. Lack of vision in quadrants can then be detected and mapped out to various types of field defect.

If the patient is uncooperative, visual field examination may be grossly tested by asserting a threatening hand to half

Funduscopy is performed with an ophthalmoscope. The patient is asked to fixate on an object in the distance while the examiner uses his right eye to examine the patient's right eye and the left eye for examination of the patient's left eye. Once the fundus is visualized, systematic examination of the optic disk, with attention to color and definition of disk margins, arterial supply, venous pulsations, and surrounding retina is conducted.

Swelling of the optic disk may be due to inflammation of the optic nerve, **optic neuritis**, or **papilledema**. These conditions may be difficult to differentiate based on

HOME

AAN.COM

©2013 American Academy of  
Neurology - All Rights Reserved

FOR MORE INFORMATION

memberservices@aan.com

OR

(800) 870-1960 • (612) 928-6000

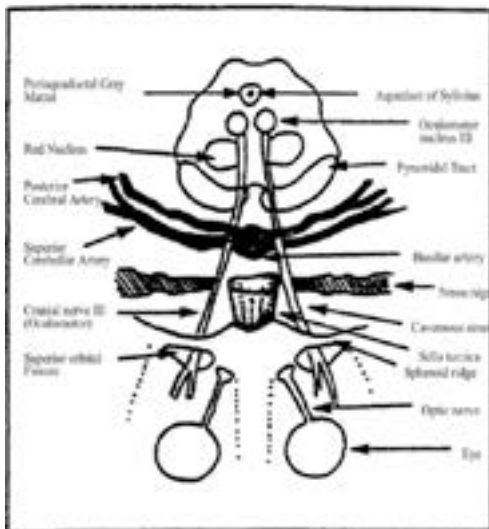


Figure 2-5

funduscopy alone. Typically, optic neuritis is associated with **decreased visual acuity** and an **enlarged blind spot**. **Optic pallor** implies optic atrophy from **retrobulbar neuritis**, as seen in multiple sclerosis, or ischemic optic neuropathy from small vessel infarction of the optic nerve secondary to long-standing hypertension. **Papilledema implies increased intracranial pressure**. Visual acuity is not affected unless there is secondary atrophy of the optic nerve. With papilledema, venous pulsations may be lost. Pallor of a segment of the fundus, associated with complaints of a “pie in the sky” loss of monocular vision, suggests branch central retinal artery occlusion secondary to embolic

or thrombotic occlusion of either the ciliary or ophthalmic arteries, both of which supply the optic nerve.

### Cranial Nerves III, IV, and VI—Oculomotor, Trochlear and Abducens Nerves (see Chapter on the Visual System)

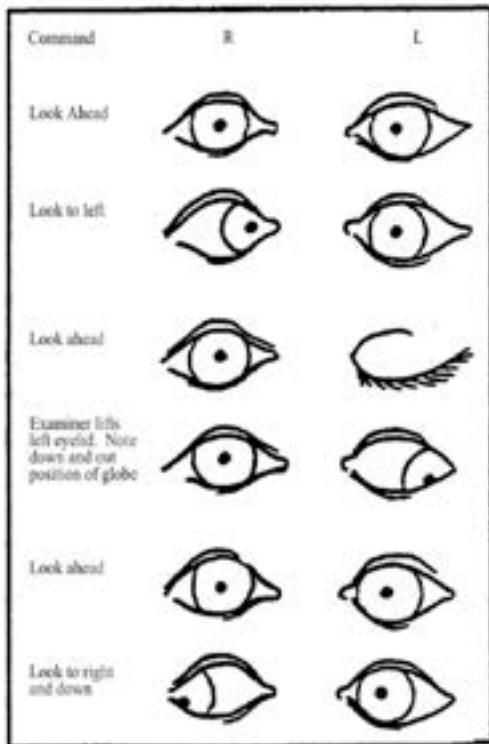


Figure 2-6: A complete left III nerve palsy is illustrated along with clinical presentations of left VI and IV nerve palsies.

The **oculomotor (III)**, **trochlear (IV)**, and **abducens (VI)**, nerves together innervate the extraocular muscles (Figure 2-4). The primary action of the **medial rectus** is adduction and that of the **lateral rectus** is abduction. The **superior rectus** and **inferior oblique** primarily elevate the eye while the **inferior rectus** and **superior oblique** primarily depress the eye.

The oculomotor nerve (cranial nerve III) also innervates the **levator palpebrae muscle**, which elevates the eyelid, the **pupillo-constrictor muscle**, which constricts the pupil, and the **ciliary muscle**, which controls the thickness of the lens, allowing for accommodation. The nuclear complex of the oculomotor nerve lies medially within the midbrain, ventral to the aqueduct of Sylvius (Figure 2-5). It consists of the oculomotor nucleus, which innervates the skeletal muscles of the eye and the Edinger-Westphal nucleus, which carries parasympathetic innervation to the pupil and ciliary muscle. The superior branch

of the oculomotor nerve supplies the superior rectus and levator of the upper lid while the inferior division innervates the medial rectus, inferior rectus, inferior oblique, pupilloconstrictor muscle and ciliary body.

HOME

AAN.COM

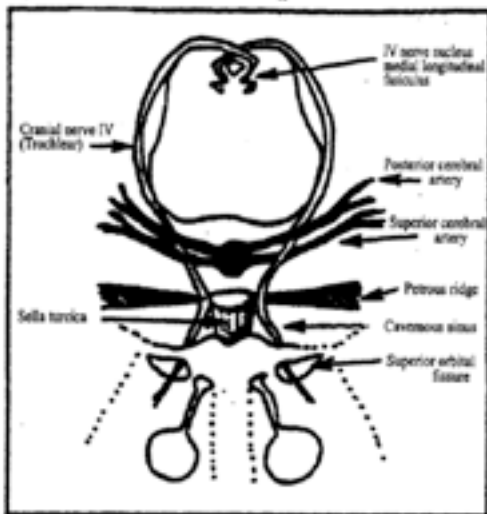
©2013 American Academy of  
Neurology - All Rights Reserved

FOR MORE INFORMATION

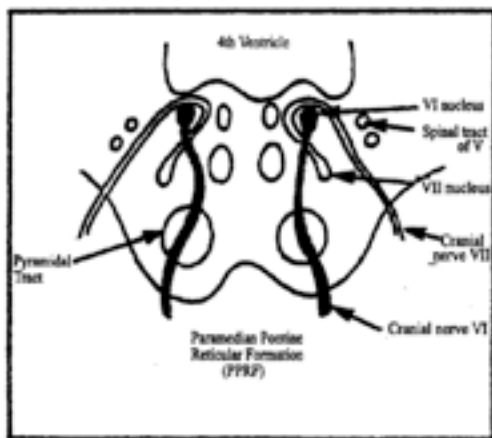
memberservices@aan.com

OR

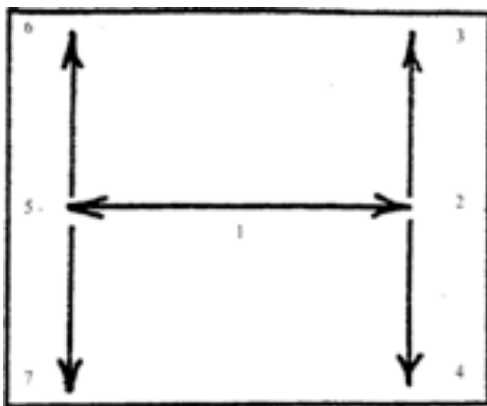
(800) 870-1960 • (612) 928-6000



**Figure 2-7:** The course of the trochlear nerve in the pons, across the posterior and superior cerebellar arteries, across the petrous ridge of the temporal bone, through the cavernous sinus, and out the superior orbital fissure is illustrated.



**Figure 2-8:** Note how the facial nerve wraps around the nucleus of cranial nerve VI within the pons.



**Figure 2-9:** The arrows and numbers indicate the sequence of eye movements tested in the six cardinal fields of gaze.

A complete oculomotor palsy will manifest as **ptosis, dilated and fixed pupil, and outward and slightly downward deviation of the eye.** (Figure 2-6). **Pupil-sparing,** isolated oculomotor nerve paresis is often due to ischemia from hypertension, diabetes, tertiary syphilis, or vasculitis, as the pupillomotor fibers travel along the periphery (outside) of the oculomotor nerve, closer to the blood supply of the nerve and are less susceptible to end-arteriole ischemia that tends to affect the center of the nerve. On the other hand, acquired third nerve palsies, which involve the pupil, may be due to compressive lesions such as aneurysm of the posterior communicating artery, head trauma, and tumors of the cerebral hemispheres compressing the oculomotor nerve and the parasympathetic fibers, which run peripherally within it.

The trochlear nerve (cranial nerve IV) nucleus lies in the medial midbrain, and wraps around the midbrain dorsally, alongside the cerebral peduncles, and courses between the posterior cerebral and superior cerebellar arteries (Figure 2-7). As the trochlear nerve has the longest intracranial distance of the cranial nerves, head trauma is the most common cause of nerve injury. A large proportion of fourth nerve palsies, however, are congenital and associated with a superior oblique that is shortened and tethered.

The abducens nerve (cranial nerve VI) nucleus lies in the caudal portion of the pons. The axons course ventrally through the pons and then travel in the middle of the cavernous sinus, through the superior orbital fissure and into the lateral rectus muscle, which it innervates. The facial nerve loops around the abducens nerve nucleus within the pons, therefore a pontine lesion in this location will produce ipsilateral paralysis of the lateral rectus and lower motor neuron facial nerve palsy (Figure 2-8).

Examination of the extraocular muscles is first conducted by examining the

HOME

AAN.COM

©2013 American Academy of  
Neurology - All Rights Reserved

FOR MORE INFORMATION

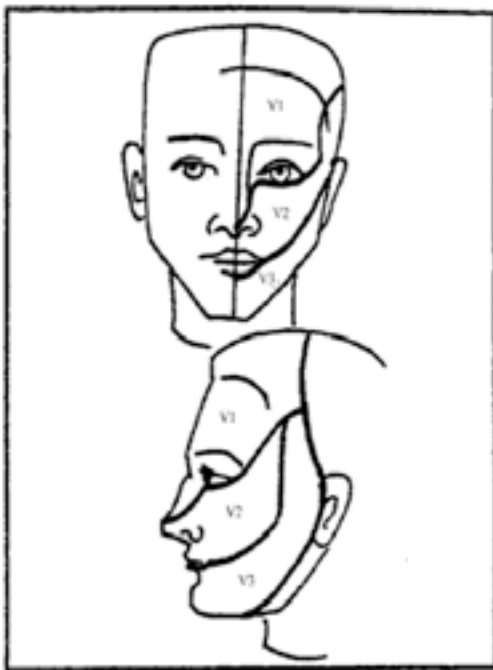memberservices@aan.com

OR

(800) 870-1960 • (612) 928-6000

alignment of the patient's eyes in the **primary position** (patient looking straight ahead). Shine a light into the patient's eyes and examine the corneal light reflection. If the light falls off center to a pupil, there is evidence of ocular malalignment, termed **exotropia** if the eye is laterally deviated, **esotropia** if the eye is medially deviated, **hypertropia** if the eye is deviated upwards and **hypotropia** if the eye is deviated downwards. Next, examine ocular motility by asking the patient to follow the examiner's finger as it is moved through the six cardinal fields of gaze (**Figure 2-9**). During conjugate eye movements the yoke muscles are equally stimulated so a lag in eye movement is a subtle sign of extraocular muscle weakness. Complaints of double vision by the patient will not always manifest as visible extraocular muscle weakness. Diplopia is worse in the direction of gaze of the weak muscle.

### Cranial Nerve V–Trigeminal Nerve (*Video*)



**Figure 2-10:** The subdivisions of cranial nerve V innervation to the face is illustrated.

The trigeminal nerve provides sensation to the face and mucous membranes of the nose, mouth, tongue and sinuses as well as motor innervation to the muscles of mastication.

The cell bodies of most sensory neurons innervating the face lie in the Gasserian ganglion and the rest are in the mesencephalic nucleus. There are three sensory divisions of the trigeminal nerve, all with their origin in the **Gasserian ganglion**: the **ophthalmic (V1)**, **maxillary (V2)** and **mandibular branches (V3)**.

The ophthalmic division innervates the conjunctiva, cornea, upper lid, forehead, bridge of the nose and upper scalp to the vertex (**Figure 2-10**). The maxillary branch innervates the cheek, lateral surface of the nose, upper teeth, jaw, and mucosal membranes of the nose and upper portion of the oropharynx.

The mandibular branch carries sensory

and motor neurons to the lower jaw, pinna of the ear, anterior portion of the external auditory meatus, ipsilateral tongue, lower teeth, and mucosal surface of the cheeks and floor of the mouth. The motor fibers innervate the temporalis, masseters and medial and lateral pterygoids.

Light touch is assessed by using a cotton wisp and gently touching the areas innervated by the three divisions of the trigeminal nerve while the patient's eyes are closed. The patient is asked to say, "touch" whenever he feels the cotton. To test pain sensation, repeat the above maneuver with the sharp and round end of a safety pin, asking the patient to discriminate between "sharp" and "dull." Temperature sensation can be tested by filling two test tubes individually with cold and warm water, applying the test tubes to the three divisions of the trigeminal nerve and asking the patient to differentiate cold from warm.

The corneal blink reflex tests the integrity of the ophthalmic division of V, which innervates the cornea and constitutes the sensory component of the reflex, and

HOME

AAN.COM

©2013 American Academy of  
Neurology - All Rights Reserved

FOR MORE INFORMATION

memberservices@aan.com

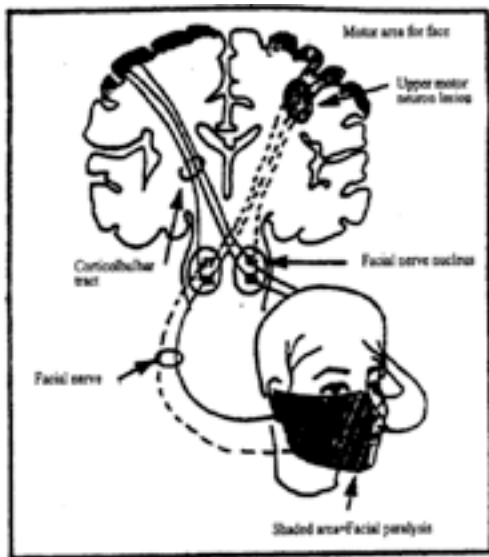
OR

(800) 870-1960 • (612) 928-6000

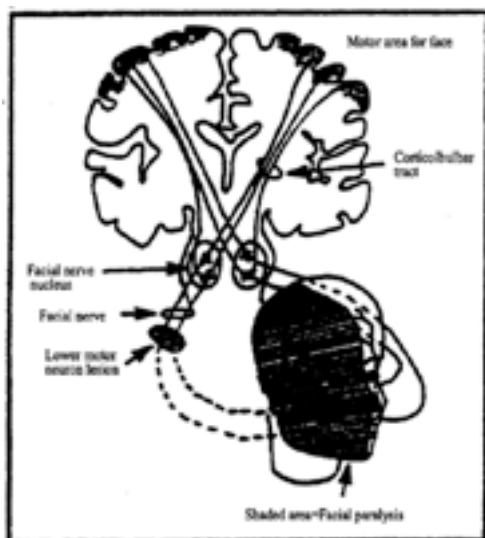
the facial nerve, which constitutes the motor arc of the reflex by innervating the orbicularis oculi and allowing closure of the eyelid. To test the reflex, the end of a cotton Q-tip is twisted into a point. The patient is asked to look laterally and the cotton point applied gently onto the cornea from the direction contralateral to the gaze so as to avoid reflex defensive blinking. In patients who are comatose, the presence of a corneal blink reflex implies that the sensory nucleus of V and the facial nerve nucleus, both in the pons, are intact. .

### Cranial Nerve VII–Facial Nerve (Video)

The facial nerve, cranial nerve VII, innervates all the muscles of facial expression, i.e., the muscles around the eyes, mouth, nose, ears and neck. It also innervates the stapedius muscle in the ear, which dampens excessive movement of the ossicles when subject to loud sounds. The facial nerve subserves taste to the anterior two thirds of the tongue and sensation to the outer ear.



**Figure 2-11:** A right upper motor neuron VII lesion due to a left subcortical stroke is illustrated.



**Figure 2-12:** A lower motor neuron VII lesion due to a left peripheral facial nerve palsy is illustrated.

The motor nucleus of VII sits in the pons while its axons loop around the nucleus of the abducens nerve and emerges from the pontomedullary junction. The facial nerve then courses through the internal auditory meatus where it is joined by the auditory nerve, and enters the facial canal of the temporal bone. Distal to the geniculate ganglion, the facial nerve gives off the chorda tympani, which supplies taste to the anterior two thirds of the tongue via the lingual nerve. The facial nerve exits the facial canal through the stylomastoid foramen, passing through the parotid gland, before innervating the muscles of the face and the platysma.

To test the facial nerve, first observe the patient's face for symmetry by paying close attention to the nasolabial folds, forehead wrinkles, spontaneous smiling and blinking. Then, ask the patient to show his teeth, raise his eyebrows, squeeze his eyes shut tightly and hold air in his cheeks. Facial weakness may be due to upper motor neuron or lower motor neuron facial palsy. Upper motor neuron palsy implies that there is a lesion contralateral to the side of facial weakness which is disrupting the face motor fibers somewhere in its course from the primary motor cortex to the facial nucleus within the pons (i.e., upper motor neuron to the facial nerve nucleus, **Figure 2-11**). A typical presentation of an upper motor neuron palsy is a patient with a right subcortical

HOME

AAN.COM

©2013 American Academy of  
Neurology - All Rights Reserved

FOR MORE INFORMATION

memberservices@aan.com

OR

(800) 870-1960 • (612) 928-6000

lacunar infarct resulting in flattened left nasolabial fold, decreased up turning of the left corner of the mouth on smiling, and symmetric wrinkling of forehead bilaterally, in addition to a left hemiparesis. Lower motor neuron palsy implies a lesion involving the facial nerve at the nucleus in the pons or along the course of the facial nerve ipsilateral to the side of facial weakness (**Figure 2-12**). Bell's palsy is a lower motor neuron facial palsy whereby the patient has unilateral flattening of the nasolabial fold with inability to upturn the corner of the mouth upon smiling, inability to wrinkle his forehead, delayed or absent blinking due to weakness of the eyelid, and inability to hold air in the cheeks due to escape of air through the corner of the mouth which is weak. In addition, patients with Bell's palsy may complain of dry eye from disruption of parasympathetic innervation of the lacrimal gland, hyperacusis or augmented hearing in the ear ipsilateral to the lesion from paralysis of the stapedius muscle and diminished taste from a lesion proximal to the lingual nerve, which inhibits afferent signals concerning taste from reaching the brainstem.

**In summary upper motor neuron facial weakness spares the frontalis (forehead muscle) so the patient can wrinkle his brow. Lower motor neuron facial weakness involves the forehead muscle and the patient can't wrinkle the brow and in addition has unilateral hyperacusis and loss of taste.**

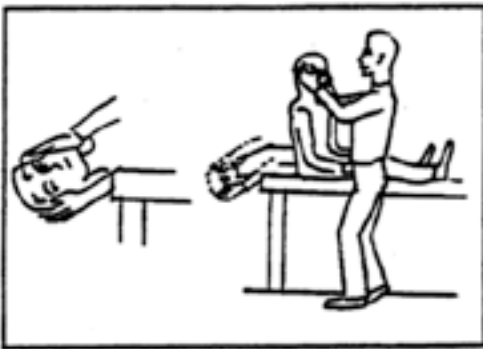
**Facial diplegia**, or bilateral lower motor neuron facial weakness, is seen in such conditions as Guillain-Barré syndrome or sarcoidosis.

### Cranial Nerve VIII—Acoustic Nerve (*Video*)

The auditory nerve, cranial nerve VIII, is composed of two divisions, the cochlear nerve, which subserves hearing, and the **vestibular** nerve, which provides sense of balance. The cochlear nerve sits in the lower pons, near the cerebellopontine angle. Lesions of the cochlear nerve commonly present with ipsilateral decreased hearing and sometimes tinnitus. The vestibular nerve is composed of nerve fibers from the labyrinth of the inner ear, which travel alongside the cochlear nerve to terminate on the vestibular nuclei within the lower pons.

To test the auditory nerve, first check gross hearing in each ear by rubbing your fingers about 30 inches from the patient's ear, with the contralateral ear covered. If hearing in one ear is impaired, perform Rinne and Weber tests. Both tests

employ the use of a 256 Hz tuning fork. In the **Rinne** test, the vibrating tuning fork is placed over the mastoid process, behind the ear to test bone conduction (BC). Ask the patient to tell you when he no longer hears the vibrating fork, after which the tuning fork is placed in front of the ear and the patient asked if he can hear it (air conduction = AC). Next perform the **Weber** test by placing a vibrating tuning fork over the middle of the forehead and ask the patient if the sound is louder in one ear compared to the other. With conductive hearing loss, from middle ear disease or obstruction of the external auditory meatus with wax, BC will be greater than AC and Weber



**Figure 2-13:** The Hallpike maneuver is illustrated. The patient initially is seated upright and asked to fall backwards, so that his head is below the plane of his trunk. The examiner then turns his head to one side and asks the patient to look in the direction to which his head is turned.

HOME

AAN.COM

©2013 American Academy of  
Neurology - All Rights Reserved

FOR MORE INFORMATION

 [memberservices@aan.com](mailto:memberservices@aan.com)

OR

 (800) 870-1960 • (612) 928-6000



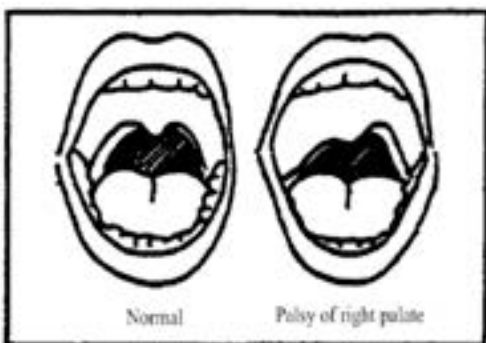
test will lateralize to the deaf ear. However, with sensorineural hearing loss AC is better than BC and Weber test will lateralize to the good ear.

Vestibular nerve function can be tested with postural maneuvers. In patients suspected of benign positional vertigo, presenting with vertigo or dizziness associated with changes in head position, the Hallpike maneuver should be attempted when not contraindicated due to severe cervical spine disease. To perform the Hallpike maneuver, the patient sits up in bed and then quickly lies back on command so that his head hangs over the edge of the bed. The head is tilted backward below the plane of his body and turned to one side by the examiner who holds the patient's head in his hands. The patient is asked to look in the direction that his head is turned (**Figure 2-13**). Watch for nystagmus in the direction of gaze and ask the patient if he feels vertigo. If no nystagmus is observed after 15 seconds, have the patient sit up and repeat the maneuver turning the patient's head and directing his gaze in the contralateral direction. The absence of nystagmus suggests normal vestibular nerve function. However, with peripheral vestibular nerve dysfunction, such as benign positional vertigo, the patient will complain of vertigo, and rotary nystagmus will appear after a 1- to 5-second latency toward the direction in which the eyes are deviated. With repeated maneuvers, the nystagmus and sensation of vertigo will **fatigue** and disappear, a sign of peripheral vestibular disease, in contrast to central vestibular disease from stroke or other intrinsic brainstem lesions, which manifests as **nonfatigable nystagmus** without delay in onset.

### Cranial Nerves IX and X—The Glossopharyngeal and Vagus Nerves (*Video*)

The glossopharyngeal nerve (cranial nerve IX) contains sensory and motor fibers as well as autonomic innervation to the parotid glands. It mediates taste to the posterior one third of the tongue and sensation to the pharynx and middle ear.

Like the glossopharyngeal nerve, the vagus nerve (cranial nerve X) contains sensory, motor and autonomic fibers. Motor innervation to the muscles of the soft palate, pharynx and larynx originates in the medulla. Autonomic fibers arise from the dorsal motor nucleus of vagus and synapse at peripheral ganglia to provide parasympathetic innervation to the trachea, esophagus, heart, stomach, and small intestine.



**Figure 2-14:** A normal soft palate is illustrated on the left. On the right, a right palatal palsy from a lower motor neuron X nerve lesion has resulted in deviation of the uvula to the left.

To test glossopharyngeal and vagus nerve function, examine the position of the uvula and its movement by asking the patient to say "Ah." the soft palate should elevate symmetrically and the uvula should remain in the midline. The gag reflex can be tested by touching the pharyngeal wall on each side with a cotton tip applicator. This reflex relies on an intact sensory arc, as mediated by sensory fibers of the glossopharyngeal nerve to the soft palate, and an intact motor arc, as mediated by the motor fibers of the vagus nerve to the soft palate

and pharynx. Deviation of the uvula to one side implies a lower motor lesion of the vagus nerve **contralateral** to the side the uvula is deviating to (**Figure 2-14**).

HOME

AAN.COM

©2013 American Academy of  
Neurology - All Rights Reserved

FOR MORE INFORMATION

 [memberservices@aan.com](mailto:memberservices@aan.com)

OR

 (800) 870-1960 • (612) 928-6000

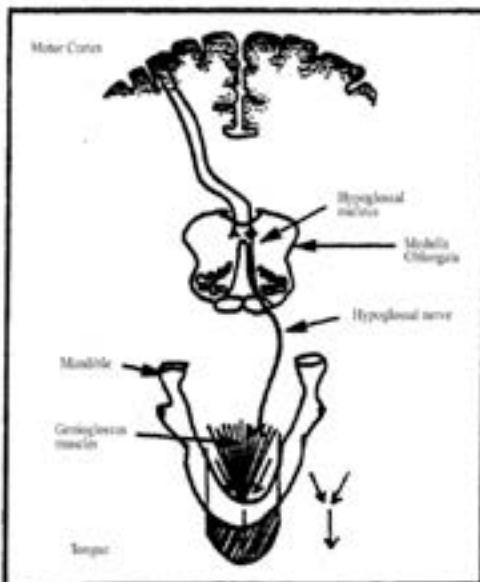
An upper motor neuron vagus nerve lesion will present with the uvula deviating toward the side of the lesion. The presence of a gag reflex does not necessarily imply that the patient can swallow without aspiration after a stroke. Impairment of swallowing is usually due to bilateral vagus nerve lesions. On the other hand, the absence of a gag reflex does not imply inability to swallow. Hoarseness may be seen with tumors encroaching on the recurrent laryngeal nerve, a branch of the vagus nerve. This results in unilateral vocal cord paralysis.

### Cranial Nerve XI—The Accessory Nerve (Video)

The spinal accessory nerve, cranial nerve XI, innervates the sternocleidomastoid and trapezius muscles.

To test the strength of the sternocleidomastoids ask the patient to turn his head against your hand, which is placed over the mandible. Repeat this maneuver with your hand on the contralateral mandible. Observe the sternocleidomastoid, which is contralateral to the side to which the patient is turning his head. Weakness detected when the patient turns his head to the left implies that the right sternocleidomastoid is weak. To test the trapezius, ask the patient to shrug his shoulders and press down on the shoulders. Trapezius weakness is manifest as difficulty in elevating the shoulders. When the sternocleidomastoid and trapezius are weak on the same side, an ipsilateral peripheral accessory palsy, involving cranial nerves X and XI, is implied as may be seen with a jugular foramen tumor, i.e., glomus tumor or neurofibroma. Because the cerebral hemisphere innervates the contralateral trapezius and ipsilateral sternocleidomastoid, a large right hemisphere stroke will result in weakness of the left trapezius and right sternocleidomastoid. Bilateral wasting of the sternocleidomastoid may be seen with myopathic conditions such as myotonic dystrophy and polymyositis or motor neuron disease, the latter usually associated with fasciculations.

### Cranial Nerve XII—Hypoglossal Nerve (Video)



**Figure 2-15:** The opposing action of the two halves of the tongue is illustrated. Note that the tongue, like most muscles in the body derives supranuclear innervation from the contralateral motor cortex.

The hypoglossal nerve, cranial nerve XII, is a pure motor nerve, innervating the muscles of the tongue.

To test the function of the hypoglossal nerve, ask the patient to protrude his tongue and wiggle it from side to side. Look for deviation and atrophy. To check for subtle weakness, ask the patient to push his tongue against the wall of his cheek while you push against it through the outer cheek. Like the forehead, each side of the tongue receives upper motor neuron innervation from bilateral motor cortices. Each half of the tongue pushes the tongue in the contralateral direction, i.e., left half of tongue pushes to the right (**Figure 2-15**). Thus, if the tongue deviates to one side, **it is pointing to the side that is weak**. Tongue deviation, combined with wasting on the side to which it is deviated, implies a unilateral,

HOME

AAN.COM

©2013 American Academy of  
Neurology - All Rights Reserved

FOR MORE INFORMATION

memberservices@aan.com

OR

(800) 870-1960 • (612) 928-6000

lower motor neuron, hypoglossal nucleus or nerve lesion as may be seen with syringobulbia (a degenerative cavity within the brainstem), with basilar meningitis, or foramen magnum tumor. If the tongue deviates and is of normal bulk, one should consider an upper motor neuron lesion, such as stroke or tumor in the hemisphere contralateral to the side of deviation, and look for associated hemiparesis on the side of tongue deviation.

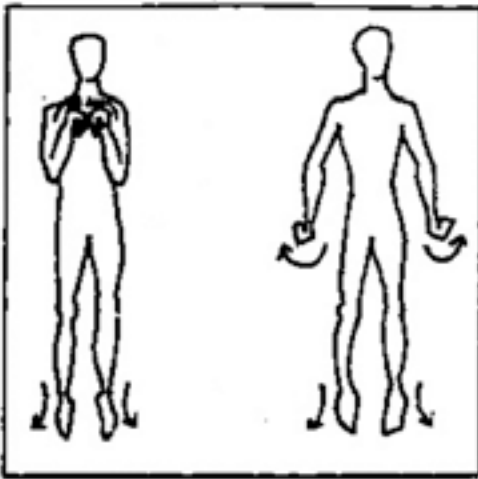
## The Mental Status Examination

As previously noted, the neurologic exam begins with an assessment of the patient's mental status. In most cases, a large part of the mental status exam may be ascertained from observation of the patient as history is provided. A more detailed mental status exam can be divided into the following components:

- Level of consciousness
- Intellectual performance
- Language

### Level of Consciousness

Level of consciousness implies awareness of surroundings. If one is examining a patient who is somnolent or comatose, it is important to determine the degree of stimulation that is required to alert the patient, i.e., voice, light touch, sternal rub.



**Figure 2-16:** Decorticate posturing is illustrated on the left. Decerebrate posturing is on the right.

**Motor system.** In evaluating the motor system, look for lateralizing signs such as asymmetry of movement either spontaneously or to painful stimulation and asymmetric reflexes. Describe any spontaneous posturing. **Decorticate posturing** is characterized by tonic flexion of the arms and extension of the legs and implies a lesion at the level of the midbrain (**Figure 2-16**). **Decerebrate posturing** is manifest as tonic adduction and extension of the arms and legs and suggests a lesion at the level of the pons. In general, metabolic disturbances do not result in posturing, although anoxia and hypoglycemia can produce posturing. A mass lesion, which

previously produced lateralized signs, may result in decorticate or decerebrate posturing when it expands and compresses the brainstem.

**Pupils and fundi.** Papilledema suggests increased intracranial pressure from a mass lesion or cerebral edema. Check the pupils for size and reactivity to direct light. With metabolic disease the pupils tend to be small and sluggishly reactive. Asymmetry of pupil size and reactivity, particularly the unilateral dilated pupil, suggests mass effect with herniation. **Thalamic** lesions usually produce a 2 mm nonreactive pupils, 4-5 mm fixed pupils suggest a **midbrain lesion** and pinpoint pupils suggest **pontine dysfunction**. **Any nonmetabolic sign requires emergent CT scan for evaluation of possible mass lesion.**

**Ocular movement.** Eye movements should be intact with metabolic disease,

HOME

AAN.COM

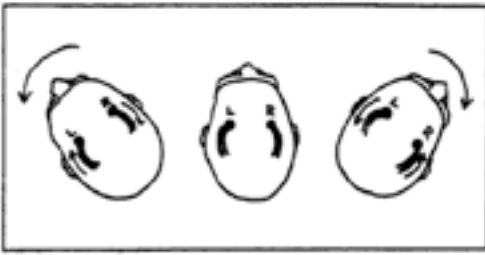©2013 American Academy of  
Neurology - All Rights Reserved

FOR MORE INFORMATION


 [memberservices@aan.com](mailto:memberservices@aan.com)

OR

 (800) 870-1960 • (612) 928-6000



**Figure 2-17:** The Doll's eye maneuver is illustrated. With an intact brainstem, the eyes conjugately deviate in the opposite direction of head turning.



**Figure 2-18:** Cold caloric testing and appropriate responses when the brainstem is intact (top) and when a pontine lesion is present (bottom) is demonstrated.

as noted with spontaneous movement or with **Doll's eye maneuver**. Doll's eye maneuver should be performed once severe cervical spine disease or fracture has been ruled out (**Figure 2-17**). The patient's head is moved swiftly from side to side, with the eyes held open. An intact Doll's eye reflex is characterized by the eyes moving conjugately in the direction opposite to which the head is being turned, i.e., head turn to the left should swing both eyes across the midline to the right. This maneuver checks the integrity of the brainstem between the midbrain and pons. If the Doll's eye maneuver does not produce eye movements, cold caloric testing is necessary (**Figure 2-18**). The head of the bed is raised by 30 degrees. Examination of the tympanic membranes for perforation should be ruled out before cold water is injected into each ear. If the brainstem is intact, injection of cold water into the ear should elicit tonic conjugate deviation of the eyes toward the side of injection. Nystagmus away from the side injected may or may not be present, but is not necessary to assess the integrity of the brainstem. Inability to produce the full range of eye movements with either the Doll's eye maneuver or cold calorics suggests brainstem pathology from pressure on the brainstem (herniation from a subdural hematoma) or from direct brainstem injury (basilar artery stroke).

The unilateral third nerve palsy, manifest as a fixed, dilated pupil in an eye that is "down and out" in position, is the classic example of a hemisphere lesion

producing brainstem signs of oculomotor and pupillary dysfunction. A mass in one hemisphere causes the uncus of the temporal lobe to herniate over the edge of the tentorium, where it impinges on the third nerve. Compression of the parasympathetic fibers on the outer portion of the nerve results in ipsilateral pupillary dilation and is an early sign of the uncal herniation syndrome.

**Respiratory patterns.** The respiratory pattern of metabolic disease characteristically produces Cheyne-Stokes respirations however; early mass lesions may also produce Cheyne-Stokes respirations. Central neurogenic hyperventilation, which is manifest as rapid shallow breathing, indicates midbrain dysfunction. Cluster or apneustic breathing suggests pontine injury. Ataxic, shallow breathing is characteristic of agonal respirations from medullary lesion.

HOME

AAN.COM

©2013 American Academy of  
Neurology - All Rights Reserved

FOR MORE INFORMATION

 [memberservices@aan.com](mailto:memberservices@aan.com)

OR

 (800) 870-1960 • (612) 928-6000

In the patient who is somnolent but arousable to stimulation, or confused, the etiology is most likely metabolic or toxic causes unless there are focal neurologic signs to suggest a structural lesion.

### Intellectual Performance

Intellectual performance provides the best evidence of organic brain damage and its extent. Diffuse involvement of the brain results in deterioration of general intellectual functions while a structural lesion results in impairment of specific intellectual functions. Difficulties with **maintaining attention** and **perseveration** of thought manifest as slowness to shift from one topic to another. These, and **poor memory** are examples of specific intellectual deficits which should lead the examiner to more specific testing of memory, calculations, and judgment.



Memory depends on the ability to store and retrieve information both on a short and long-term basis. It is critical for learning. When evaluating memory function, it is important to realize that inattention, decreased motivation, and poor cooperation, all symptoms of depression, can appear to impair memory. However, in depression, memory deficits may be overcome by improving the patient's cooperation and concentration, while organic deficits in memory are not altered with increased effort.

Formation of long-term memory requires both intact sensory store, short-term memory and the consolidation of short-term memory into long-term memory. Most clinical memory deficits involve transfer of information from short term to long-term memory. This deficit is referred to as **anterograde amnesia** or the inability to form new long-term memory and is classically seen in **Korsakoff's psychosis** from thiamine deficiency. Once information has been stored in long-term memory it can decay if not rehearsed. Long-term memory is the last memory to be lost in organic disease, with the most remote events, i.e., childhood, retained the longest. This phenomenon is observed in Alzheimer's dementia. The loss of remote memory is referred to as **retrograde amnesia** and is always accompanied with severe anterograde amnesia. A classic cause of this condition is head trauma with the memory deficit proportional to the severity of the blow.

To test memory, check digit span to make sure attention capacity is intact. The patient is asked to repeat a gradually increasing sequence of numbers, e.g., 2-3-7-4, 5-8-4-6-1, 2-0-5-1-6-9, etc. The normal patient should be able to repeat at least 7 digits. Present the patient with three words (baseball, tree, car) and three complex shapes that are drawn for the patient. Have the patient recall the words and shapes after five minutes. This procedure checks short-term to long-term memory transfer and is an effective screen for anterograde amnesia. Ask the patient about the remote and recent past to check for retrograde amnesia.

### References

1. Strub RL and Black FW. The Mental Status Examination, 4<sup>th</sup> Edition. FA Davis Co., Philadelphia, 2000.
2. Massey EW, Pleet AB, and Scherokman BJ. Diagnostic Tests in Neurology: Photographic Guide to Bedside Techniques. Chicago: Year Book Medical Publishers, 1985.
3. Bajandas FJ and Kline LB. Neuro-Ophthalmology Review Manual, 3<sup>rd</sup> Edition. Thorofare, NJ: SLACK Inc., 1988.
4. Mayo Clinic and Mayo Foundation: Clinical Examination in Neurology. St. Louis: Mosby Year Book, Inc., 1998.
5. DeMyer W. Technique of the Neurologic Examination: A Programmed Text. 4<sup>th</sup> Edition. New York: McGraw Hill, Inc., 1994.



6. Fuller G. Neurological Examination Made Easy. 2<sup>nd</sup> Edition. Edinburgh: Churchill Livingstone, 1999.
7. Plum F and Posner JB. The Diagnosis of Stupor and Coma. 3<sup>rd</sup> Edition. Philadelphia: FA Davis Co., 1980.

## The Sensory System

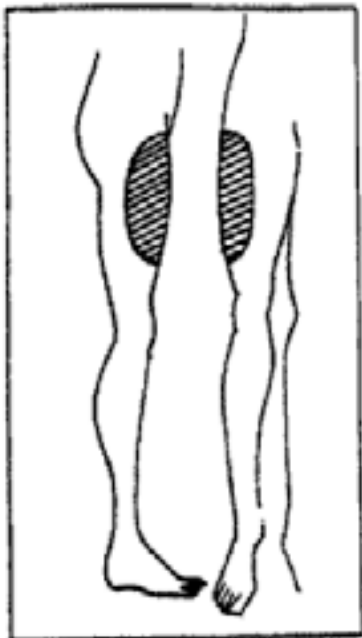
### (Video)

Performing this part of the examination may be time consuming because of misunderstanding or lack of patient cooperation. With some experience and practice, useful information can be obtained. If the patient has no sensory symptoms a routine sensory examination is usually performed. If, however, the patient has sensory symptoms, an examination tailored to the symptoms is performed in addition to the usual survey.

We will first go over some basic neuroanatomic pathways so that abnormal findings on the examination can be translated into useful clinical information.

The sensory modalities usually tested are **superficial sensation** and **deep sensation**. Superficial sensation encompasses light touch, pain and temperature sensibility. Deep sensation includes joint and vibratory sensibility and pain from deep muscle and ligamentous structures.

Sensory stimuli are picked up at their origin by specialized **receptors** whose unique firing patterns enable the brain to identify different types of stimuli. The information is relayed upwards to its ultimate destination, the **primary sensory cortex** of the parietal lobe (post-central gyrus). Here, sensory information is integrated into meaning (e.g., feeling an object and being able to identify it, or experiencing pain and then undergoing suffering and anguish as a result of it). All sensory modality fibers are grouped together in peripheral nerves but once they reach the spinal cord, they split and travel to their ultimate destination over different routes. It is awareness of these pathways and how they are distributed at different levels of the neuraxis that enables the examiner to localize the level of a lesion based on the clinical findings of the sensory examination.



**Figure 2-19:** Lateral femoral cutaneous nerve sensory loss.

**Peripheral nerve lesions** can produce sensory deficits, motor deficits, autonomic dysfunction, or all of these. The sensory loss characteristically has **sharp borders** and if it is a **mixed nerve** for example, the median nerve, sensory, motor and autonomic fibers are affected. **Sensory nerves** have no motor fibers and lesions produce sensory loss for all modalities. Partial lesions may produce a disquieting burning or lancinating pain as well. An example of this type of nerve is the lateral femoral cutaneous nerve supplying the skin of the lateral thigh (**Figure 2-19**). Examples of findings secondary to common peripheral nerve lesions are found at the end of this chapter.

The peripheral nerve cell body is located in the dorsal root ganglion near the spinal cord. As the specific central processes of these cells enter the spinal cord (**Figure 2-19A**) they either synapse and cross in one or two segments to enter the spinothalamic tract (pain and temperature), or

HOME

AAN.COM

©2013 American Academy of  
Neurology - All Rights Reserved

FOR MORE INFORMATION

 [memberservices@aan.com](mailto:memberservices@aan.com)

OR

 (800) 870-1960 • (612) 928-6000

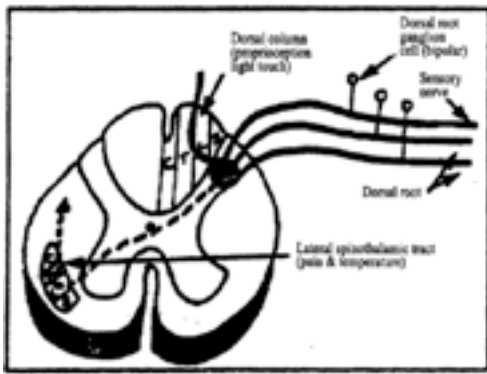


Figure 2-19A: Spinal cord sensory pathways.

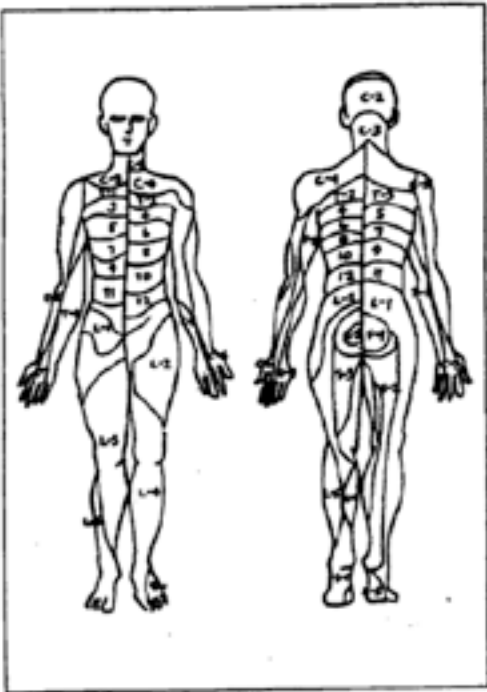


Figure 2-20: Dermatome map of spinal sensory nerve roots.

remain ipsilateral and travel upwards in the dorsal columns or lateral spinothalamic tracts (proprioception, joint receptor sensation). The dorsal columns convey information that will ultimately reach consciousness and the spinothalamic tracts send sensory information to the cerebellum for its use in coordinating motor activity.

If a patient has a lesion involving the nerve root itself there will be sensory and motor loss characterized by the nerve fibers present in the root. Root sensory distribution follows a **dermatomal distribution**. A dermatome map is shown in **Figure 2-20**.

Points to remember about root lesions are the following:

- Most frequent in the cervical and lumbo-sacral regions.
- Associated with pain.
- Commonly caused by intervertebral disc herniations and spondylosis.
- Can also occur secondary to metastatic disease, metabolic or inflammatory/infectious disorders.
- Sensory loss found on exam is not always dramatic because of overlap of sensation with the roots above and below.
- Muscle weakness is characteristic for the root in question.

Once the sensory fibers enter the spinal cord they begin their upward ascent. Pain and temperature fibers travel upwards on the **side opposite** to their origin in the **lateral spinothalamic tract** (**Figure 2-21**). Fibers for facial pain and temperature sensation originate in the Gasserian ganglion and then travel downward in the **descending root of V** before they cross over to join the contralateral spinothalamic tract. As a result of this unusual arrangement the lateral medulla is characterized by having ipsilateral facial and contralateral body pain and temperature fibers on the same side. For example, a unilateral lesion in the lateral medulla (**Wallenberg syndrome**) demonstrates loss of pain and temperature on the **ipsilateral** side of the **face**, and **contralateral** side of the **body**.

Proprioceptive fibers and touch fibers travel in the dorsal columns ipsilateral to the side of their origin until they reach the lower medulla; then the fibers cross to the opposite side and travel up to the thalamus where they are joined by facial sensory fibers from the opposite trigeminal sensory nucleus. After synapsing in

HOME

AAN.COM

©2013 American Academy of  
Neurology - All Rights Reserved

FOR MORE INFORMATION

[memberservices@aan.com](mailto:memberservices@aan.com)

OR

(800) 870-1960 • (612) 928-6000

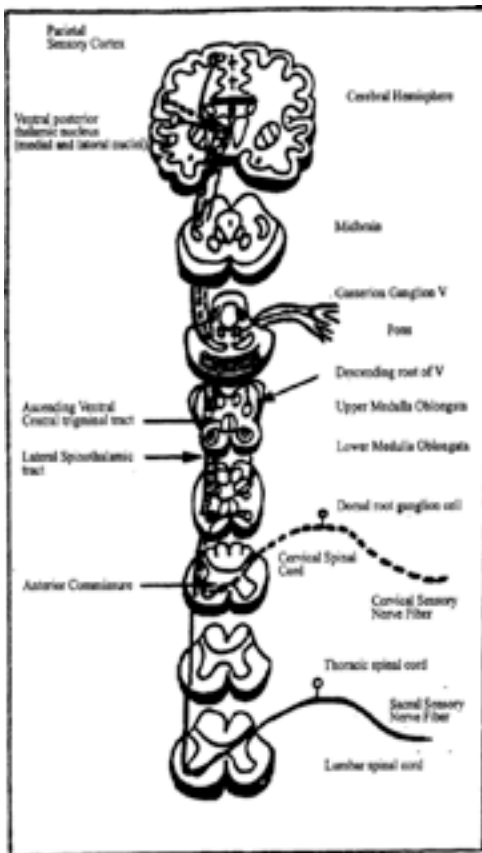


Figure 2-21: Spinothalamic tract (Pain and temperature pathway).




Figure 2-22: Topographic relationship for sensation on the post central gyrus (parietal lobe). Similar topographic representation is present for motor control on the precentral gyrus (frontal lobe).

the thalamus the fibers project to the primary sensory cortex of the parietal lobe where all sensory modalities are processed and interpreted.

Some light touch fibers travel in the anterior spinothalamic tract (Figure 2-23) and some vibratory fibers travel in the lateral columns. For this reason there may be sparing of some light touch and vibration sensation with dorsal column lesions.

### The Sensory Examination

The patient should be in a comfortable position and undressed except for a gown. Exposure of the feet, abdomen and trunk as well as the perineum is necessary to perform an adequate sensory examination.

### Primary Modalities to be Tested

- **Light touch**

Test item: Cotton wisp. Touch patient lightly with eyes closed and have them say “yes” when touched. Compare sensation on right and left side of body. Ascend from the foot upward and ask the patient to identify the level where touch is first appreciated or becomes more pronounced.

- **Vibration**

Test item: 256 Hz Tuning fork. Strike the fork and hold it to a bony prominence such as the first toe, ankle malleolus, tibial plateau, or ilium. Having to increase the vibration and apply more proximal stimulation implies that the deficit is more pronounced.

- **Pain**

Test item: Sterile pin. Touch the patient with the sharp or dull end and ask them to identify “sharp or dull” with the eyes closed. One can also ascend from the foot upwards and ask the patient to identify the level where appreciation of sharpness occurs or where an appreciable increase in sensation occurs.

- **Temperature**

HOME

AAN.COM

©2013 American Academy of  
Neurology - All Rights Reserved

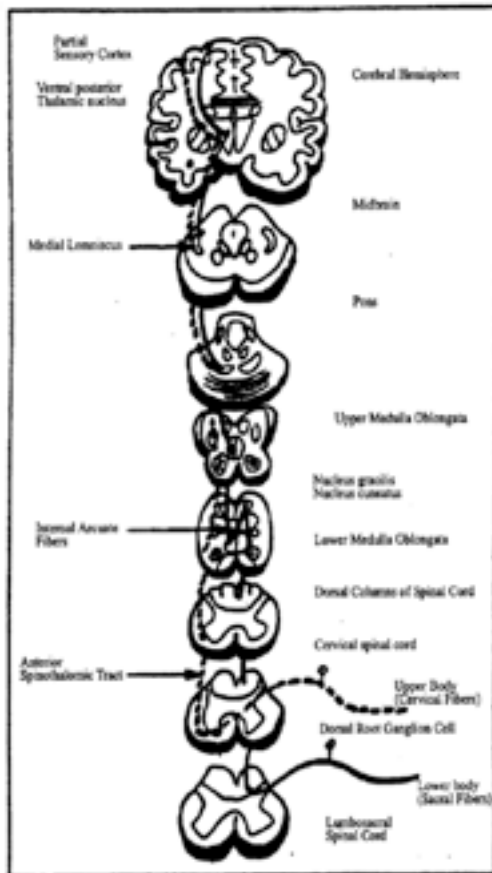
FOR MORE INFORMATION

memberservices@aan.com

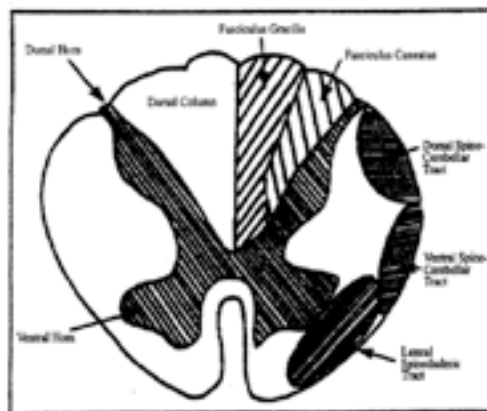
OR

(800) 870-1960 • (612) 928-6000





**Figure 2-23:** Proprioceptive – light touch sensory pathway.



**Figure 2-24:** Ascending sensory pathways – Cervical spinal cord.

Test item: Cold tuning fork; hot and cold water in a test tube or flask. With eyes closed ask them to identify when touched with hot or cold. Levels and laterality can also be tested as described for pain and light touch.

- **Position sense**

Move patient's finger and, later, toe up or down with the patient's eyes closed, and ask them to identify the direction of the motion. Greater deficits are characterized by having to move a more proximal joint such as ankle, knee or hip for the patient to appreciate the movement.

### Cortical Discrimination Testing (Combined sensation)

Simple sensations can be appreciated and poorly localized at the thalamic level. It is at the cortical level that sensations are combined and integrated into meaningful and symbolic information. A cortical lesion is usually recognized if there is not a significant absence or loss of primary sensory modalities, and the patient is unable to integrate the appreciated sensations into symbolic information. When sensory recognition functions are impaired a lesion is implied in the contralateral parietal lobe. Basic tests for these modalities are:

**Two point discrimination.** Test item: small calipers. These may be applied to the face, fingertips, palms and tibial regions. The usual sensory thresholds are: face 2-5 mm; finger tips 3-6 mm; palms 10-15 mm; and shins 30-40 mm. Increased distance threshold or loss of this ability implies a contralateral parietal lobe lesion.

**Stereognosis.** This is the ability to identify an object only by feeling it. The

patient is asked to close their eyes. A test object is placed in the hand being tested. The patient can manipulate and feel the object with the test hand only and is asked to identify it. Test items can include a key, thimble, coin or bolt. The side suspected to be abnormal is usually tested first.

**Traced figure identification.** Numbers (1-9) are traced on the fingertips or palms of the hands while the patient's eyes are closed. The examiner orients himself so that the numbers are upright to the patient. The patient is asked to identify each

HOME

AAN.COM

©2013 American Academy of  
Neurology - All Rights Reserved

FOR MORE INFORMATION

memberservices@aan.com

OR

(800) 870-1960 • (612) 928-6000

number.

**Double simultaneous stimulation.** Homologous parts of the body are touched simultaneously or separately (e.g., right hand, both hands, left hand). The patient is asked to answer right, left or both hands. With a parietal lobe lesion the patient may not identify being touched on the side opposite the lesion when right and left sides are simultaneously stimulated. This phenomenon is termed sensory extinction.

It will be through repetition and clinical correlation that one becomes proficient at doing the sensory examination. The more commonly seen sensory loss patterns are listed below.

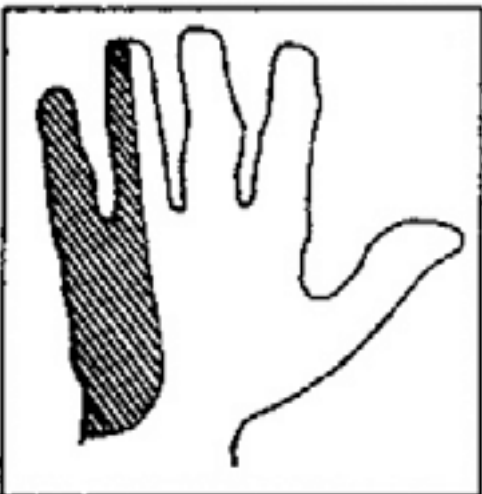
### 1. Isolated nerve lesions (mononeuropathy)

- Median nerve (Carpal tunnel syndrome) **Figure 2-25**
- Ulnar nerve (Elbow entrapment) **Figure 2-26**
- Lateral femoral cutaneous nerve (meralgia paresthetica) **Figure 2-19**

### 2. Mononeuritis multiplex



**Figure 2-25:** Sensory distribution of the median nerve – Palm of hand.



**Figure 2-26.** Sensory distribution of the ulnar nerve – Palm of hand.

Combinations of peripheral nerve lesions occur, usually caused by nerve infarcts secondary to vasculitis or diabetic vasculopathy.

### 3. Sensory peripheral neuropathy

Disease affecting peripheral nerves may affect the Schwann cell myelin sheath (**demyelinating neuropathy**) or the nerve axons (**axonal neuropathy**). These two types are usually clinically indistinguishable in sensory neuropathies. Motor axonal neuropathy is associated with muscle atrophy. Peripheral neuropathy characteristically starts in the feet and is symmetrical. Progression is characterized by rising deficit levels in the legs and eventual involvement of the fingers. In any peripheral nerve or root lesion the sensory or motor arc of the deep tendon reflex can be interrupted leading to **diminished** or **absent deep tendon reflexes**. Distal reflexes (ankle) are diminished more than proximal reflexes (biceps).

### 4. Root lesion

The dermatome maps for the sensory distribution of individual roots are shown in **Figure 2-20**. Root lesions may manifest a vague sensory alteration or loss following the corresponding dermatome, or no objective sensory loss. Often the patient will have paresthesias

HOME

AAN.COM

©2013 American Academy of  
Neurology - All Rights Reserved

FOR MORE INFORMATION

 [memberservices@aan.com](mailto:memberservices@aan.com)

OR

 (800) 870-1960 • (612) 928-6000

in the root distribution. The location of common root paresthesias are C-5, shoulder region; C-6, thumb; C-7, middle finger; C-8, 5<sup>th</sup> finger; L-3, anterior thigh; L-5, great toe; and S-1, medial sole of the foot. If a patient cannot appreciate the sensation of bladder fullness, passing stools, or sexual sensations, it may imply deficits of the S-3, 4, 5 sensory roots.

Sensory loss or characteristic paresthesias, when combined with a root pattern of muscle weakness, will confirm the presence of radiculopathy. Root lesions are also, usually characterized by the presence of pain, especially if the root is being compressed.

## 5. Spinal cord

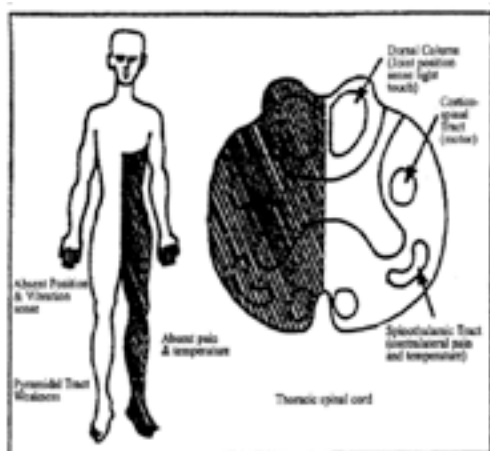
Lesions of the spinal cord are usually of two different types—**external (compressive)** lesions and intrinsic lesions.

External compressive lesions affect the spinal cord as a whole, even though one side may be compressed more. As a result all tracts are affected to some degree. Because the corresponding nerve root is also compressed or stretched, pain is a prominent symptom. Ascending and descending pathways are interrupted and sensation is usually diminished distal to the lesion. Localizing signs would be localized root pain, sensory loss below the level of the lesion, an absent root reflex at the level of the lesion, and generally increased reflexes below this level. Compressive lesions can be caused by herniated discs, tumors or abscess, among others.

Because sensory fibers separate into distinct tracts when they enter the spinal cord some are affected by intrinsic spinal cord lesions while others are completely spared. This produces a characteristic finding of intrinsic cord lesions termed sensory dissociation. These lesions may be caused by infarction, tumor or a syrinx. Some common cord syndromes are:

Brown-Sequard syndrome (**Figure 2-27**)

- ipsilateral plegia below the lesion.
- ipsilateral proprioception and light touch loss below the lesion.
- contralateral pain and temperature loss below the lesion.



**Figure 2-27:** Brown-Sequard Syndrome (Unilateral hemi-cord lesion).

Anterior spinal artery infarction (**Figure 2-28**)

- Paraplegia below the lesion.
- Pain and temperature loss below the lesion.
- Sparing of dorsal column sensation.

Central cord syndrome (cervical) (**Figure 2-29**)

- Shawl distribution pain and temperature loss.
- Sparing of light touch and proprioception.
- Lower motor neuron weakness of the affected cord levels (anterior horn cell involvement).

HOME

AAN.COM

©2013 American Academy of Neurology - All Rights Reserved

FOR MORE INFORMATION

 [memberservices@aan.com](mailto:memberservices@aan.com)

OR

 (800) 870-1960 • (612) 928-6000

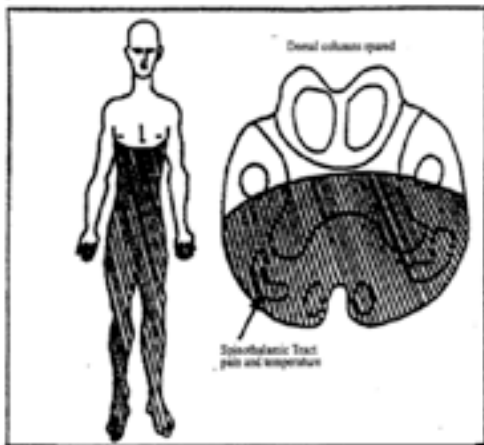


Figure 2-28: Anterior Spinal Artery Infarction.

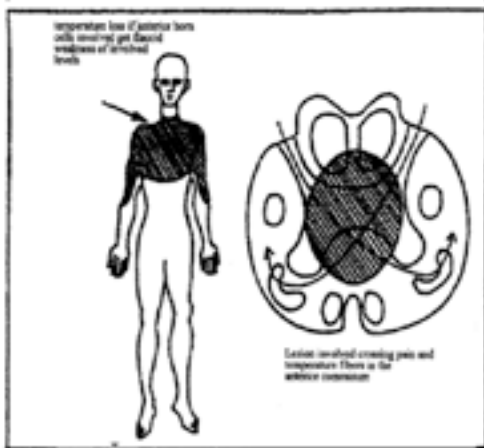


Figure 2-29: Central cord syndrome.

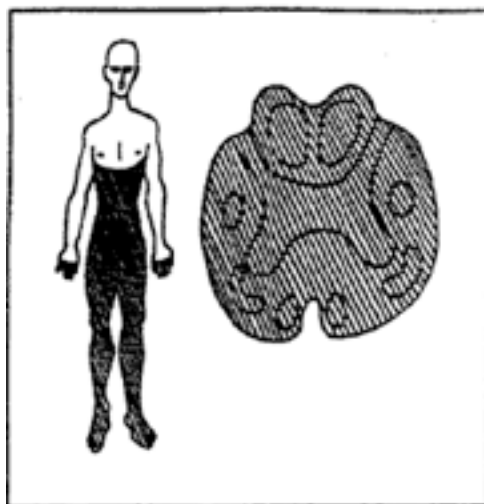


Figure 2-30: Complete spinal cord transection.

Complete cord transection.  
 (Figure 2-30)

- loss of all modalities below the level of the lesion

## 6. Brainstem

Brainstem lesions at the level of the medulla have ipsilateral loss of pain and temperature of the face and contralateral loss on the body. Light touch and proprioceptive loss is contralateral. Above this level all sensory modality findings are contralateral to the side of the lesion because all pathways have crossed.

## 7. Thalamus

Thalamic lesions produce contralateral loss of all sensory modalities in the face, extremities and trunk. In addition, stimulation may be perceived as uncomfortable and painful (dysesthesia).

## 8. Cortical lesions

Lesions of the cerebral cortex cause diminution of all sensory modalities on the contralateral side of the body. In addition, higher integrative sensory functions are impaired causing defects in stereognosis, two-point discrimination, double simultaneous stimulation and traced figure identification as previously discussed. The extent of the sensory loss parallels the size of the lesion. The pattern of cortical sensory representation in the cerebral cortex is illustrated in Figure 2-22.

The foregoing contains essentials of the sensory examination and should become easier to perform and interpret with continued use. The video on how to perform the neurological examination should be watched as well.

HOME

AAN.COM

©2013 American Academy of  
 Neurology - All Rights Reserved

FOR MORE INFORMATION

 [memberservices@aan.com](mailto:memberservices@aan.com)

OR

 (800) 870-1960 • (612) 928-6000

## Summary

Characteristics of sensory system lesions:

- Peripheral nerve**
  - All sensory modalities are affected.
  - The borders are sharply demarcated.
  - There may be hyperesthesia, discomfort and pain.
- Root**
  - All sensory modalities are affected.
  - Sensory loss is vague but in a dermatomal distribution.
  - Pain is present and may radiate in the dermatome distribution.
- Spinal cord**
  - There is sensory dissociation.
  - A unilateral lesion produces ipsilateral loss of light touch and proprioception and contralateral loss of pain and temperature.
- Medulla**
  - There is sensory dissociation.
  - Pain and temperature are lost on the ipsilateral side of the face and contralateral side of the body.
  - Light touch and proprioception are lost on the contralateral side of the body.
- Upper brainstem**
  - There is sensory dissociation.
  - All sensory modalities are now crossed and on the same side.
  - Unilateral lesions cause contralateral loss of sensory modalities.
- Thalamus**
  - Sensory dissociation is no longer present.
  - Ipsilateral lesions produce contralateral loss of all modalities.
- Cerebral cortex**
  - Sensory dissociation is absent.
  - Ipsilateral lesions produce contralateral loss of all modalities.
  - Discriminative sensory functions are lost.

### The Extrapyramidal System (Video)

Reflect back to our description of the marionette, lying limp on the floor. **(Review Section on System Integration)** If the puppeteer wants to simulate normal, life-like action, he first puts tension on the strings that cause the legs, trunk and neck to become erect. Similarly, activation of extensor muscle systems finally allows the developing neonate to stand. This function is carried out by an unconscious indirect motor system, called the **extrapyramidal system (EPS)**. It is a primitive system, and is not fully understood.

The EPS basically consists of a group of large subcortical nuclei termed the **basal ganglia**. They include the **caudate nucleus, and putamen** (collectively

HOME

AAN.COM

©2013 American Academy of  
Neurology - All Rights Reserved

FOR MORE INFORMATION

 [memberservices@aan.com](mailto:memberservices@aan.com)

OR

 (800) 870-1960 • (612) 928-6000

termed the **striatum**), the **globus pallidus, substantia nigra** and the **subthalamic nucleus**. These nuclei receive input from the primary motor cortex (pyramidal system), have multiple reverberating connections among themselves, and send output to the **ventral anterior thalamic nucleus**, which in turn connects back to the motor cortex. There is also some output to **reticulospinal tracts**, which travel down the spinal cord and have a modulating effect on anterior horn cells which ultimately initiate movement. By and large, however, the EPS is a reverberating circuit receiving input from the motor cortex, processing it through its nuclei, and then send

### Navigation

- Section 1
- Section 2
- Section 3
- Section 4



HOME

AAN.COM

©2013 American Academy of  
Neurology - All Rights Reserved

### FOR MORE INFORMATION

 [memberservices@aan.com](mailto:memberservices@aan.com)

OR

 (800) 870-1960 • (612) 928-6000