

## Review

## The functional neuroanatomy of dystonia

Vladimir K. Neychev<sup>a</sup>, Robert E. Gross<sup>b</sup>, Stephane Lehericy<sup>c</sup>, Ellen J. Hess<sup>d</sup>, H.A. Jinnah<sup>e,\*</sup><sup>a</sup> Department of Surgery, Danbury Hospital, CT, USA<sup>b</sup> Departments of Neurosurgery and Neurology, Emory University, Atlanta, USA<sup>c</sup> Service de Neuroradiologie, Centre de Neuroimagerie de Recherche-CENIR, CR-ICM, Hopital Pitie-Salpetriere, Université Pierre et Marie Curie, Paris, France<sup>d</sup> Departments of Pharmacology & Neurology, Emory University, Atlanta, USA<sup>e</sup> Departments of Neurology, Human Genetics, & Pediatrics, Emory University, Atlanta, USA

## ARTICLE INFO

## Article history:

Received 8 October 2010

Revised 8 January 2011

Accepted 28 January 2011

Available online 12 February 2011

## Keywords:

Cerebellum

Basal ganglia

Thalamus

Deep brain stimulation

Animal model

History

## ABSTRACT

Dystonia is a neurological disorder characterized by involuntary twisting movements and postures. There are many different clinical manifestations, and many different causes. The neuroanatomical substrates for dystonia are only partly understood. Although the traditional view localizes dystonia to basal ganglia circuits, there is increasing recognition that this view is inadequate for accommodating a substantial portion of available clinical and experimental evidence. A model in which several brain regions play a role in a network better accommodates the evidence. This network model accommodates neuropathological and neuroimaging evidence that dystonia may be associated with abnormalities in multiple different brain regions. It also accommodates animal studies showing that dystonic movements arise with manipulations of different brain regions. It is consistent with neurophysiological evidence suggesting defects in neural inhibitory processes, sensorimotor integration, and maladaptive plasticity. Finally, it may explain neurosurgical experience showing that targeting the basal ganglia is effective only for certain subpopulations of dystonia. Most importantly, the network model provides many new and testable hypotheses with direct relevance for new treatment strategies that go beyond the basal ganglia. This article is part of a Special Issue entitled "Advances in dystonia".

© 2011 Elsevier Inc. All rights reserved.

## Contents

Introduction . . . . .	186
Historical perspective . . . . .	186
The basal ganglia in dystonia . . . . .	186
Evidence for involvement of the basal ganglia . . . . .	186
Limitations of the basal ganglia paradigm . . . . .	188
A reappraisal of the evidence . . . . .	188
Evidence from neuropathology . . . . .	189
Evidence from human neuroimaging . . . . .	191
Lesion studies . . . . .	191
[ <sup>18</sup> F]-fluorodeoxyglucose-PET studies . . . . .	192
PET studies of blood flow . . . . .	192
fMRI studies . . . . .	192
DTI and tractography . . . . .	192
Quantitative structural imaging . . . . .	192
Summary of human neuroimaging . . . . .	193
Evidence from human physiology . . . . .	193
Loss of inhibition . . . . .	193
Defects in sensorimotor integration . . . . .	193
Maladaptive neural plasticity . . . . .	194
Associations of dystonia with other clinical disorders . . . . .	194

\* Corresponding author at: Woodruff Memorial Building Suite 6000, 101 Woodruff Circle, Atlanta GA, 30322, USA. Fax: +1 404 712 8576.

E-mail address: [hjinnah@emory.edu](mailto:hjinnah@emory.edu) (H.A. Jinnah).Available online on ScienceDirect ([www.sciencedirect.com](http://www.sciencedirect.com)).

Evidence from neurosurgery . . . . .	195
Evidence from animal models . . . . .	195
A revised model for the functional anatomy of dystonia . . . . .	196
The network model . . . . .	196
Integrating function and dysfunction . . . . .	197
Conclusions . . . . .	198
Acknowledgments . . . . .	198
References . . . . .	198

## Introduction

Dystonia is defined as a syndrome of involuntary sustained or intermittent muscle contractions leading to twisting or repetitive movements or abnormal postures (Fahn, 1984; Fahn, 1988). The core problem involves over-contraction of the primary muscles normally used for a movement, along with over-flow contraction of nearby muscles that sometimes antagonize the primary muscles. The patterns and strengths of the muscles involved determine the character of the resulting abnormal movement. Very mild dystonias appear as slight exaggerations or distortions of otherwise normal movements. More obvious manifestations include movements that are overtly stiff, slow, twisting, or jerky. The most serious expressions involve unnatural postures or fixed deformities associated with significant disability.

Virtually any region of the body may be affected, and the region affected provides a convenient means for subgrouping (Fahn, 1988; Geyer and Bressman, 2006; Tarsy and Simon, 2006). Focal dystonias involve an isolated body region. Commonly recognized focal dystonias include the neck in cervical dystonia (torticollis), the upper face (blepharospasm), the larynx (spasmodic dysphonia), or a limb (writer's cramp). Segmental dystonias involve two or more contiguous body regions, such as the neck and one arm. Multifocal dystonias involve two or more non-contiguous regions, while generalized dystonias encompass a broad distribution.

The dystonias also can be grouped according to etiology, with both inherited and acquired forms (Bressman, 2003; deCarvalho Aguiar and Ozelius, 2002; Nemeth, 2002). Dystonia is associated with mutations in more than 30 different genes, is a feature of several neurodevelopmental or neurodegenerative disorders, and can arise from a vast array of acquired insults to the nervous system. Traditionally, etiological subgroups of dystonia have included primary dystonia, dystonia-plus syndromes, developmental or degenerative disorders, and acquired insults. Primary dystonias include disorders where dystonia is a relatively isolated neurological problem and there is no histopathological evidence for developmental or degenerative anomalies. Many primary dystonias are idiopathic, but some are due to known genetic defects. The dystonia-plus syndromes include dystonia with other neurological problems, again without significant histopathological correlates. In contrast, the developmental and degenerative syndromes include specific histopathological hallmarks. Acquired forms are defined by specific causes; some have histopathological correlates (e.g. stroke or traumatic brain injury), while others do not (e.g. drug-induced dystonias).

The current review addresses regions of the nervous system underlying the dystonias. Delineating the functional neuroanatomical substrates for dystonia is of fundamental importance for both clinical and basic research. Knowing the responsible brain regions is a prerequisite for more precise studies of neuronal physiology and biochemistry, and for designing both medical and surgical treatment strategies. In keeping with currently used definitions of dystonia, this review focuses on dystonia as a syndrome of abnormal movements, not a specific disease entity. Although etiological heterogeneity raises the possibility that different dystonias may have different neuroanatomical substrates, the working premise is that some dystonias share common biological substrates (Defazio et al., 2007; Jinnah and Hess, 2008).

## Historical perspective

Historically, delineating a new neurological disease as a distinct nosological entity required linking specific clinical features with consistent neuropathological changes. Hammond was among the first to describe pathology of the basal ganglia in an individual with athetosis (Hammond, 1890), a diagnosis that historically overlapped with dystonia (Morris et al., 2002; Salam-Adams and Adams, 1997; Twitchell, 1961). Hammond's report stimulated others to focus on the basal ganglia, but results were inconsistent. Most notable was the absence of consistent pathology in cases with pure dystonia, now designated as primary dystonias. It was the failure to establish consistent clinico-pathological correlations that led to the rejection of pure dystonia as a neurological disorder at the 10th International Neurological Meeting in 1929 (Wimmer, 1929).

The view that pure dystonia was a psychiatric disorder prevailed for nearly five decades, but some investigators continued to find evidence for an organic basis (Munts and Koehler, 2010). In one of the earliest reviews on the neuropathology of dystonia that included 17 affected individuals, Herz cataloged abnormalities in the putamen, caudate, pallidum, and thalamus (Herz, 1944). Herz emphasized the organic nature of some dystonias, disregarding pure forms where pathology was not apparent. In subsequent studies, Zeman distinguished two subclasses of dystonias (Zeman, 1970). Overt basal ganglia pathology was frequent among those with dystonia secondary to another disorder such as Wilson's disease, kernicterus, perinatal injuries or ischemic lesions. Pathology was not evident in pure dystonias, which he viewed as disorders of biochemistry or function.

These early neuropathological studies have played a dominant and enduring role in modern concepts regarding the neural substrates of dystonia. Today, many investigators work under the premise that dysfunction of the basal ganglia is responsible for *all* forms of dystonia. This premise is evident in experimental studies that focus exclusively on the basal ganglia, in studies that dismiss changes in other brain regions as epiphenomenal, in reviews that exclusively summarize evidence relating to the basal ganglia, and in descriptions of dystonia that imply dysfunction of the basal ganglia is a defining characteristic. In fact, some writers use the term "pseudodystonia" for dystonic movements that do not have their origin in basal ganglia dysfunction. However, modern definitions of dystonia are based on the nature of abnormal movements without presuming any specific neuropathological substrate. This review encompasses evidence relating to any brain region that may be relevant for dystonic movements.

## The basal ganglia in dystonia

### *Evidence for involvement of the basal ganglia*

The evidence supporting a role for the basal ganglia in dystonia is strong; but it will be summarized here only briefly, since it has been reviewed many times by others (Berardelli et al., 1998; Breakefield et al., 2008; Hallett, 2006). As noted above, the role of the basal ganglia originated with studies showing neuropathological defects in the basal ganglia of individuals with various secondary forms of dystonia (Hedreen et al., 1988; McGeer and McGeer, 1995). These early studies later were supported by results from neuroimaging including CT or MRI, where focal lesions often were found in the basal

ganglia and especially the putamen. In an influential 1985 article, Marsden reported that the most frequent lesions detected by CT among 28 patients with symptomatic hemidystonia or isolated limb dystonia were in the putamen, caudate nucleus, and posterior ventral areas of the thalamus, occurring mostly in combination (Marsden et al., 1985). These findings were supported by Pettigrew and Jankovic who studied 22 patients (Pettigrew and Jankovic, 1985) and by Obeso and Gimenez-Roldan who studied 39 patients (Obeso and Gimenez-Roldan, 1988). Bhatia and Marsden later showed that dystonia occurred in 36% of 240 cases with basal ganglia lesions described in the literature (Bhatia and Marsden, 1994). These large case series have been supported by numerous smaller series and case reports.

Even when overt lesions could not be identified by neuropathological or structural imaging methods, more sophisticated imaging studies identified regions of abnormal brain activity. These studies are summarized in several reviews (Asanuma et al., 2005a; Carbon and Eidelberg, 2009; Meunier et al., 2003; Niethammer et al., in press; Troiano and Stoessl, 2008) and in Tables 1–5. Abnormalities in the basal ganglia have been documented for a wide variety of different forms of dystonia by positron-emission tomography (PET) studies of regional metabolic activity detected with [<sup>18</sup>F]-fluorodeoxyglucose (FDG-PET) uptake or regional blood flow, voxel-based morphometry (VBM), functional magnetic resonance imaging (fMRI), and diffusion tensor imaging (DTI).

Clinical associations of dystonia with other movement disorders have also pointed to the basal ganglia. For example, dystonia often co-exists with parkinsonism in idiopathic Parkinson's disease and several Parkinson-plus syndromes (Jankovic and Tintner, 2001; Rivest et al., 1990; Schneider et al., 2009; Tolosa and Compta, 2006), where the primary pathology involves dysfunction of dopaminergic and other basal ganglia pathways (Perlmutter and Mink, 2004; Schneider et al., 2009). Dysfunction of nigrostriatal pathways also is thought to be responsible for both acute dystonic reactions and tardive dystonia associated with antagonists of dopamine receptors. Dystonia similarly

co-exists with chorea, for example in Huntington's disease where there is prominent degeneration of the striatum (Louis et al., 1999).

The basal ganglia further have been implicated by studies of neurosurgical interventions showing that dystonia improves in patients following thermolytic lesions of the internal segment of the globus pallidus (Gross, 2008; Marks, 2007). Evidence from deep brain stimulation (DBS) of the same region is particularly compelling, since dystonia remits when stimulation is turned on, and returns when stimulation is turned off (Grabli et al., 2009; Ostrem and Starr, 2008). Benefits are not universal but occur in primary generalized and focal dystonias, dystonia-plus syndromes, tardive dystonia, and some developmental or degenerative disorders.

Finally, animal studies frequently have implicated the basal ganglia in dystonia, as noted in several reviews (Guehl et al., 2009; Jinnah et al., 2005; Richter and Loscher, 1998). For example, selective lesions of the nigrostriatal dopamine pathway with the toxins 6-hydroxydopamine or MPTP result in dystonic movements in both rodents (Winkler et al., 2002) and primates (Perlmutter et al., 1997; Tabbal et al., 2006). Lesions of the striatum with the toxin 3-nitropropionic acid similarly cause dystonia in both rodents (Fernagut et al., 2002) and primates (Cuny et al., 2008; Ghorayeb et al., 2002; Palfi et al., 1996). In primates, focal destructive lesions of the posterior putamen also result in dystonia (Burns et al., 1995). In aggregate, these results provide strong converging support that the basal ganglia play an important role in dystonia.

Several theoretical paradigms have been developed to explain the mechanisms by which basal ganglia defects may cause dystonia. One paradigm for predicting the consequences of basal ganglia dysfunction is based on the existence of parallel but separate excitatory and inhibitory pathways for motor output (DeLong and Wichmann, 2007). In this paradigm, imbalances between the two pathways predict hypokinetic and hyperkinetic motor disorders. Another paradigm proposes the existence of a filtering or selection process that amplifies intended movement while suppressing extraneous or competing ones

**Table 1**  
Fluorodeoxyglucose PET studies of dystonia.

Type of dystonia	Cases/controls	Regions affected				Source
		BG	CRB	CTX	Other	
Blepharospasm	6/6		Verm (↑)		Pons (↑)	(Hutchinson et al., 2000)
Blepharospasm	11/11	Caud (↑)	Hem (↓)	Cing (↑) Temp (↑)	Thal (↓)	(Kerrison et al., 2003)
Blepharospasm	25/38				Thal (↑) Pons (↑)	(Suzuki et al., 2007)
Blepharospasm	22/44				Thal (↑) Mid (↓)	(Emoto et al., 2010)
Cervical dystonia <sup>a</sup>	13/11					(Stoessl et al., 1986)
Cervical dystonia	10/15	Put (↑)	Hem (↑)	PreM (↑)	Thal (↑)	(Galardi et al., 1996)
Cervical dystonia	10/10	Put (↑)				(Magyar-Lehman et al., 1997)
DOPA-responsive dystonia	7/14	Put (↓)	Verm (↑)	SMA (↑) PreM (↓)	Mid (↑)	(Asanuma et al., 2005b)
DYT1 dystonia	10/14	Put (↑)	Hem (↑)	SMA (↑)	Thal (↑) Mid (↑)	(Eidelberg et al., 1998)
DYT1 dystonia <sup>b</sup>	7/14	Put (↑)	Hem (↑)	SMA (↑)		(Eidelberg et al., 1998)
DYT1 dystonia	23/11	Put (↑)	Hem (↑)			(Carbon et al., 2004b)
DYT6 dystonia	13/11	Put (↓)		Cing (↑) Temp (↑)		(Carbon et al., 2004b)
Mixed dystonias <sup>c</sup>	8/8					(Otsuka et al., 1992)
Mixed dystonias <sup>c</sup>	15/31	Caud (↓) Put (↓)	Hem (↑)	FC (↓) PreF (↓)	BS (↑)	(Karbe et al., 1992)
Mixed dystonias <sup>c</sup>	11/11	Put (↑)		PreM (↑) SMA (↑)	Mid (↑) Pons (↑)	(Eidelberg et al., 1995)

Fluorodeoxyglucose PET studies of dystonia are listed according to type of dystonia. Arrows indicate increased (↑) or decreased (↓) tracer uptake. Studies that compared multiple types of dystonia with a single control group are listed according to type of dystonia rather than as a combined group. Studies reporting only abnormal relationships among regions rather than absolute changes are not listed. Abbreviations: BS (brainstem), Caud (caudate), Cing (cingulate gyrus), FC (frontal cortex), Hem (cerebellar hemisphere), Mid (midbrain), PreF (prefrontal cortex), PreM (premotor cortex), PM (primary motor cortex), PS (primary sensory cortex), Put (putamen), STL (superior temporal lobe), SMA (supplementary motor area), Temp (temporal cortex), Verm (cerebellar vermis).

<sup>a</sup> No abnormalities were identified in any region, but there was an abnormal relationship between putamen and thalamus.

<sup>b</sup> Unaffected DYT1 mutation carriers were compared with controls.

<sup>c</sup> These studies included a mixture of generalized and focal idiopathic dystonias.

**Table 2**  
PET blood flow studies of dystonia.

Type of dystonia	Cases/Controls	Task(s)	Regions affected			Source
			CTX (↑)	CTX (↓)	Other	
Blepharospasm	7/7	Vibrotactile stimulation		SMC		(Feiwell et al., 1999)
Cervical dystonia	7/7	Effect of sensory trick	Par	SMA, SMC		(Naumann et al., 2000)
DYT1 dystonia <sup>a</sup>	6/8	Rest, joystick	DLPFC, Par, PreM, PM, Temp		Caud (↑) CRB (↑) GP (↑) Thal (↑)	(Detante et al., 2004)
DYT1 dystonia <sup>b</sup>	6/6	Motor sequence learning	Temp	Cing, DLPF, PM	CRB (↑)	(Carbon et al., 2007)
DYT1 dystonia <sup>c</sup>	19/12	Reaching	PreM, SMA, SMC		CRB (↑)	(Carbon et al., 2010)
Generalized (idiopathic) <sup>d</sup>	6/6	Rest, joystick	Cing, <sup>e</sup> DLPFC, PreM, SMA <sup>e</sup>	Cing, <sup>e</sup> Par, SMA <sup>e</sup>	Put (↑)	(Ceballos-Baumann et al., 1995b)
Generalized (idiopathic)	6/6	Rest, joystick	Cing, DLPFC, Par, PreM, SMA	PM, PS	Put (↑) CRB (↑)	(Playford et al., 1998)
Hemidystonia	5/5	Joystick	Cing, Ins, Par, PreM, SMA, SMC		CRB (↑)	(Ceballos-Baumann et al., 1995a)
Mixed focal dystonias	11/18	Vibrotactile stimulation		SMC		(Tempel and Perlmutter, 1990)
Spasmodic dysphonia	9/10	Rest, speak, whisper	PreM, PM, SMC, Aud	SMA, Temp	BS (↓)	(Ali et al., 2006)
Tardive dystonia	5/8	Joystick ± DBS	Cing, PreF, PreM		CRB (↑)	(Thobois et al., 2008)
Writer's cramp	6/6	Write	Cing, <sup>e</sup> DLPFC, Ins, Par, <sup>e</sup> PreM, PS, SMA <sup>e</sup>	Cing, <sup>e</sup> Par, <sup>e</sup> PM, PreF, SMA	CRB (↑) Thal (↓)	(Ceballos-Baumann et al., 1997)
Writer's cramp	7/7	Write, finger tap		Cing, PreM, SMA, SMC		(Ibanez et al., 1999)
Writer's cramp	4/4	Write	PreM, SMC		CRB (↑) Thal (↑)	(Odergren et al., 1998)
Writer's cramp	10/10	Rest, write, finger tap	PM, PreM, PS	SMA		(Lerner et al., 2004)

Positron emission tomography (PET) studies of cerebral blood flow are shown according to type of dystonia. Arrows indicate increased (↑) or decreased (↓) regional blood flows. Results show differences between dystonia patients and controls, and do not show secondary analyses such as effects of deep brain stimulation or abnormal relationships among brain regions. Abbreviations: Caud (caudate), Cing (cingulate cortex), CRB (cerebellum), DLPFC (dorsolateral prefrontal cortex), GP (globus pallidus), Par (parietal cortex), PreF (prefrontal cortex), PreM (premotor cortex), PM (primary motor cortex), PS (primary sensory cortex), Put (putamen), SMA (supplementary motor area), Temp (temporal cortex), Thal (thalamus).

<sup>a</sup> Most patients were DYT1 mutation positive, except for one.

<sup>b</sup> Patients were non-manifesting mutation carriers.

<sup>c</sup> Patients included 10 non-manifesting and 9 manifesting mutation carriers.

<sup>d</sup> Most patients had generalized or multifocal dystonia, although one had focal hand dystonia.

<sup>e</sup> This region showed increased or decreased perfusion depending on the subregion examined.

(Mink, 2003). A third paradigm relates dystonia to an imbalance between the striosomal and matrix compartments within the basal ganglia (Goto et al., 2005). To date, conclusive experimental support for any of these basal ganglia paradigms for dystonia is lacking.

#### Limitations of the basal ganglia paradigm

Despite the strengths of the associations between dystonia and the basal ganglia, the correlations between dystonia and basal ganglia are not absolute. For example, there are many patients with dystonia and lesions that do not affect the basal ganglia or its connections (Marsden et al., 1985; Obeso and Gimenez-Roldan, 1988; Pettigrew and Jankovic, 1985). This observation implies that other regions may also play a role. There also are many patients with basal ganglia lesions but no dystonia, implying that basal ganglia lesions do not consistently result in dystonia (Bhatia and Marsden, 1994). This inconsistency may reflect the importance of a specific subregion such as the sensorimotor territory of the basal ganglia. Even when overt structural defects in the basal ganglia are linked with dystonia, the emergence of the clinical manifestations is commonly delayed by weeks or years following the lesion, implying that loss of function from the lesion itself is not a direct cause for dystonia (Pettigrew and Jankovic, 1985; Scott and Jankovic, 1996). These loose correlations between basal ganglia lesions and dystonia provide clues that some additional unrecognized influences are involved.

Another line of evidence challenging the concept that dystonia is exclusively due to basal ganglia dysfunction comes from modern imaging studies (Asanuma et al., 2005a; Carbon and Eidelberg, 2009; Meunier et al., 2003; Niethammer et al., in press; Troiano and Stoessl, 2008). The most comprehensive surveys reveal that abnormalities are not limited to this region; they occur also in the cerebral cortex,

cerebellum, thalamus, midbrain, and brainstem (reviewed below). Functional links with the basal ganglia are sometimes invoked to account for changes in some of these regions, such as those in the midbrain or cortex. Changes in other regions such as the cerebellum often are interpreted as compensatory. However, functional imaging techniques provide a correlative result that does not permit discrimination of cause from consequence.

Neurosurgical treatments frequently are cited as evidence for a causal relationship between basal ganglia dysfunction and dystonia. However, the benefits of surgery are limited to specific subpopulations, suggesting etiological heterogeneity in the functional anatomy of different subtypes of dystonia. Surgical benefits targeting the pallidum in dystonia typically are delayed by several weeks or months, implying that success depends on secondary neural responses to the procedure. Finally, the success of surgery does not provide conclusive evidence that the region targeted is the source of the problem; it may be a single site in a broader network.

Perhaps the strongest evidence against the paradigm relating dystonia strictly to basal ganglia dysfunction comes from studies of animals. Some animal models point to dysfunction of the basal ganglia in dystonia, but others point to different regions, most notably the cerebellum or midbrain/brainstem (reviewed below). In summary, there is strong evidence that the basal ganglia play a role in dystonia. However, multiple clues argue against a paradigm focusing on dysfunction of basal ganglia circuits alone.

#### A reappraisal of the evidence

In this section the evidence supporting a role of for the basal ganglia in dystonia is critically reappraised and updated. The goal is not to refute the evidence supporting the involvement of the basal

**Table 3**  
Functional MRI studies of dystonia.

Type of dystonia	Cases/controls	Task(s)	Regions affected				Source
			BG	CRB	CTX	Other	
Blepharospasm	6/4	Blink	Put (↑)				(Schmidt et al., 2003)
Blepharospasm	13/13	Whistle			PS (↑) SMA (↑)		(Dresel et al., 2006)
Focal hand/arm dystonia	9/9	Vibratory stimulation			SS (↓) Par (↓)		(Butterworth et al., 2003)
Focal hand dystonia	11/11	Finger tap	Put (↓)	Hem (↓)	Par (↓) SMA (↓) SMC (↓)		(Wu et al., 2010)
Musician's dystonia (embouchure)	10/10	Blow mouth-piece	Caud (↑)		PS (↑) PM (↑) Par (↑) SMA (↑) Temp (↑)	Thal (↑)	(Haslinger et al., 2010)
Musician's dystonia (hand)	5/3	Simulate guitar			PreF (↓) SMC (↑)		(Pujol et al., 2000)
Musician's dystonia (hand)	7/10	Finger tap		Hem (↓)	PreM (↑)		(Kadota et al., 2010)
Myoclonus-dystonia	13/11	Finger tap		Hem (↑)	DLPFC (↑) PreM (↑) PM (↑) PS (↑)		(Beukers et al., 2010)
Oromandibular dystonia	13/13	Whistle			PS (↑) PreM (↓) SMA (↑) SMC (↓)		(Dresel et al., 2006)
Post-stroke dystonia	6/7	Imagined and real hand movement	Caud (↑) Put (↑)	Hem (↑)	Cing (↑) Par (↑) PreF (↑) PreM (↑) PM (↑)		(Lehericy et al., 2004)
Spasmodic dysphonia	12/12	Speak, whisper		Hem (↓)	Cing (↓) Par (↓) SMA (↓) SMC (↓) Temp (↓)		(Haslinger et al., 2005)
Spasmodic dysphonia	22/11	Speak, whisper		Hem (↑)	PM (↑) PS (↑) Temp (↑)	Mid (↑)	(Simonyan and Ludlow, 2010)
Writer's cramp	12/10	Write		Hem (↑)	SMC (↑)	Thal (↑)	(Preibisch et al., 2001)
Writer's cramp	17/17	Finger tap			SMC (↓)		(Islam et al., 2009)
Writer's cramp	8/12	Wrist extension			SMA (↓) SMC (↓)		(Oga et al., 2002)
Writer's cramp <sup>a</sup>	5/5	Finger tap	Caud (↑) GP (↑) Put (↑)				(Blood et al., 2004)
Writer's cramp	14/14	Move finger, toe, lip	Abn Map				(Delmaire et al., 2005)
Writer's cramp	10/10	Write	Put (↑)	Hem (↑)	Par (↑) PM (↑) PS (↑) SMA (↑)	Thal (↓)	(Hu et al., 2006)
Writer's cramp	5/5	Tactile discrimination	GP (↑)				(Schneider et al., 2010)
Writer's cramp	17/17	Tactile discrimination	Caud (↑) GP (↑) Put (↑) Thal (↑)				(Peller et al., 2006)
Writer's cramp	12/12	Vibrotactile stimulation			Abn Map PS (↓)		(Nelson et al., 2009)

Functional MRI (fMRI) studies of dystonias are shown according to the type of dystonia. Arrows indicate increased (↑) or decreased (↓) regional changes. When multiple comparisons were made, only differences between dystonic patients and non-dystonic controls are shown. Abbreviations: Abn Map (abnormal mapping in somatosensory cortex), Caud (caudate), Cing (cingulate gyrus), Dent (cerebellar dentate nucleus), DLPFC (dorsolateral prefrontal cortex), GP (globus pallidus), Hem (cerebellar hemisphere), Par (parietal cortex), PreF (prefrontal cortex), PreM (premotor cortex), PM (primary motor cortex), PS (primary sensory cortex), Put (putamen), SMA (supplementary motor area), SMC (sensorimotor cortex), Temp (temporal cortex), Thal (thalamus).

<sup>a</sup> Most patients had writer's cramp but one had focal musician's hand dystonia.

ganglia in dystonia, but to accommodate evidence implicating other brain regions. The evidence comes from a wide array of sources including neuropathology, neuroimaging, links with other disorders, neurophysiology, neurosurgery, and animal models. Because much of the evidence is indirect and incapable of proving causation, the limitations of each line of evidence also are outlined.

#### Evidence from neuropathology

Years before Herz (Herz, 1944) and Zeman (Zeman, 1970) linked histopathological changes of the basal ganglia with dystonia, neurosurgeons recognized that abnormal postures of the head and neck were associated with mass lesions of the posterior fossa. In an



**Table 4**  
Diffusion tensor imaging studies of dystonia.

Type of dystonia	Cases/Controls	Primary measure	Regions affected				Source
			BG	CRB	CTX	Other	
Blepharospasm <sup>a</sup>	18/35	FA MD					(Fabbrini et al., 2008) <sup>b</sup>
Cervical dystonia	15/10	FA MD	Put (↑) Caud (↓) GP (↓) Put (↓)		CC (↓)		(Colosimo et al., 2005) <sup>b</sup>
Cervical dystonia <sup>c</sup>	7/7	FA MD	Caud (↑) GP (↑) Put (↑)		PreF (↓)	Thal (↓)	(Bonilha et al., 2007)
Cervical dystonia	16/35	FA MD	Put (↑) Caud (↓) Put (↓)		CC (↓) PreF (↑) SMA (↑)		(Fabbrini et al., 2008) <sup>b</sup>
DYT1 dystonia <sup>d</sup>	12/17	FA			SMC (↓)		(Carbon et al., 2004a)
DYT1 and DYT6 dystonias	7/8	FA		SSP (↓)	SMC (↓)		(Carbon et al., 2008b)
DYT1 and DYT6 dystonias <sup>e</sup>	20/8	Tractography		CRB-Thal (↓)	Thal-CTX (↓)		(Argyelan et al., 2009)
Spasmodic dysphonia	20/20	FA MD	Put (↑)	MCP (↑)	IC (↓) CBT (↑) CP (↑) IC (↑)	Thal (↑) Thal (↑)	(Simonyan et al., 2008)
Writer's cramp	26/26	FA			IC (↑)		(Delmaire et al., 2009)

Diffusion tensor imaging (DTI) studies of primary dystonias are shown according to type of dystonia. Studies comparing multiple types of dystonia with a single control group or employing multiple methods are listed according to different types of dystonia and method rather than as combined groups. Arrows indicate increased (↑) or decreased (↓) changes in the measurement variable of fractional anisotropy (FA) or mean diffusivity (MD). FA and MD normally are closely related but opposing measures, but differences in sensitivity sometimes yield different results. All reported results are shown, although those for gray matter should be viewed with caution. Abbreviations: Caud (caudate), CP (cerebral peduncle), GP (globus pallidus), IC (internal capsule), MCP (middle cerebellar peduncle), PreF (prefrontal cortex), Put (putamen), SMC (sensorimotor cortex), SCP (superior cerebellar peduncle), SMA (supplementary motor area).

<sup>a</sup> No abnormalities were found.

<sup>b</sup> These studies involved overlapping cohorts of the same patients.

<sup>c</sup> All patients had cervical dystonia but 2 had generalized dystonia and 1 had spasmodic dysphonia.

<sup>d</sup> Comparison combined symptomatic and non-symptomatic patients versus normal controls.

<sup>e</sup> Reduced probability of connections calculated using probabilistic DTI fiber tracking between the cerebellum, thalamus and cerebral cortex.

early review, Grey noted that 23 of 58 patients with posterior fossa tumors, mostly affecting the cerebellum, exhibited "an unusual attitude of the head, tilted so that the ear approximated one

shoulder..." (Grey, 1916). Others similarly noted links between pathology of the posterior fossa with postures "in which the head was held rotated so that the occiput was turned to one side and the

**Table 5**  
Voxel-based morphometry studies of dystonia.

Type of dystonia	Cases/controls	Regions affected				Source
		BG	CRB	CTX	Other	
Blepharospasm	16/16	Put (↑)		IPL (↓)		(Etgen et al., 2006)
Blepharospasm	11/14	Caud (↑) Put (↓)	Hem (↑)		Thal (↓)	(Obermann et al., 2007)
Cervical dystonia	10/10	GP (↑)	Floc (↑)	PM (↑) SMA (↓) DLPFC (↓) OCC (↓)		(Draganski et al., 2003)
Cervical dystonia	11/31	Caud (↑) Put (↓)	Hem (↑)	STL (↑)	Thal (↑)	(Egger et al., 2007)
Cervical dystonia	9/14	Put (↑) GP (↑)				(Obermann et al., 2007)
Cervical dystonia <sup>a</sup>	29/28	Put (↑) GP (↑) Caud (↓) Put (↓)		PM (↓) SMC (↓)		(Draganski et al., 2009)
Cervical dystonia	19/28	Put (↓)		PM (↓) SMC (↓)		(Pantano et al., 2010)
DYT1 dystonia <sup>b</sup>	11/11	Put (↓)		SMC (↑)		(Draganski et al., 2009)
Focal hand dystonias <sup>c</sup>	36/36			SMC (↑)		(Garraux et al., 2004)
Focal hand dystonias <sup>c</sup>	11/31	GP (↑)				(Egger et al., 2007)
Generalized (idiopathic)	9/31	GP (↑)				(Egger et al., 2007)
Writer's cramp	30/30		Hem (↓)	SMC (↓)	Thal (↓)	(Delmaire et al., 2007)
Writer's cramp <sup>d</sup>	14/14			PM (↑)		(Granert et al., 2010)

Voxel-based morphometry (VBM) studies of primary dystonias are shown according to type of dystonia. Arrows indicate increased (↑) or decreased (↓) regional volumes. Studies comparing multiple types of dystonia with a single control group are listed according to type of dystonia rather than as a combined group. Abbreviations: Caud (caudate), Cing (cingulate gyrus), DLPFC (dorsolateral prefrontal cortex), Floc (cerebellar flocculus), GP (globus pallidus), Hem (cerebellar hemisphere), IPL (inferior parietal lobule), PreF (prefrontal cortex), NA (nucleus accumbens), OFC (orbitofrontal cortex), OCC (occipital cortex); PM (primary motor cortex), Put (putamen), SMC (sensorimotor cortex), STL (superior temporal lobe), SMA (supplementary motor area).

<sup>a</sup> Most patients had cervical dystonia but 5 had segmental dystonia and 1 had generalized dystonia.

<sup>b</sup> Comparison involved symptomatic vs non-symptomatic DYT1 mutation carriers as controls.

<sup>c</sup> Most patients had writer's cramp, but some also had musician's or other focal hand dystonias.

<sup>d</sup> Patients with writer's cramp were studied before and after immobilization therapy.

chin to the other, and at the same time flexed to the side towards which the occiput was directed" (Batten, 1903; Brain, 1926). It is likely that these patients had cervical dystonia, although the term "dystonia" was not typically applied to focal manifestations until decades later (Marsden, 1976).

The associations between mass lesions in the posterior fossa and cervical dystonia have been confirmed in more recent studies combining neuropathology with neuroimaging (Boisen, 1979; Krauss et al., 1997; Kumandas et al., 2006; Turgut et al., 1995). The mass lesions are varied with benign and malignant brain tumors, schwannomas, granulomas, and arachnoid cysts. Stroke and other destructive lesions in the cerebellum are notably uncommon causes of dystonia. The relationship between cervical dystonia and posterior fossa lesions is particularly compelling in cases where dystonia remits after the mass is removed (Krauss et al., 1997; Turgut et al., 1995). The proposed mechanisms for dystonia are not clear and have included distortion of cerebellar function, distortion of proprioceptive signals from the head and neck, and posturing due to pain from meningeal irritation. Whatever the mechanism, it seems clear that at least some forms of dystonia may be linked with lesions affecting the cerebellum or its pathways through the brainstem.

Establishing clinico-pathological correlations is one of the most common methods used in traditional clinical neurology and neuroscience for linking neurological function or dysfunction with their responsible brain regions. It is a time-honored method for which many limitations are recognized. First, conclusions are limited by the resolution of the histologic and microscopic methods applied; more sophisticated methods may reveal more subtle defects. Second, it is impossible to be certain that the histopathological lesion found is responsible for the disorder; other unrecognized defects may play an important role. Third, the secondary downstream responses of a plastic nervous system may be more relevant than the original insult; this issue is particularly relevant since dystonia rarely occurs immediately following a nervous system insult, but rather after a delay of weeks or years. Fourth, the method is biased towards overt structural defects and is insensitive to functional defects; this limitation is particularly important for primary dystonias, where metabolic or physiological changes may be more relevant than structural changes. Finally, establishing clinico-pathological correlations does not prove causation. Demonstrations that some patients with dystonia improve after surgical correction of a lesion, such as a benign tumor, provide some of the most compelling evidence. However, the number of such cases is small, so it is difficult to draw definitive conclusions.

#### *Evidence from human neuroimaging*

##### *Lesion studies*

Although early neuroimaging studies consistently linked dystonia with structural lesions of the basal ganglia, the initial studies were dominated by patients with hemidystonia (Marsden et al., 1985; Pettigrew and Jankovic, 1985). Studies of other forms of dystonia pointed to other regions. For example, Obeso and Gimenez-Roldan described 6 patients with craniofacial dystonia and 3 with cervical dystonia (Obeso and Gimenez-Roldan, 1988). Brainstem lesions were more common than basal ganglia lesions leading these authors to suggest that the location of lesions may vary according to type of dystonia. LeDoux focused specifically on 25 cases of secondary cervical dystonia and found 11 lesions in the brainstem or cerebellum, 6 in the basal ganglia, and 6 in the spinal cord (LeDoux and Brady, 2002). These results confirm that the type of dystonia may be related to the location of underlying lesions, a suggestion consistent with reviews of neuropathological findings (Hedreen et al., 1988; McGeer and McGeer, 1988).

Lesions of the brainstem clearly are associated with dystonia. However, these lesions present many challenges for interpreting the

functional anatomy of dystonia because of the close proximity of multiple regions and fibers of passage (LeDoux and Brady, 2002; Loher and Krauss, 2008; Vidailhet et al., 1999). Vidailhet studied 7 patients with dystonia in association with midbrain/brainstem lesions, noting that lesions spanned several areas including the red nucleus, rubrothalamic tract, and midbrain dopamine neurons or their axonal pathways (Vidailhet et al., 1999). PET studies showing loss of [<sup>18</sup>F]-flurodopa uptake in the basal ganglia indicated that the nigrostriatal pathways were often impacted, raising the possibility that midbrain/brainstem lesions may cause dystonia by destroying inputs to the basal ganglia. Loher and Krauss evaluated 4 patients with midbrain/brainstem lesions of the upper tegmentum and superior cerebellar peduncles where they were unlikely to impact mesotelencephalic dopamine pathways (Loher and Krauss, 2008). They further noted that dystonia may be associated with lesions of the midbrain/brainstem region only rarely because small isolated lesions are uncommon and larger ones cause more serious neurological deficits that overshadow dystonia.

Several other studies have linked dystonia with isolated lesions of the cerebellum or its pathways. For example, 11 of 25 patients with secondary cervical dystonia studied by LeDoux had cerebellar lesions (LeDoux and Brady, 2002). Cerebellar stroke has been associated with hemidystonia (Rumbach et al., 1995), cervical dystonia (Zadro et al., 2008), and paroxysmal dystonia (O'Rourke et al., 2006). A tuberculoma deep in the cerebellar midline has been associated with hemidystonia, which resolved after therapy (Alarcon et al., 2001). There are reports of tumors of the cerebellum among patients with hemidystonia or craniofacial dystonia, where dystonia improved after resection of the mass (Krauss et al., 1997; Persing et al., 1990). In one case, a patient with segmental dystonia improved following removal of a meningioma from the 4th ventricle, and blood flow studies with PET imaging implicated cerebellar dysfunction (Rousseaux et al., 1996).

Multiple structural imaging studies also link limb dystonias with focal lesions of the thalamus (Cho and Samkoff, 2000; Ghika et al., 1994; Kim, 2001; Krystkowiak et al., 1998; Lee and Marsden, 1995; Lehericy et al., 2001, 1996; Miwa et al., 1996). The topography of lesions within the thalamus varies, with some occurring in subnuclei receiving information from the basal ganglia, and others receiving information from the cerebellum. Interestingly, the clinical manifestations of dystonia may vary according to location within the thalamus, with a twisting and writhing quality dominating dystonias involving striatopallidal circuits, and a tremulous or jerky quality dominating those affecting cerebellar circuits (Kim, 2001; Krystkowiak et al., 1998; Lehericy et al., 1996). However, lesions selectively affecting a single thalamic nucleus are rare, as most lesions involve several subnuclei and nearby white matter.

There are multiple reports of patients with secondary dystonia with isolated lesions of the parietal cortex. Included are reports of hand dystonia with contralateral parietal stroke (Burguera et al., 2001), meningioma (Khan and Sussman, 2004), or metastasis (Coria et al., 2000). Parietal lesions also have been associated with cervical dystonia (Kim and Lee, 2007) and Meige syndrome (Jacob and Chand, 1995). One patient with hemidystonia improved after surgical resection of a parietal metastasis (Krauss et al., 1991). Ghika and colleagues characterized the neurological problems in 32 patients with pure parietal strokes and found dystonia in 84% (Ghika et al., 1998). In most of these cases, dystonia has been attributed to faulty processing of sensory information or distortion of perceptions of body positions.

There also are multiple reports of cervical dystonia associated with lesions of the spinal cord. These have been reviewed by Kumandas and colleagues, who noted various combinations of torticollis, laterocollis, retrocollis or anterocollis (Kumandas et al., 2006). The postures have a tonic rather than spasmodic quality, and concomitant tremor is rare. The underlying pathologies were almost invariably located in the cervical spine and included benign and malignant

tumors, granuloma, and syringomyelia. The mechanism is thought to involve local disruption of sensory feedback from neck muscles to the brain, or to distortion of motor signals from the brain to neck muscles.

In summary, a variety of different forms of secondary dystonia is associated with structural lesions in several regions of the nervous system. At first glance, it appears that hemidystonia is most often associated with lesions of the basal ganglia, hand dystonia is most often associated with lesions of the thalamus, and axial dystonias are most often associated with lesions of the cerebellum/brainstem. However, the correspondence between the type of dystonia and brain region is not absolute, since different forms of dystonia can be associated with isolated lesions of different regions. The reasons for the preferential associations of certain types of dystonia with specific regions are not known, but may be related to the proportion of each brain region devoted to movement of different body parts. These regions all are organized topographically with respect to the body, and the relative distribution of body regions in the “homunculus” varies among them.

#### *[<sup>18</sup>F]-fluorodeoxyglucose-PET studies*

Evidence for abnormal brain function also has been obtained from FDG-PET, even among primary dystonias where overt structural lesions are not apparent. The tracer in these studies resembles glucose, which is taken up by different brain regions according to metabolic needs. Since regional metabolism is determined largely by synaptic activity, changes in tracer uptake are thought to correlate with changes in regional neuronal activity.

The most frequently affected regions among the studies reviewed included the cerebral cortex, cerebellum, basal ganglia, thalamus, and midbrain/brainstem (Table 1). A pattern of regional metabolic activity involving the basal ganglia, cerebellum, and supplementary motor cortex was identified in patients with sporadic or DYT1 dystonia (Eidelberg et al., 1998, 1995; Trost et al., 2002), but results are not consistent across different studies. Some of the inconsistencies are attributable to comparing different types of dystonia. For example, Carbon and colleagues directly compared DYT1 and DYT6 dystonia and found opposite patterns of tracer uptake in the putamen (Carbon and Eidelberg, 2009). Studies of blepharospasm also seem to highlight the thalamus and midbrain/brainstem rather than basal ganglia and cortex (Table 1). Thus different types of dystonia may be associated with different metabolic patterns.

#### *PET studies of blood flow*

Alterations in brain activity can be recorded using PET studies of blood flow. Blood flow most often is monitored with [<sup>15</sup>O]H<sub>2</sub>O, although other tracers may also be used. Multiple studies of various forms of dystonia have revealed abnormal activation patterns during performance of various tasks in the cerebral cortex, basal ganglia, cerebellum, and thalamus (Table 2). Different regions of the cortex are most often involved including the primary sensory or motor cortex, motor planning regions of the frontal lobes, but also regions within the posterior parietal and temporal lobes too. Activation changes were observed in patients performing either dystonic (Ceballos-Baumann et al., 1995a; Playford et al., 1998) or non-dystonic movements (Ibanez et al., 1999). During performance of motor tasks, overactivity in the primary and secondary motor cortices was reported frequently, and was interpreted as a correlate of cortical disinhibition (Table 2). However, reduced activation in these regions also was observed (Ibanez et al., 1999). Abnormal sensory processing was reported for focal dystonia (Tempel and Perlmutter, 1990), blepharospasm (Feiwell et al., 1999), and cervical dystonia (Naumann et al., 2000). Compensatory mechanisms may take place before overt clinical manifestations as abnormal activation patterns were observed in non-manifesting DYT1 carriers performing a motor learning task (Carbon et al., 2008a). Lastly, different types of dystonias were associated with different patterns of activation change.

#### *fMRI studies*

Regional changes in the oxygenation level of the blood can be detected with fMRI using blood oxygen level dependent (BOLD) contrast. Results of fMRI are influenced by both blood flow and oxygen use by metabolically active neurons. Its spatial and temporal resolution is superior to PET studies of blood flow. Among the studies reviewed, the most commonly affected regions included various portions of the cerebral cortex, basal ganglia, and cerebellum (Table 3). Most studies reported either normal or increased basal ganglia activation during motor or sensory tasks. In the cortex, activation level was variably altered, depending on the task, the type of dystonia, and whether patients expressed dystonia during task performance. The primary sensory cortex was activated frequently (Dresel et al., 2006; Haslinger et al., 2010; Simonyan and Ludlow, 2010) but not always (Haslinger et al., 2010; Nelson et al., 2009; Oga et al., 2002). Dystonic movements were commonly associated with overactivation in the sensorimotor cortex (Haslinger et al., 2010; Hu et al., 2006; Pujol et al., 2000; Simonyan and Ludlow, 2010), whereas activation levels may be normal (Delmaire et al., 2005) or decreased (Oga et al., 2002) during non-dystonic movements. However, reduced sensorimotor activation also may occur during dystonic movements (Dresel et al., 2006; Haslinger et al., 2005). The abnormal fMRI signals for representation of digits in the primary sensory cortex (Nelson et al., 2009) or other body parts in the basal ganglia (Delmaire et al., 2005) have been interpreted as a loss of neuronal selectivity. Although fMRI presumably monitors neuronal activation, results only partially correlate with PET studies of blood flow (Table 2).

#### *DTI and tractography*

Diffusion-weighted imaging (DWI) is sensitive to the random motion of water molecules, also called Brownian motion. Measures of water diffusivity from DWI provide an estimate of the microstructural integrity of the brain parenchyma. Diffusion tensor imaging (DTI) can also detect the directionality of molecular diffusion. The directionality dependence of diffusion is also called anisotropy and is measured using indices such as fractional anisotropy (FA). This property is mainly observed in brain white matter. The origin of anisotropy is not completely known, but it results from the specific organization of fiber bundles with axons running in parallel. Changes in FA often are interpreted as “microstructural” changes such as changes in axonal amounts, axonal integrity, myelination, or coherence. DTI tractography has also been used to trace specific fiber tracts and to quantify abnormalities along them. DTI tractography uses anisotropy properties, assuming that diffusion predominates along the direction of the tracts. Among the studies reviewed (Table 4), the most commonly affected regions included the cortex, basal ganglia, and cerebellum (or nearby white matter). Additionally three DTI tractography studies revealed abnormalities in the internal capsule or more specifically in cerebello-thalamic or thalamocortical pathways (Argyelan et al., 2009; Bonilha et al., 2009; Delmaire et al., 2009).

#### *Quantitative structural imaging*

An early study described increased putamen volumes in cervical and focal hand dystonias using “region of interest” methods (Black et al., 1998). Evidence for abnormal brain structure also has been obtained from voxel-based morphometry (VBM), which measures structural differences in local composition, voxel by voxel, according to brain tissue type (white matter, gray matter, and cerebrospinal fluid), while discounting large-scale or volumetric differences in global anatomy. This method can be used for making quantitative comparisons of individual region volumes throughout the brain without a priori hypotheses regarding the “regions of interest” that introduce bias in other analyses. The most frequently affected regions among the reported VBM studies of dystonia are the basal ganglia, cortex, thalamus, and cerebellum (Table 5). There is increasing



recognition that different types of dystonia may yield different results (Bradley et al., 2009; Draganski et al., 2009; Pantano et al., 2010).

#### *Summary of human neuroimaging*

The imaging studies are attractive because they point to potential abnormal brain regions in affected patients. They also are valuable for delineating potential abnormalities among the primary dystonias, where overt structural defects are not evident. Overall, it is clear that the imaging studies do not point to a single brain region in dystonia, but rather to a group of brain regions. The many different imaging modalities provide complementary sources of information on different regions. It has been suggested that patterns of covariance among different regions may provide a more relevant measure for dystonia than isolated increases or decreases in a specific region (Carbon and Eidelberg, 2009; Eidelberg et al., 1998; Trost et al., 2002). It also seems increasingly clear that different types of dystonia may reveal different patterns of involvement, which may vary further depending on whether measures are taken at rest or during tasks that trigger dystonia (Carbon et al., 2004b; Draganski et al., 2009; Trost et al., 2002).

The limitations of inferring the anatomic basis of a neurological disorder via clinico-radiographic correlations are similar to those described previously for clinico-pathological correlations. These include the resolution and precision of the methods applied, uncertainties regarding whether abnormalities other than the visible ones are responsible for the disorder, and a bias towards structural vs functional defects. Another limitation is the lack of consistency among different studies. Some of the inconsistencies are attributable to differing technologies. For example, studies measuring metabolism or blood flow are more sensitive to changes in gray matter, while DTI is more sensitive to changes in white matter. However, a lack of concordance sometimes is evident even for modalities that measure a common biological phenomenon such as brain activity (Tables 1–3), or even within a single type of imaging modality (Tables 1–5). The reasons for the inconsistencies are unknown, but may reflect the different and sometimes mixed populations of dystonia patients, relatively small numbers of patients in some studies, use of different reference groups as controls, different effects of baseline on the measured variable, comparisons of resting state vs tasks that induce dystonia, the resolution of the imaging modality, focus on of “regions of interest” vs whole brain studies, measurements of intensity of changes vs extent of changes, differences in regional brain nomenclature, and other methodological differences in data acquisition and analyses.

The more substantial limitation of these studies is that it is difficult to distinguish cause from effect. It seems likely that dysfunction of one brain region responsible for triggering dystonia leads to downstream secondary effects in other regions. The functional imaging methods cannot distinguish the initial dysfunction from downstream consequences, although studies of non-manifesting mutation carriers provide indirect results to infer causation (Carbon et al., 2008a; Draganski et al., 2009). Additionally, it is likely that dystonic movement itself may result in sensory feedback to the brain, resulting in additional changes. The functional imaging methods cannot distinguish the cause of dystonia from its effects. These criticisms apply to both functional and structural imaging studies. Repetitive or highly trained movements are known to cause changes in brain volumes even among normal subjects, raising the possibility that dystonic movements cause changes in brain volumes (Draganski and May, 2008; Granert et al., 2010). Thus changes in brain volumes may be a consequence of dystonic movements rather than a cause, and changes may vary according to the type of dystonia studied.

Because secondary dystonia historically has been associated with defects in the basal ganglia, most imaging studies presume that changes in basal ganglia circuitry reveal causal defects, while those in other regions such as cerebellum are consequential. However, several

imaging studies have revealed patterns of abnormalities that sometimes do not involve the basal ganglia, and some have argued for a causal role of the cerebellum (Argyelan et al., 2009; Delmaire et al., 2007; Hutchinson et al., 2000; Oergren et al., 1998; Thobois et al., 2008). Whatever regions are revealed, the imaging studies do not permit conclusive discrimination of cause from effect.

#### *Evidence from human physiology*

Multiple physiological studies of human dystonia have consistently revealed three common themes: loss of inhibition, impaired sensorimotor integration, and maladaptive neural plasticity.

#### *Loss of inhibition*

A loss of inhibitory processes is observed at multiple levels of the nervous system (Hallett, 2006; Lin and Hallett, 2009). The co-contraction of antagonistic muscles sometimes seen in dystonia is consistent with loss of reciprocal inhibition, which is mediated by the spinal cord. Transcranial magnetic stimulation (TMS) also has revealed loss of cortical inhibition. These abnormalities have been documented for multiple different types of dystonia, both focal and generalized.

Because dystonia historically was linked with dysfunction of the basal ganglia, the loss of inhibition often is interpreted in the context of presumed basal ganglia dysfunction. However, the cerebellum also modulates cortical excitability (Luft et al., 2005). Alterations in cortical excitability following repetitive somatosensory stimulation are mediated by the cerebellum (Daskalakis et al., 2004; Oulad Be Taib et al., 2005), and significant changes of cortical excitability occur with cerebellar degeneration or infarction (Liepert et al., 2004; Tamburin et al., 2004). Finally, transcranial magnetic stimulation of the cerebellum decreases cortical excitability in humans, an effect that is abnormal among patients with dystonia (Borich et al., 2009; Brighina et al., 2008). Currently there is no conclusive evidence linking the loss of inhibition in dystonia with either the basal ganglia or cerebellum, so the contribution of either region remains speculative.

#### *Defects in sensorimotor integration*

A second recurring theme in the physiology of human dystonia involves defects in sensory or perceptual function, or “sensorimotor integration”. Tinazzi recently reviewed multiple psychophysical studies demonstrating deficits in temporal and spatial discrimination (Tinazzi et al., 2009). He also summarized several studies demonstrating abnormalities in the perception of sensory information, such as vibration-induced illusions of movement or central movement representations. These sensory and perceptual abnormalities have been documented for multiple forms of dystonia, including sporadic focal dystonias and inherited generalized dystonias. A potentially related abnormality, disorganized somatotopic representations in the sensorimotor cortex, also has been revealed by both transcranial magnetic stimulation and imaging studies (Bara-Jimenez et al., 1998; Braun et al., 2003; Butterworth et al., 2003; Delmaire et al., 2005; Elbert et al., 1998; Meunier et al., 2001; Nelson et al., 2009).

Again, traditional associations between dystonia and the basal ganglia have led investigators to interpret sensory and perceptual defects in the context of presumed basal ganglia dysfunction. However, there is evidence that the cerebellum also regulates these phenomena. Unlike the basal ganglia that receive sensory information only indirectly, the cerebellum is the direct recipient of sensory input from the spinal cord through the inferior cerebellar peduncles. It processes proprioceptive information, alters somatosensory thresholds in the cortex, and plays a key role in both temporal and spatial discrimination (Pastor et al., 2004; Restuccia et al., 2001). Perlmutter and Thach have pointed out that the cerebellum monitors afferent information from muscle spindles and independently influences drive to spinal cord alpha and gamma motor neurons, providing a potential

mechanism for faulty sensorimotor scaling (Perlmutter and Thach, 2007). At present, there is no direct experimental evidence linking sensory abnormalities with either the basal ganglia or cerebellum, so their contributions remain speculative.

#### Maladaptive neural plasticity

A third theme in the physiology of human dystonia involves neuroplasticity, a phenomenon that refers to the neural processes underlying the brain's ability to adapt to the environment as part of the learning process (Quartarone et al., 2008, 2006; Rothwell and Huang, 2003). Although plasticity is a normal property of the nervous system, maladaptive plasticity could occur as a result of intrinsic defects in plasticity mechanisms, or from breakdown of these mechanisms by "over-training". Abnormal plasticity has been demonstrated for several different types of dystonia, typically using protocols that involve transcranial magnetic stimulation of the motor cortex.

Traditional views of the importance of the basal ganglia in dystonia again have led many investigators to interpret maladaptive plasticity in the context of presumed basal ganglia dysfunction (Quartarone et al., 2008, 2006; Rothwell and Huang, 2003), perhaps related to striatal dopamine systems (Peterson et al., 2010). However, the evidence is indirect and it is well known that the cerebellum also plays a critical role in motor learning and plasticity (Doya, 2000; Thompson and Steinmetz, 2009). Recently, Teo and colleagues found the conditioned eyeblink reflex to be abnormal in patients with focal dystonia (Teo et al., 2009). This reflex is mediated exclusively by the cerebellum, indicating abnormal cerebellar neuroplasticity in dystonia. Another study showed that the ability of transcranial magnetic stimulation of the cerebellum to modulate plasticity in the motor cortex was abnormal in patients with focal dystonia (Brighina et al., 2008), while another showed that transcranial magnetic stimulation of the cerebellum reduced the severity of hand dystonia (Borich et al., 2009). Finally, there is evidence from studies of rats that the cerebellum controls corticostriatal long-term depression, the physiological mechanism thought to underlie neural plasticity (Rossi et al., 2008). These observations suggest that ascribing abnormal plasticity to one neural system is over-simplistic.

The physiological abnormalities described above are enticing because they address systems-level phenomena of direct relevance to patients with dystonia, and because three themes have consistently emerged after investigations of multiple different types of dystonia by multiple groups. The main limitation of commonly applied physiological methods for localization of functional anatomy of dystonia is that they reflect an emergent property of interactions among many brain regions in the intact human brain, making it challenging to distinguish cause from effect. The abnormalities described may reflect a core defect underlying a predisposition to develop dystonia, a downstream consequence of the motor disorder, or even a phenomenon of little relevance (epiphenomenon).

Some authors have argued these physiological abnormalities are a cause rather than an effect because they can be detected from unaffected body regions among patients with focal dystonia and from both sides of

the brain even when dystonia is limited to one side. Unfortunately, these arguments are undermined by multiple studies showing that operations of one side of the body have bilateral influences on the brain, and by evidence that motor activity can alter sensory thresholds and other physiological measures from the brain (Carroll et al., 2006; Page et al., 2009; Waberski et al., 2007) that are used to probe the physiology of dystonia.

#### Associations of dystonia with other clinical disorders

In addition to its frequent associations with Parkinsonism and chorea, dystonia also is frequently associated with tremor and ataxia. While Parkinsonism and chorea originate with dysfunction of the basal ganglia, tremor and ataxia are linked with dysfunction of the cerebellum.

Tremor is the most common associate of dystonia. Tremor has been reported for 28–68% of patients with dystonia, depending on the definition of tremor and the methods used to identify it (Chan et al., 1991; Dubinsky et al., 1993; Jankovic et al., 1991; Pal et al., 2000; Rondot et al., 1991; Valls-Sole et al., 1997). Tremor occurs frequently in many forms of dystonia including primary dystonia, dystonia-plus syndromes, and development or degenerative dystonias. In fact, tremor is so common that it is allowed in definitions of otherwise "pure" or primary dystonia. At least two different tremor-like movements occur in dystonia: a large-amplitude irregular tremor that is often called "dystonic" tremor, and a smaller amplitude sinusoidal tremor that resembles the tremor of essential tremor.

Several investigators have argued the high-frequency sinusoidal tremor is identical with that of essential tremor (Jankovic et al., 1991; Pal et al., 2000; Valls-Sole et al., 1997). Evidence in support of this view includes several phenomenological similarities between this tremor and essential tremor including frequency, amplitude, regular tempo, and sinusoidal morphology. Additional evidence includes therapeutic responses to anti-tremor medications such as propranolol, a high prevalence of essential tremor in family members of dystonia probands, and clustering of dystonia and tremor in families suggesting they may arise from the same genetic defect (Hedera et al., 2010). Essential tremor is thought to originate from dysfunction of cerebellar circuitry, implying that patients with tremor and dystonia may have cerebellar dysfunction.

Dystonia also is frequently associated with other disorders classically associated with cerebellar dysfunction including Friedreich ataxia, ataxia telangiectasia, and many of the spinocerebellar ataxias (Table 6). For nearly all of these cerebellar disorders, there also are multiple reports of occasional patients where dystonia rather than ataxia is a presenting or dominating clinical feature (Bodensteiner et al., 1980; Goyal and Behari, 2002; Hagenah et al., 2004; Hess et al., 2010; Munchau et al., 1999; Muzaimi et al., 2003; Sethi and Jankovic, 2002; Wilder-Smith et al., 2003; Wu et al., 2004). There also are several reports suggesting a distinct nosological entity of very slowly progressive adult-onset focal or segmental dystonia with severe cerebellar atrophy

**Table 6**  
Dystonia in cerebellar disorders.

Disorder	Total cases	Total with dystonia	Percent with dystonia	Source
Ataxia-telangiectasia	83	63	75.9	(Verhagen et al., 2009; Woods and Taylor, 1992)
Friedreich ataxia	71	15	21.1	(Garcia-Ruiz et al., 1992; Schols et al., 2000)
Ataxia with oculomotor apraxia	90	12	13.5	(Anheim et al., 2009)
SCA1	45	3	6.7	(Dragasevic et al., 2006; Schols et al., 2000)
SCA2	148	31	20.9	(Boesch et al., 2007; Cancel et al., 1997; Dragasevic et al., 2006; Schols et al., 2000)
SCA3	149	25	16.8	(Garcia-Ruiz et al., 1992; Jardim et al., 2001; Schols et al., 2000)
SCA6	84	16	19.0	(Garcia-Ruiz et al., 1992; Ikeuchi et al., 1997; Schols et al., 2000)

This table was compiled from selected studies wherein the nature of the movement disorder was systematically profiled for relatively large numbers of patients. It does not include case reports or small series of patients.

(Fletcher et al., 1988; Jinnah and Hess, 2006; Kuoppamaki et al., 2003; Le Ber et al., 2006). Thus dystonia is common in “cerebellar” disorders. The frequency of dystonia in cerebellar disorders is likely to be underestimated, since there are few prospective studies addressing the co-occurrence of dystonia and ataxia. Additionally, many dystonic movements are given alternative designations in ataxia clinics such as “dyskinesia”, “extrapyramidal disturbances”, “cramps”, “posturing”, or “sway”. For example, the truncal distortion in Friedreich's ataxia is most commonly labeled “scoliosis” even though it probably reflects truncal dystonia (Hou and Jankovic, 2003).

There are obvious limitations of the method of “guilt by association” where specific brain regions are linked with dystonia by association with other disorders. The main limitation is that dysfunction in “cerebellar” disorders may not be limited to the cerebellum. For example, degenerative changes in SCA3 and related disorders may occur in several brain regions and is not limited to the cerebellum. The evidence is most compelling for disorders where pathology is thought to be restricted to the cerebellum, such as SCA6, although microstructural and functional defects outside the cerebellum cannot be ruled out.

#### *Evidence from neurosurgery*

Most of the recent neurosurgical literature has focused on DBS of the internal pallidum in dystonia (Marks, 2007; Ostrem and Starr, 2008; Perlmutter and Mink, 2006). It is clear that some forms of dystonia consistently respond well, while other forms do not. These differences may be due to etiological heterogeneity among different dystonias, with differing functional anatomy. There is an extensive older neurosurgical literature that focused on regions outside the basal ganglia, where again a marked variation was observed in therapeutic responses. This literature often is overlooked because the term “dystonia” was not always used. More commonly used were terms such as “athetosis”, “dyskinesia”, “hypertonia”, or “cerebral palsy”. However, there is good evidence that many of the patients in these early reports had dystonia, as the original clinical descriptions described patients with twisting, writhing, and co-contraction.

The thalamus was an early target to be explored by neurosurgeons (Krack and Vercueil, 2001; Rosenow et al., 2002; Vercueil, 2003). Cooper described the largest series, with thalamotomies in 226 dystonia patients operated between 1955 and 1974 (Cooper, 1976). He targeted several regions in the thalamus, sometimes in a staged approach. He initially ablated pallidal relays in the ventrolateral thalamus, and if the response was not satisfactory, he ablated the cerebellar relays too. Benefits were sometimes dramatic, but inconsistent. The inconsistencies were not surprising, considering that precise neuroimaging was not available, and the importance of etiological heterogeneity was not yet well appreciated. Historical assessments have revealed that the potential benefits of Cooper's work were clouded by his tendency to publish positive case reports rather than objective comparisons, his frequent variation in technique, and his bold and sometimes theatrical personality (Vercueil, 2003). However, thalamotomy and DBS of the thalamus are advocated for specific populations even today. Effective targets still include both the pallidal and cerebellar receiving fields. Although formal studies comparing these targets have never been done, anecdotal observations and small case series suggest the preferred target may vary with different populations (Fukaya et al., 2007; Goto et al., 2008; Morishita et al., 2010).

Noting that some patient populations did not respond well to thalamotomies, several neurosurgeons focused on the cerebellum. The interest in the cerebellum was driven by observations of Sherrington and others that the cerebellum exerted powerful control over muscle tone in the decerebrate cat. Several surgeons have noted dystonic movements among humans following stimulation of the dentate nucleus (Nashold and Slaughter, 1969), or the cerebellar receiving area of the thalamus (Lenz et al., 1990). Others reported that a variety of dyskinetic movements may improve following ablation or DBS of the dentate

nucleus, or superficial stimulation of the cerebellar cortex (Davis, 2000; Hitchcock, 1973). Benefits were dramatic in some but absent in others, and often delayed by many weeks, similar to the effects of pallidal DBS. The inconsistencies were likely due to technical variations and etiological heterogeneity in mixed dystonia populations. The mechanisms by which surgical interventions in the cerebellum might improve dystonic movements remain unclear. Some investigators have postulated a mechanism relating to reduced cortical excitability, while others postulated changes in proprioceptive feedback. Cerebellar ablations or stimulation rarely are advocated as treatments for dystonia today, because prior results were inconsistent, and the scarcity of objective measures led to questions regarding claimed improvements.

In addition to the targets noted above, there is literature supporting the interstitial nucleus of Cajal (INC) as a viable target for cervical dystonia. Multiple investigators have shown that stimulation or destruction of the INC results in characteristic abnormalities of head control in cats and monkeys that resemble those of people with cervical dystonia, and several neurosurgeons have reported beneficial effects of lesioning the INC and nearby structures among patients with cervical dystonia (Farshadmanesh et al., 2007; Goldhahn and Goldhahn, 1977; Klier et al., 2002, 2007; Loher et al., 2004; Sano et al., 1972; Stejskal et al., 1981; Vasin et al., 1985). The INC is proposed to serve as a center for control of head/neck posture, so it is not a logical target for other dystonic disorders.

The neurosurgical literature provides clear evidence that dystonic movements can be attenuated via interventions in multiple brain regions including the basal ganglia, thalamus, cerebellum, and INC. The main limitation to inferring the functional anatomy of dystonia from this evidence is that it is difficult to determine if the region in question is the source of the problem or part of downstream pathways that permit the problem to occur. For example, the spinal cord is not considered the source of all motor and sensory functions, even though spinal cord lesions may interrupt both. The delayed therapeutic effects associated with interventions involving the basal ganglia or cerebellum argue that subsequent reorganization of neural function is important. This plasticity often is assumed to be occurring within the basal ganglia, but it may also occur in distant regions. In fact, the effect of pallidal DBS on regional blood flow provides evidence for distant reorganization, as obvious changes are detectable in the cerebral cortex, cerebellum, and elsewhere (Detante et al., 2004; Thobois et al., 2008; Yianni et al., 2005). Additional limitations of the neurosurgical literature include the application of multiple terms that differ from conventional agreements (e.g. hypertonia or dyskinesia) making it difficult to know what is being treated, the lack of objective measures and study designs to document effects, the small numbers of patients in many reports, and technical uncertainties regarding methods and regions targeted.

#### *Evidence from animal models*

The human studies are valuable because they provide evidence of direct relevance to affected patients. However, they provide largely correlative evidence regarding the functional neuroanatomy of dystonia, because the types of studies required for proving causation cannot be done in human subjects. In this setting, animal models can be particularly valuable for testing hypotheses regarding potential neuroanatomical substrates (Hess and Jinnah, 2005; Jinnah et al., 2005).

A widely used approach for identifying potential neuroanatomical substrates for dystonia has involved investigating animals for dystonic-appearing movements after focal ablations of brain tissue or microinjection of pharmacological inhibitors or stimulants. Dystonic-appearing movements have been elicited from a wide variety of species (rodents, cats, primates) and a wide variety of regions (cortex, basal ganglia, cerebellum, thalamus, midbrain, and INC) over many years. The earliest literature described the phenomenology of movements without labeling them as dystonic, and the interpretation often was that they were exaggerations of normal movement. More recent studies describe the resulting movements as dystonic, but the movements often are not



sufficiently characterized to exclude potential mimics. These studies will not be reviewed here because of uncertainties regarding the nature of the movements.

Another approach for identifying anatomical substrates has involved examining the brains of animals with spontaneous dystonic-appearing movements. One of the first to be studied was the dystonic (*dt*) rat, which exhibits abnormal movements with both clinical and electromyographic hallmarks of generalized dystonia (Lorden et al., 1984). It carries a defect in the *Atcay* gene, which encodes caytaxin that is expressed at high levels in the cerebellum (Xiao and Ledoux, 2005). Metabolic mapping and electrophysiological studies have shown abnormal activity of the cerebellum, leading to the hypothesis that the cerebellum is responsible for dystonia (Beales et al., 1990; LeDoux et al., 1998; Lorden et al., 1992). In fact, surgical removal of the entire cerebellum or focal lesions of the deep cerebellar nuclei eliminate dystonic movements and replace them with ataxia (LeDoux et al., 1993, 1995). These results suggest a cerebellar origin for dystonia in this model.

Another model has been the tottering mutant mouse, which has clinical and electromyographic features resembling human paroxysmal dystonia (Scholle et al., 2010; Shirley et al., 2008). This model carries a mutation in the *Cacna1a* gene, which encodes a calcium channel that is widely expressed in the brain (Fletcher et al., 1996). Different mutations in this gene among humans are associated with a variety of neurological disorders including hemiplegic migraine, episodic ataxia type 2, spinocerebellar ataxia type 6, seizures, or dystonia (Benarroch, 2010; Hess et al., 2010). Similar to the situation in humans, different mutations in mice and rats also cause a variety of disorders in different models including paroxysmal or generalized dystonia, ataxia, and seizures (Fletcher et al., 2001; Miki et al., 2008; Raike et al., 2005; Shirley et al., 2008; Tokuda et al., 2007; Xie et al., 2007). The tottering mouse has provided a powerful tool for delineating the functional anatomy of dystonia, because dystonia occurs in discrete episodes on a normal baseline, making it possible to compare changes in the brain at baseline and during a dystonic attack.

Cerebellar Purkinje neurons were implicated as a source of dystonia in tottering mice by mapping the time course of brain activation during an attack, which showed early activation of cerebellar Purkinje and deep cerebellar neurons followed by activation of the red nucleus, thalamus, and cortex (Campbell and Hess, 1998). Like the *dt* rat model, surgical removal of the cerebellum eliminated their dystonic attacks, suggesting the cerebellum was the source of the problem (Neychev et al., 2008). In fact, selective elimination of Purkinje neurons by cross-breeding tottering mice with another mouse line in which these neurons degenerate also eliminated their dystonia, suggesting involvement of a single neuronal population (Campbell et al., 1999). The nature of the defect in these neurons remains to be determined, although preliminary studies have suggested increased burst-firing patterns (Chen et al., 2009). These findings lead to the proposal that dystonia originating from the cerebellum in this model may reflect an increase in neuronal activity rather than a loss of activity.

This proposal has been confirmed in studies showing that pharmacological excitation of the cerebellum by local microinjection of the excitatory amino acid agonist kainic acid even in normal mice acutely evokes movements that bear clinical and electrophysiological hallmarks of human dystonia (Pizoli et al., 2002). However, other stimulants do not have the same effects, suggesting that the manner in which cerebellar output is altered is important for causing dystonia. Although the mechanisms are not yet fully understood, these observations demonstrate that dystonic movements may be elicited by functional disturbances in an otherwise structurally normal brain.

The animal studies are valuable because specific hypotheses can be verified experimentally in a rigorously controlled manner to establish causation. There are two main weaknesses of the animal studies. The first is that many animal studies describe “dystonia” with limited description of the nature of the abnormal movements, no quantitative measures, or no effort to exclude potential mimics. The relevance of

such studies therefore is uncertain. This limitation can be addressed by careful description of the movements with videotape documentation, together with appropriate physiological tests such as electroencephalography or electromyography to exclude other disorders (Jinnah et al., 2005). Another limitation of the animal studies is that results may be species-specific and not relevant to humans. This seems unlikely, since the internal organization and extrinsic connections of the major motor pathways are similar in most mammals, except for variations in the relative size and importance of different pathways. This limitation can be addressed by attempting to replicate findings in rodents with higher mammals such as primates.

### A revised model for the functional anatomy of dystonia

The accumulating evidence reviewed above renders traditional models that focus on basal ganglia circuits as the central cause for all forms of dystonia obsolete. It is becoming increasingly clear that many brain regions contribute to dystonia, including the cerebral cortex, cerebellum, thalamus, and midbrain/brainstem. It also is becoming increasingly clear that etiological heterogeneity among dystonias is important, as the relative importance of different brain regions seems to vary among them. Current challenges are to develop a model for understanding physiological interactions for how the different brain regions may contribute to different forms of dystonia, whether different dystonias can be subdivided into subgroups depending on how these regions are affected, and whether there is a final common pathway for all dystonias.

#### The network model

Previously we suggested that a “network model” may better accommodate more of the available evidence than models that focus on basal ganglia dysfunction as the sole cause (Jinnah and Hess, 2006). This network model is not entirely new; prior studies had recognized involvement of multiple brain regions (Carbon and Eidelberg, 2009; Eidelberg et al., 1998, 1995). What is new is a shift away from traditional belief that the basal ganglia always are the cause of dystonia. This revised model accommodates the possibility that dystonia may result from dysfunction of other nodes in the network, from combined dysfunction of multiple nodes, or from aberrant communication among the nodes. Which of these possibilities best applies to dystonia remains unclear, and there is evidence that supports each. For example, dystonias that arise from focal lesions involving individual nodes argue that dysfunction of a single node can cause dystonia. However, the loose correlations between focal lesions and dystonia, and the delays between the lesion and emergence of dystonia raise the possibility that maladaptive reorganization in distant nodes may be important too. There also is evidence that dystonia arises from simultaneous abnormal function of multiple nodes. An example is the two-hit rat model for blepharospasm, where combining partial injury to nigral neurons with abnormal proprioceptive feedback from weakened orbicularis oculi muscles results in blepharospasm, when neither abnormality alone is sufficient (Schicatanò et al., 1997). Focal defects in the thalamus may provide an example of defects involving communication among nodes, since this is a region where pallidal and cerebellar afferents may communicate before relaying to the cortex.

The available evidence suggests further that the nature of defects in individual nodes may vary. For example, destructive lesions such as stroke cause dystonia when they occur in the basal ganglia or thalamus. However, destructive lesions in the cerebellum rarely cause dystonia. Instead, destructive cerebellar lesions more often cause ataxia. One possible explanation for this difference is that the types of lesions affecting the cerebellum cause a distortion or increase in Purkinje neuron activity rather than a loss of activity. Indeed, Batten postulated a difference between “irritative” and “paralytic” cerebellar lesions in relation to cervical dystonia more than 100 years ago



(Batten, 1903). This proposal is supported by animal studies of dystonia, implying increased cerebellar activity rather than loss of activity (Chen et al., 2009; LeDoux et al., 1998; Pizoli et al., 2002). It also is supported by observations that the preponderance of lesions causing dystonia in the cerebellum involves space-occupying lesions such as tumors, where they are more likely to distort output than eliminate it. Dystonia associated with degenerative cerebellar disorder may reflect abnormal activity of cerebellar neurons during a lengthy agonal period before death.

### Integrating function and dysfunction

The network model requires that the various nodes in the proposed network communicate at some level. Despite decades of research, the means by which normal motor functions are handled by brain subregions involved with motor control such as the basal ganglia and cerebellum remain uncertain (Mano et al., 1993). Traditionally, the basal ganglia are thought to play a role in the selection and inhibition of motor commands, while the cerebellum plays a role in tuning ongoing movement. Though the functions of these regions are often addressed separately for heuristic reasons, normal motor behavior requires seamless integration.

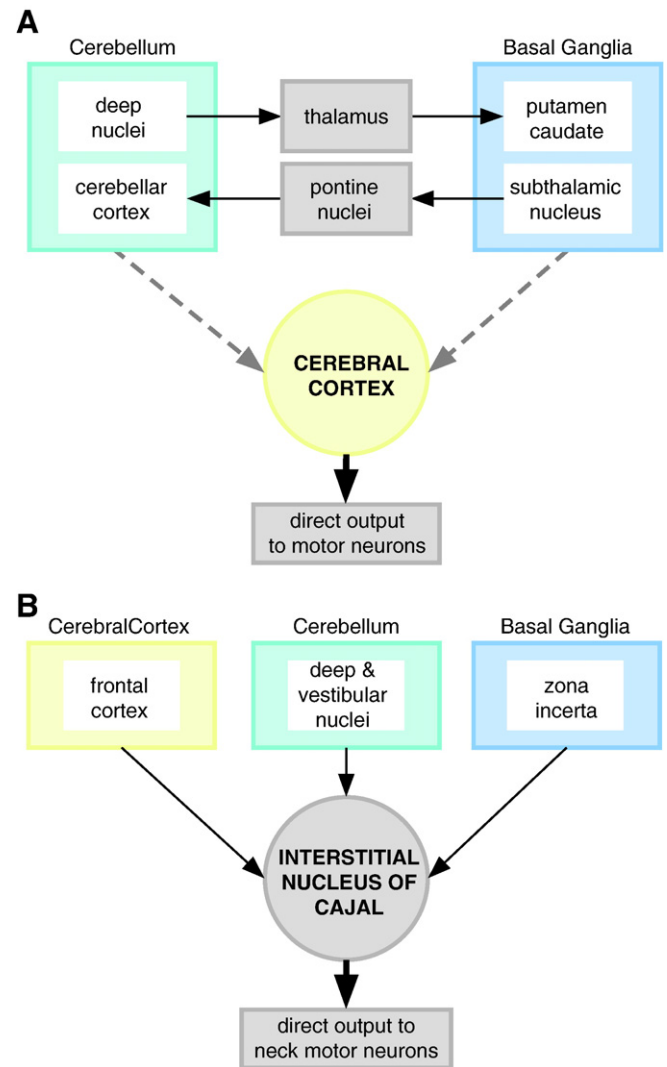
The mechanisms responsible for communication have not been fully elucidated, though several possibilities exist. The traditional view is that the basal ganglia and cerebellum communicate via distinct thalamic relays to the cortex, where final motor output is organized (Bostan and Strick, 2010). However, subcortical pathways of communication linking basal ganglia and cerebellum have been identified by tract tracing studies in both rodents and non-human primates. In rats, the lateral deep cerebellar nucleus projects to the dorsolateral striatum via the central lateral nucleus of the thalamus (Ichinohe et al., 2000). In primates, the dentate and interpositus deep cerebellar nuclei project via disynaptic or trisynaptic pathways involving thalamus to the putamen or external segment of the globus pallidus (Hoshi et al., 2005; McFarland and Haber, 2000). Anatomical studies in rats and cats also suggest a pathway from deep cerebellar nuclei to nigrostriatal dopamine neurons (Snider et al., 1976). Finally, there is a return pathway from basal ganglia to cerebellum (Bostan et al., 2010). Thus there is ample evidence that the basal ganglia and cerebellum are anatomically interconnected, providing pathways whereby the function (or dysfunction) of one region may influence another region without involving the cerebral cortex (Bostan and Strick, 2010).

The functional significance of anatomical pathways between the basal ganglia and cerebellum is evident in changes in striatal dopamine release caused by stimulation or lesions of the mouse cerebellum (Neychev et al., 2008). Unilateral electrical stimulation of the cat deep cerebellar nuclei also increases dopamine turnover in the contralateral striatum (Nieoullon et al., 1978). Conversely, unilateral electrolytic lesions of the deep cerebellar nuclei in rats reduce contralateral striatal dopamine turnover (Tellerman et al., 1979). These interactions between cerebellar and nigrostriatal function are not limited to animals. Tranchant and colleagues described a woman with torticollis in association with a hemangioma within the cerebellum (Tranchant et al., 1991). FDG-PET revealed marked hypometabolism of the basal ganglia, suggesting that a focal lesion in the cerebellum can have distant effects in the basal ganglia. These studies provide functional evidence for communications between the cerebellum and basal ganglia. The concept that the basal ganglia and cerebellum cooperate in the expression of motor disorders is not new, as others have proposed that the tremor in Parkinson's disease reflects cerebello-thalamic dysfunction (Stein and Aziz, 1999).

We recently explored the network model in animals (Neychev et al., 2008). In normal mice treated with pharmacological excitation of the cerebellum or mutant tottering mice, abnormal cerebellar activity drives dystonic movements. Surprisingly, superimposed subclinical basal ganglia lesions exaggerate the dystonic movements in these "cerebellar" models, implying that the basal ganglia participate in the generation in abnormal movements even when the primary defect originates in the

cerebellum. These findings could suggest that the basal ganglia may normally filter out or suppress abnormal movements generated via the cerebellum in these models, providing experimental support for the filtering model of basal ganglia defects in dystonia.

It generally is assumed that the final common pathway for motor processing in the basal ganglia and cerebellum proceeds through the cerebral cortex (Fig. 1A). Other nodes in the network may cause dystonia via their influence on the cortex, or abnormalities may arise directly from the cortex. However, some types of movement, such as basic reflexes or postural control, may not require cortical involvement, raising the possibility that the cortex may not be required as the final common pathway for all dystonias. The most obvious potential example is



**Fig. 1.** Schematic representation of anatomical substrates for dystonia. Panel A shows the most commonly assumed model that involves defects in subcortical pathways of the basal ganglia or cerebellum being transmitted through the cerebral cortex for final expression of dystonia. Panel A also shows the recently appreciated subcortical communications between the basal ganglia and cerebellum (modified from Bostan and Strick, 2010). This schematic has been simplified and does not show all known connections. Solid lines depict well-established direct pathways, and dashed lines depict established pathways involving one or more connections to reach target. Panel B shows an alternative schematic whereby cervical dystonia may be expressed directly through subcortical pathways, such as the interstitial nucleus of Cajal (INC). In this pathway, the cerebral cortex may contribute to the expression of cervical dystonia but the INC is the final common pathway with direct connections to neck motor neurons (modified from Fukushima, 1987). These two schematics provide two examples of how pathways may differ according to type of dystonia, and how they may not require involvement of the cerebral cortex.

involvement of the INC in cervical dystonia (Fig. 1B). The INC has been proposed to serve a central role in the control of head movements by integrating afferents from the cortex, cerebellum, vestibular system, and basal ganglia through zona incerta (Fukushima, 1987). It has direct efferents to motoneurons of the cervical spinal cord, placing it in a position where it could directly disrupt head control without involvement of the cerebral cortex. Indeed, pharmacological and electrophysiological manipulations of this region provoke abnormalities of head control resembling cervical dystonia (Farshadmanesh et al., 2007; Goldhahn and Goldhahn, 1977; Klier et al., 2002, 2007; Loher et al., 2004; Sano et al., 1972; Stejskal et al., 1981; Vasin et al., 1985). If abnormalities in this region can directly provoke cervical dystonia, then abnormalities of the cortex found in physiological or imaging studies may be compensatory or epiphenomenal.

## Conclusions

The localization of function and dysfunction in the nervous system is a core part of neuroscience and clinical neurology. Although the traditional view localizes dystonia to basal ganglia circuits, there is increasing recognition that this view is inadequate for accommodating a substantial portion of available clinical and experimental evidence. Unfortunately, there has been a tendency to dismiss experimental findings that do not fit the prevailing traditional view. Rather than dismiss experimental results, it is increasingly recognized that it may be time to dismiss the traditional view. A model in which several brain regions play a role in a network better accommodates the available evidence. With the revised network model, many awkward and apparently conflicting observations can be reconciled. This model better accommodates neuropathological and neuroimaging evidence that dystonia may be associated with abnormalities in multiple different brain regions. It also better accommodates animal studies showing that dystonic movements arise with manipulations of different brain regions. It is consistent with neurophysiological evidence suggesting defects in neural inhibitory processes, sensorimotor integration, and maladaptive plasticity. Finally, it may explain neurosurgical evidence showing that targeting the basal ganglia is effective only for certain subpopulations of dystonia.

The best experimental models are those that go beyond accommodating existing evidence. They also should guide the development of testable hypotheses that advance our understanding of the disorder being modeled. The revised network model is likely to stimulate further investigations into potential causal roles of regions other than the basal ganglia in dystonia, a more sophisticated understanding of cause and effect in imaging and physiological studies, a more targeted and useful application for animal models, further exploration of the “two-hit” concept in dystonia, and especially novel intervention strategies. As new data accumulate to confirm or refute the revised model and provide a more sophisticated understanding of dystonia, the model will be inevitably revised again, or perhaps replaced entirely.

## Acknowledgments

Supported in part by grants from the NIH Office of Rare Diseases Research and the National Institutes of Neurological Disorders & Stroke (NS033592, NS040470, NS967501).

## References

Alarcon, F., et al., 2001. Focal limb dystonia in a patient with a cerebellar mass. *Arch. Neurol.* 58, 1125–1127.

Ali, S.O., et al., 2006. Alterations in CNS activity induced by botulinum toxin treatment in spasmodic dysphonia: an H2150 PET study. *J. Speech Lang. Hear. Res.* 49, 1127–1146.

Anheim, M., et al., 2009. Ataxia with oculomotor apraxia type 2: clinical, biological and genotype/phenotype correlation study of a cohort of 90 patients. *Brain* 132, 2688–2698.

Argyelan, M., et al., 2009. Cerebellothalamocortical connectivity regulates penetrance in dystonia. *J. Neurosci.* 29, 9740–9747.

Asanuma, K., et al., 2005a. Neuroimaging in human dystonia. *J. Med. Investig.* 52, 272–279.

Asanuma, K., et al., 2005b. The metabolic pathology of dopa-responsive dystonia. *Ann. Neurol.* 57, 596–600.

Bara-Jimenez, W., et al., 1998. Abnormal somatosensory homunculus in dystonia of the hand. *Ann. Neurol.* 44, 828–831.

Batten, F.E., 1903. On the diagnostic value of the position of the head in cases of cerebellar disease. *Brain* 26, 71–80.

Beales, M., et al., 1990. Quantitative autoradiography reveals selective changes in cerebellar GABA receptor of the rat mutant dystonic. *J. Neurosci.* 10, 1874–1885.

Benarroch, E.E., 2010. Neuronal voltage-gated calcium channels: brief overview of their function and clinical implications in neurology. *Neurology* 74, 1310–1315.

Berardelli, A., et al., 1998. The pathophysiology of primary dystonia. *Brain* 121, 1195–1212.

Beukers, R.J., et al., 2010. Disorganized sensorimotor integration in mutation-positive myoclonus-dystonia: a functional magnetic resonance imaging study. *Arch. Neurol.* 67, 469–474.

Bhatia, K.P., Marsden, C.D., 1994. The behavioral and motor consequences of focal lesions of the basal ganglia in man. *Brain* 117, 859–876.

Black, K.J., et al., 1998. Putamen volume in idiopathic focal dystonia. *Neurology* 51, 819–824.

Blood, A.J., et al., 2004. Basal ganglia activity remains elevated after movement in focal hand dystonia. *Ann. Neurol.* 55, 744–748.

Bodensteiner, J.B., et al., 1980. Progressive dystonia masking ataxia in ataxia-telangiectasia. *Arch. Neurol.* 37, 464–465.

Boesch, S.M., et al., 2007. Cervical dystonia in spinocerebellar ataxia type 2: clinical and polymyographic findings. *J. Neurol. Neurosurg. Psychiatry* 78, 520–522.

Boisen, E., 1979. Torticollis caused by an infratentorial tumour: three cases. *Br. J. Psychiatry* 134, 306–307.

Bonilha, L., et al., 2007. Structural white matter abnormalities in patients with idiopathic dystonia. *Mov. Disord.* 22, 1110–1116.

Bonilha, L., et al., 2009. Disrupted thalamic prefrontal pathways in patients with idiopathic dystonia. *Parkinsonism Relat. Disord.* 15, 64–67.

Borich, M., et al., 2009. Lasting effects of repeated rTMS application in focal hand dystonia. *Restor. Neurol. Neurosci.* 27, 55–65.

Bostan, A.C., Strick, P.L., 2010. The cerebellum and basal ganglia are interconnected. *Neuropsychol. Rev.* 20, 261–270.

Bostan, A.C., et al., 2010. The basal ganglia communicate with the cerebellum. *Proc. Natl. Acad. Sci. USA* 107, 8452–8456.

Bradley, D., et al., 2009. Temporal discrimination threshold: VBM evidence for an endophenotype in adult onset primary torsion dystonia. *Brain* 132, 2327–2335.

Brain, W.R., 1926. On the rotated or “cerebellar” posture of the head. *Brain* 49, 61–76.

Braun, C., et al., 2003. Task-specific plasticity of somatosensory cortex in patients with writer’s cramp. *Neuroimage* 20, 1329–1338.

Breakefield, X.O., et al., 2008. The pathophysiological basis of dystonias. *Nat. Rev. Neurosci.* 9, 222–234.

Bressman, S.B., 2003. Dystonia: phenotypes and genotypes. *Rev. Neurol.* 159, 849–856.

Brighina, F., et al., 2008. Effects of cerebellar TMS on motor cortex of patients with focal dystonia: a preliminary report. *Exp. Brain Res.* 192, 651–656.

Burguera, J.A., et al., 2001. Action hand dystonia after cortical parietal infarction. *Mov. Disord.* 16, 1183–1185.

Burns, L.H., et al., 1995. Selective putaminal excitotoxic lesions in non-human primates model the movement disorder of Huntington disease. *Neuroscience* 64, 1007–1017.

Butterworth, S., et al., 2003. Abnormal cortical sensory activation in dystonia: an fMRI study. *Mov. Disord.* 18, 673–682.

Campbell, D.B., Hess, E.J., 1998. Cerebellar circuitry is activated during convulsive episodes in the tottering (tg/tg) mutant mouse. *Neuroscience* 85, 773–783.

Campbell, D.B., et al., 1999. Tottering mouse motor dysfunction is abolished on the Purkinje cell degeneration (pcd) mutant background. *Exp. Neurol.* 160, 268–278.

Cancel, G., et al., 1997. Molecular and clinical correlations in spinocerebellar ataxia 2: a study of 32 families. *Hum. Mol. Genet.* 6, 709–715.

Carbon, M., Eidelberg, D., 2009. Abnormal structure–function relationships in hereditary dystonia. *Neuroscience* 164, 220–229.

Carbon, M., et al., 2004a. Microstructural white matter changes in carriers of the DYT1 gene mutation. *Ann. Neurol.* 56, 283–286.

Carbon, M., et al., 2004b. Regional metabolism in primary torsion dystonia: effects of penetrance and genotype. *Neurology* 62, 1384–1390.

Carbon, M., et al., 2007. Increased cerebellar activation during sequence learning in DYT1 carriers: an equiperformance study. *Brain* 131, 146–154.

Carbon, M., et al., 2008a. Increased cerebellar activation during sequence learning in DYT1 carriers: an equiperformance study. *Brain* 131, 146–154.

Carbon, M., et al., 2008b. Microstructural white matter changes in primary torsion dystonia. *Mov. Disord.* 23, 234–239.

Carbon, M., et al., 2010. Increased sensorimotor network activity in DYT1 dystonia: a functional imaging study. *Brain* 133, 690–700.

Carroll, T.J., et al., 2006. Contralateral effects of unilateral strength training: evidence and possible mechanisms. *J. Appl. Physiol.* 101, 1514–1522.

Ceballos-Baumann, A.O., et al., 1995a. Motor reorganization in acquired hemidystonia. *Ann. Neurol.* 37, 746–757.

Ceballos-Baumann, A.O., et al., 1995b. Overactive prefrontal and underactive motor cortical areas in idiopathic dystonia. *Ann. Neurol.* 37, 363–372.

Ceballos-Baumann, A.O., et al., 1997. Botulinum toxin does not reverse the cortical dysfunction associated with writer’s cramp. A PET study. *Brain* 120, 571–582.

Chan, J., et al., 1991. Idiopathic cervical dystonia: clinical characteristics. *Mov. Disord.* 6, 119–126.

Chen, G., et al., 2009. Low-frequency oscillations in the cerebellar cortex of the tottering mouse. *J. Neurophysiol.* 101, 234–245.

Cho, C., Samkoff, L.M., 2000. A lesion of the anterior thalamus producing dystonic tremor of the hand. *Arch. Neurol.* 57, 1353–1355.

- Colosimo, C., et al., 2005. Diffusion tensor imaging in primary cervical dystonia. *J. Neurol. Neurosurg. Psychiatry* 76, 1591–1593.
- Cooper, I.S., 1976. 20-year followup study of the neurosurgical treatment of dystonia musculorum deformans. *Adv. Neurol.* 14, 423–452.
- Coria, F., et al., 2000. Pseudodystonic hand posturing contralateral to a metastasis of the parietal association cortex. *Neurologia* 15, 362–365.
- Cuny, E., et al., 2008. Sensory motor mismatch within the supplementary motor area in the dystonic monkey. *Neurobiol. Dis.* 30, 151–161.
- Daskalakis, Z.J., et al., 2004. Exploring the connectivity between the cerebellum and motor cortex in humans. *J. Physiol.* 557, 689–700.
- Davis, R., 2000. Cerebellar stimulation for cerebral palsy spasticity, function, and seizures. *Arch. Med. Res.* 31, 290–299.
- deCarvalho Aguiar, P.M., Ozelius, L.J., 2002. Classification and genetics of dystonia. *Lancet Neurol.* 1, 316–325.
- Defazio, G., et al., 2007. Do primary adult-onset focal dystonias share aetiological factors? *Brain* 130, 1183–1193.
- Delmaire, C., et al., 2005. Disorganized somatotopy in the putamen of patients with focal hand dystonia. *Neurology* 64, 1391–1396.
- Delmaire, C., et al., 2007. Structural abnormalities in the cerebellum and sensorimotor circuit in writer's cramp. *Neurology* 69, 376–380.
- Delmaire, C., et al., 2009. Diffusion abnormalities in the primary sensorimotor pathways in writer's cramp. *Arch. Neurol.* 66, 502–508.
- DeLong, M.R., Wichmann, T., 2007. Circuits and circuit disorders of the basal ganglia. *Arch. Neurol.* 64, 20–24.
- Detante, O., et al., 2004. Globus pallidus internus stimulation in primary generalized dystonia: a  $H_2^{15}O$  PET study. *Brain* 127, 1899–1908.
- Doya, K., 2000. Complementary roles of basal ganglia and cerebellum in learning and motor control. *Curr. Opin. Neurobiol.* 10, 732–739.
- Draganski, B., May, A., 2008. Training-induced structural changes in the adult human brain. *Behav. Brain Res.* 192, 137–142.
- Draganski, B., et al., 2003. Motor circuit gray matter changes in idiopathic cervical dystonia. *Neurology* 61, 1228–1231.
- Draganski, B., et al., 2009. Genotype-phenotype interactions in primary dystonias revealed by differential changes in brain structure. *Neuroimage* 47, 1141–1147.
- Dragasevic, N.T., et al., 2006. Frequency analysis and clinical characterization of different types of spinocerebellar ataxia in Serbian patients. *Mov. Disord.* 21, 187–191.
- Dresel, C., et al., 2006. Silent event-related fMRI reveals deficient motor and enhanced somatosensory activation in orofacial dystonia. *Brain* 129, 36–46.
- Dubinsky, R.M., et al., 1993. Essential tremor and dystonia. *Neurology* 43, 2382–2384.
- Egger, K., et al., 2007. Voxel based morphometry reveals specific gray matter changes in primary dystonia. *Mov. Disord.* 22, 1538–1542.
- Eidelberg, D., et al., 1995. The metabolic topography of idiopathic torsion dystonia. *Brain* 118, 1473–1484.
- Eidelberg, D., et al., 1998. Functional brain networks in DYT1 dystonia. *Ann. Neurol.* 44, 303–312.
- Elbert, T., et al., 1998. Alteration of digital representations in somatosensory cortex in focal hand dystonia. *NeuroReport* 9, 3571–3575.
- Emoto, H., et al., 2010. Photophobia in essential blepharospasm—a positron emission tomographic study. *Mov. Disord.* 25, 433–439.
- Etgen, T., et al., 2006. Bilateral grey-matter increase in the putamen in primary blepharospasm. *J. Neurol. Neurosurg. Psychiatry* 77, 1017–1020.
- Fabbrini, G., et al., 2008. Diffusion tensor imaging in patients with primary cervical dystonia and in patients with blepharospasm. *Eur. J. Neurol.* 15, 185–189.
- Fahn, S., 1984. The varied clinical expressions of dystonia. *Neurol. Clin.* 2, 541–554.
- Fahn, S., 1988. Concept and classification of dystonia. *Adv. Neurol.* 50, 8–Jan.
- Farshadmanesh, F., et al., 2007. Three-dimensional eye-head coordination after injection of muscimol into the interstitial nucleus of Cajal (INC). *J. Neurophysiol.* 97, 2322–2338.
- Feiwell, R.J., et al., 1999. Diminished regional cerebral blood flow response to vibration in patients with blepharospasm. *Neurology* 52, 291–297.
- Fernagut, P.O., et al., 2002. Subacute systemic 3-nitropropionic acid intoxication induces a distinct motor disorder in adult C57BL/6 mice: behavioural and histopathological characterisation. *Neuroscience* 114, 1005–1017.
- Fletcher, N.A., et al., 1988. Degenerative cerebellar ataxia and focal dystonia. *Mov. Disord.* 3, 336–342.
- Fletcher, C.F., et al., 1996. Absence epilepsy in tottering mutant mice is associated with calcium channel defects. *Cell* 87, 607–617.
- Fletcher, C.F., et al., 2001. Dystonia and cerebellar atrophy in *Cacna1a* null mice lacking P/Q calcium channel activity. *FASEB J.* 5–Mar.
- Fukaya, C., et al., 2007. Thalamic deep brain stimulation for writer's cramp. *J. Neurosurg.* 107, 977–982.
- Fukushima, K., 1987. The interstitial nucleus of Cajal and its role in the control of movements of the head and eyes. *Prog. Neurobiol.* 29, 107–192.
- Galardi, G., et al., 1996. Basal ganglia and thalamo-cortical hypermetabolism in patients with spasmodic torticollis. *Acta Neurol. Scand.* 94, 172–176.
- Garcia-Ruiz, P., et al., 1992. Parkinsonism associated with calcium channel blockers: a prospective follow-up study. *Clin. Neuropharmacol.* 15, 19–26.
- Garraux, G., et al., 2004. Changes in brain anatomy in focal hand dystonia. *Ann. Neurol.* 55, 736–739.
- Geyer, H.L., Bressman, S.B., 2006. The diagnosis of dystonia. *Lancet Neurol.* 5, 780–790.
- Ghika, J., et al., 1994. The “jerky dystonic unsteady hand”: a delayed motor syndrome in posterior thalamic infarctions. *J. Neurol.* 241, 537–542.
- Ghika, J., et al., 1998. Parietal motor syndrome: a clinical description in 32 patients in the acute phase of pure parietal strokes studied prospectively. *Clin. Neurol. Neurosurg.* 100, 271–282.
- Ghorayeb, I., et al., 2002. Dystonia is predictive of subsequent altered dopaminergic responsiveness in a chronic 1-methyl-4-phenyl-1, 2, 3, 6-tetrahydropyridine + 3-nitropropionic acid model of striatonigral degeneration in monkeys. *Neurosci. Lett.* 335, 34–38.
- Goldhahn, G., Goldhahn, W.E., 1977. Die Ergebnisse stereotaktischer Hirnoperationen beim Torticollis spasmodicus. *Zentralbl. Neurochir.* 38, 87–96.
- Goto, S., et al., 2005. Functional anatomy of the basal ganglia in X-linked recessive dystonia-parkinsonism. *Ann. Neurol.* 58, 7–17.
- Goto, S., et al., 2008. Thalamic Vo-complex vs pallidal deep brain stimulation for focal hand dystonia. *Neurology* 70, 1500–1501.
- Goyal, V., Behari, M., 2002. Dystonia as presenting manifestation of ataxia telangiectasia: a case report. *Neurol. India* 50, 187–189.
- Grabli, D., et al., 2009. Interruption of deep brain stimulation of the globus pallidus in primary generalized dystonia. *Mov. Disord.* 24, 2363–2369.
- Granert, O., et al., 2010. Manual activity shapes structure and function in contralateral human motor hand area. *Neuroimage* 54, 32–41.
- Grey, E.G., 1916. Studies on the localization of cerebellar tumors. *Ann. Surg.* 63, 129–139.
- Gross, R., 2008. What happened to posteroventral pallidotomy for Parkinson's disease and dystonia? *NeuroRx* 5, 281–293.
- Guehl, D., et al., 2009. Primate models of dystonia. *Prog. Neurobiol.* 87, 118–131.
- Hagenah, J.M., et al., 2004. Focal dystonia as a presenting sign of spinocerebellar ataxia 17. *Mov. Disord.* 19, 217–220.
- Hallett, M., 2006. Pathophysiology of dystonia. *J. Neural Transm. Suppl.* 70, 485–488.
- Hammond, G.W., 1890. Original case of athetosis. *J. Nerv. Ment. Dis.* 17, 555–556.
- Haslinger, B., et al., 2005. “Silent event-related” fMRI reveals reduced sensorimotor activation in laryngeal dystonia. *Neurology* 65, 1562–1569.
- Haslinger, B., et al., 2010. Sensorimotor overactivity as a pathophysiologic trait of embouchure dystonia. *Neurology* 74, 1790–1797.
- Hedera, P., et al., 2010. Clustering of dystonia in some pedigrees with autosomal dominant essential tremor suggests the existence of a distinct subtype of essential tremor. *BMC Neurol.* 10, 66.
- Hedreen, J.C., et al., 1988. Primary dystonias: a review of the pathology and suggestions for new directions of study. In: Fahn, S., et al. (Ed.), *Advances in Neurology: Dystonia*, 2, pp. 123–132.
- Herz, E., 1944. Dystonias, part 3: pathology and conclusions. *Arch. Neurol. Psychiatry* 52, 20.
- Hess, E.J., Jinnah, H.A., 2005. Mouse models of dystonia. In: Le Douarin, M.S. (Ed.), *Animal Models of Movement Disorders*. Elsevier Academic Press, San Diego, pp. 265–277.
- Hess, E.J., et al., 2010. Neuronal voltage-gated calcium channels: brief overview of their function and clinical implications in neurology. *Neurology* 75, 937–938.
- Hitchcock, E., 1973. Dentate lesions for involuntary movement. *Proc. R. Soc. Med.* 66, 877–879.
- Hoshi, E., et al., 2005. The cerebellum communicates with the basal ganglia. *Nat. Neurosci.* 8, 1491–1493.
- Hou, J.G., Jankovic, J., 2003. Movement disorders in Friedreich's ataxia. *J. Neurol. Sci.* 206, 59–64.
- Hu, X.Y., et al., 2006. Functional magnetic resonance imaging study of writer's cramp. *Chin. Med. J.* 119, 1263–1271.
- Hutchinson, M., et al., 2000. The metabolic topography of essential blepharospasm. *Neurology* 55, 673–677.
- Ibanez, V., et al., 1999. Deficient activation of the motor cortical network in patients with writer's cramp. *Neurology* 53, 96–105.
- Ichinohe, N., et al., 2000. A di-synaptic projection from the lateral cerebellar nucleus to the laterodorsal part of the striatum via the central lateral nucleus of the thalamus in the rat. *Brain Res.* 880, 191–197.
- Ikeuchi, T., et al., 1997. Spinocerebellar ataxia type 6: CAG repeat expansion in alpha1A voltage-dependent calcium channel gene and clinical variations in Japanese population. *Ann. Neurol.* 42, 879–884.
- Islam, T., et al., 2009. Decreased bilateral cortical representation patterns in writer's cramp: a functional magnetic resonance imaging study at 3.0 T. *Neurol. Sci.* 30, 219–226.
- Jacob, P.C., Chand, R.P., 1995. Blepharospasm and jaw closing dystonia after parietal infarcts. *Mov. Disord.* 10, 794–795.
- Jankovic, J., Tintner, R., 2001. Dystonia and parkinsonism. *Parkinsonism Relat. Disord.* 8, 109–121.
- Jankovic, J., et al., 1991. Cervical dystonia: clinical findings and associated movement disorders. *Neurology* 41, 1088–1091.
- Jardim, L.B., et al., 2001. Neurological findings in Machado-Joseph disease. *Arch. Neurol.* 58, 899–904.
- Jinnah, H.A., Hess, E.J., 2006. A new twist on the anatomy of dystonia: the basal ganglia and the cerebellum. *Neurology* 67, 1740–1741.
- Jinnah, H.A., Hess, E.J., 2008. Experimental therapeutics for dystonia. *Neurotherapeutics* 5, 198–209.
- Jinnah, H.A., et al., 2005. Rodent models for dystonia research: characteristics, evaluation, and utility. *Mov. Disord.* 20, 283–292.
- Kadota, H., et al., 2010. An fMRI study of musicians with focal dystonia during tapping tasks. *J. Neurol.* 257, 1092–1098.
- Karbe, H., et al., 1992. Positron emission tomography demonstrates frontal cortex and basal ganglia hypometabolism in dystonia. *Neurology* 42, 1540–1544.
- Kerrison, J.B., et al., 2003. Positron emission tomography scanning in essential blepharospasm. *Am. J. Ophthalmol.* 136, 846–852.
- Khan, A.A., Sussman, J.D., 2004. Focal dystonia after removal of a parietal meningioma. *Mov. Disord.* 19, 714–716.
- Kim, J.S., 2001. Delayed onset mixed involuntary movements after thalamic stroke. *Brain* 124, 299–309.



- Kim, J.W., Lee, P.H., 2007. Dystonic head tremor associated with a parietal lesion. *Eur. J. Neurol.* 14, e32–e33.
- Klier, E.M., et al., 2002. Midbrain control of three-dimensional head orientation. *Science* 295, 1314–1316.
- Klier, E.M., et al., 2007. Interstitial nucleus of Cajal encodes three-dimensional head orientations in Fick-like coordinates. *J. Neurophysiol.* 97, 604–617.
- Krack, P., Vercueil, L., 2001. Review of the functional surgical treatment of dystonia. *Eur. J. Neurol.* 8, 389–399.
- Krauss, J.K., et al., 1991. Hemidystonia due to a contralateral parieto-occipital metastasis: disappearance after removal of the mass lesion. *Neurology* 41, 1519–1520.
- Krauss, J.K., et al., 1997. Cervical dystonia associated with tumors of the posterior fossa. *Mov. Disord.* 12, 443–447.
- Krystkowiak, P., et al., 1998. Dystonia after striatopallidal and thalamic stroke: clinico-radiological correlations and pathophysiological mechanisms. *J. Neurol. Neurosurg. Psychiatry* 65, 703–708.
- Kumandas, S., et al., 2006. Torticollis secondary to posterior fossa and cervical spinal cord tumors: report of five cases and literature review. *Neurosurg. Rev.* 29, 333–338.
- Kuoppamaki, M., et al., 2003. Slowly progressive cerebellar ataxia and cervical dystonia: clinical presentation of a new form of spinocerebellar ataxia? *Mov. Disord.* 18, 200–206.
- Le Ber, I., et al., 2006. Predominant dystonia with marked cerebellar atrophy: a rare phenotype in familial dystonia. *Neurology* 67, 1769–1773.
- LeDoux, M.S., Brady, K.A., 2002. Secondary cervical dystonia associated with structural lesions of the central nervous system. *Mov. Disord.* 18, 60–69.
- LeDoux, M.S., et al., 1993. Cerebellectomy eliminates the motor syndrome of the genetically dystonic rat. *Exp. Neurol.* 120, 302–310.
- LeDoux, M.S., et al., 1995. Selective elimination of cerebellar output in the genetically dystonic rat. *Brain Res.* 697, 91–103.
- LeDoux, M.S., et al., 1998. Single-unit activity of cerebellar nuclear cells in the awake genetically dystonic rat. *Neuroscience* 86, 533–545.
- Lee, M.S., Marsden, C.D., 1995. Movement disorders following lesions of the thalamus or subthalamic region. *Mov. Disord.* 9, 493–507.
- Lehericy, S., et al., 1996. Striatopallidal and thalamic dystonia. *Arch. Neurol.* 53, 241–250.
- Lehericy, S., et al., 2001. Clinical characteristics and topography of lesion in movement disorders due to thalamic lesions. *Neurology* 57, 1055–1066.
- Lehericy, S., et al., 2004. Motor execution and imagination networks in post-stroke dystonia. *NeuroReport* 15, 1887–1890.
- Lenz, F.A., et al., 1990. Thalamic single-unit activity occurring in patients with hemidystonia. *Stereotact. Funct. Neurosurg.* 54–55, 159–162.
- Lerner, A., et al., 2004. Regional cerebral blood flow correlates of the severity of writer's cramp symptoms. *Neuroimage* 21, 904–913.
- Liepert, J., et al., 2004. Motor cortex excitability after cerebellar infarction. *Stroke* 35, 2484–2488.
- Lin, P.T., Hallett, M., 2009. The pathophysiology of focal hand dystonia. *J. Hand Ther.* 22, 109–113.
- Loher, T.J., Krauss, J.K., 2008. Dystonia associated with pontomesencephalic lesions. *Mov. Disord.* 24, 157–167.
- Loher, T.J., et al., 2004. Functional stereotactic surgery for treatment of cervical dystonia: review of the experience from the lesional era. *Stereotact. Funct. Neurosurg.* 82, 1–13.
- Lorden, J.F., et al., 1984. Characterization of the rat mutant dystonic (dt): a new animal model of dystonia musculorum deformans. *J. Neurosci.* 4, 1925–1932.
- Lorden, J.F., et al., 1992. Abnormal cerebellar output in rats with an inherited movement disorder. *Exp. Neurol.* 118, 95–104.
- Louis, E.D., et al., 1999. Dystonia in Huntington's disease: prevalence and clinical characteristics. *Mov. Disord.* 14, 95–101.
- Luft, A.R., et al., 2005. Modulation of motor cortex excitability by sustained peripheral stimulation: the interaction between the motor cortex and the cerebellum. *Cerebellum* 4, 90–96.
- Magyar-Lehman, S., et al., 1997. Cerebral glucose metabolism in patients with spasmodic torticollis. *Mov. Disord.* 12, 704–708.
- Mano, M., et al., 1993. Roles of Cerebellum and Basal Ganglia in Voluntary Movement. Elsevier, Amsterdam.
- Marks, W.J.J., 2007. Brain surgery for dystonia. In: Stacey, M.A. (Ed.), *Handbook of Dystonia*. Informa Healthcare USA, Inc., New York, pp. 393–406.
- Marsden, C.D., 1976. The problem of adult-onset idiopathic torsion dystonia and other isolated dyskinesias in adult life (including blepharospasm, oromandibular dystonia, dystonic writer's cramp, and torticollis, or axial dystonia). *Adv. Neurol.* 14, 259–276.
- Marsden, C.D., et al., 1985. The anatomical basis of symptomatic dystonia. *Brain* 108, 463–483.
- McFarland, N.R., Haber, S.N., 2000. Convergent inputs from thalamic motor nuclei and frontal cortical areas to the dorsal striatum in the primate. *J. Neurosci.* 20, 3798–3813.
- McGeer, E.G., McGeer, P.L., 1988. The dystonias. *Can. J. Neurol. Sci.* 15, 447–483.
- McGeer, E.G., McGeer, P.L., 1995. Pathology of Dystonias. In: Tsui, J.K.C., Calne, D.B. (Eds.), *Handbook of dystonia*. Marcel Dekker, New York, pp. 77–102.
- Meunier, S., et al., 2001. Human brain mapping in dystonia reveals both endophenotypic traits and adaptive reorganization. *Ann. Neurol.* 50, 521–527.
- Meunier, S., et al., 2003. Dystonia: lessons from brain mapping. *Neuroscientist* 9, 76–81.
- Miki, T., et al., 2008. Two novel alleles of tottering with distinct Ca(v)2.1 calcium channel neuropathologies. *Neuroscience* 155, 31–44.
- Mink, J.W., 2003. The basal ganglia and involuntary movements. *Arch. Neurol.* 60, 1365–1368.
- Miwa, H., et al., 1996. Thalamic tremor: case reports and implications of the tremor-generating mechanism. *Neurology* 46, 75–79.
- Morishita, T., et al., 2010. Should we consider Vim thalamic deep brain stimulation for select cases of severe refractory dystonic tremor. *Stereotact. Funct. Neurosurg.* 88, 98–104.
- Morris, J.G., et al., 2002. Athetosis I: historical considerations. *Mov. Disord.* 17, 1278–1280.
- Munchau, A., et al., 1999. Machado-Joseph disease presenting as severe generalised dystonia in a German patient. *J. Neurol.* 246, 840–842.
- Munts, A.G., Koehler, P.J., 2010. How psychogenic is dystonia? Views from past to present. *Brain* 133, 1552–1564.
- Muzaimi, M.B., et al., 2003. Task specific focal dystonia: a presentation of spinocerebellar ataxia type 6. *J. Neurol. Neurosurg. Psychiatry* 74, 1444–1445.
- Nashold, B.S., Slaughter, D.G., 1969. Effects of stimulating or destroying the deep cerebellar regions in man. *J. Neurosurg.* 31, 173–186.
- Naumann, M., et al., 2000. Sensory tricks in cervical dystonia: perceptual dysbalance of parietal cortex modulates frontal motor programming. *Ann. Neurol.* 47, 322–328.
- Nelson, A.J., et al., 2009. Digit-specific aberrations in the primary somatosensory cortex in Writer's cramp. *Ann. Neurol.* 66, 146–154.
- Nemeth, A.H., 2002. The genetics of primary dystonias and related disorders. *Brain* 125, 695–721.
- Neychev, V., et al., 2008. The basal ganglia and cerebellum interact in the expression of dystonic movement. *Brain* 131, 2499–2509.
- Nieoullon, A., et al., 1978. Release of dopamine in both caudate nuclei and both substantia nigrae in response to unilateral stimulation of cerebellar nuclei in the cat. *Brain Res.* 148, 143–152.
- Niethammer, M., et al., in press. Hereditary dystonia as a neurodevelopmental circuit disorder: evidence from neuroimaging. *Neurobiol. Dis.*
- Obermann, M., et al., 2007. Morphometric changes of sensorimotor structures in focal dystonia. *Mov. Disord.* 22, 1117–1123.
- Obeso, J.A., Gimenez-Roldan, S., 1988. Clinicopathologic correlation in symptomatic dystonia. *Adv. Neurol.* 50, 113–122.
- Odergren, T., et al., 1998. Cerebral and cerebellar activation in correlation to the action-induced dystonia in writer's cramp. *Mov. Disord.* 13, 497–508.
- Oga, T., et al., 2002. Abnormal cortical mechanisms of voluntary muscle relaxation in patients with writer's cramp: an fMRI study. *Brain* 125, 895–903.
- O'Rourke, K., et al., 2006. Paroxysmal torticollis and blepharospasm following bilateral cerebellar infarction. *J. Neurol.* 253, 1644–1645.
- Ostrem, J.L., Starr, P., 2008. Treatment of dystonia with deep brain stimulation. *Neurotherapeutics* 5, 320–330.
- Otsuka, M., et al., 1992. Increased striatal 18F-dopa uptake and normal glucose metabolism in idiopathic dystonia syndrome. *J. Neurol. Sci.* 111, 195–199.
- Oulad Be Taib, N., et al., 2005. The cerebellum modulates rodent cortical motor output after repetitive somatosensory stimulation. *Neurosurgery* 56, 811–820.
- Page, S.J., et al., 2009. Cortical plasticity following motor skill learning during mental practice in stroke. *Neurorehabil. Neural Repair* 23, 382–388.
- Pal, P.K., et al., 2000. Head tremor in cervical dystonia. *Can. J. Neurol. Sci.* 27, 137–142.
- Palfi, S., et al., 1996. Chronic 3-nitropropionic acid treatment in baboons replicates the cognitive and motor deficits of Huntington's disease. *J. Neurosci.* 16, 3019–3025.
- Pantano, P., et al., 2010. A transverse and longitudinal MR imaging voxel-based morphometry study in patients with primary cervical dystonia. *AJNR Am. J. Neuroradiol.* 32, 84–81.
- Pastor, M.A., et al., 2004. The functional neuroanatomy of temporal discrimination. *J. Neurosci.* 24, 2585–2591.
- Peller, M., et al., 2006. The basal ganglia are hyperactive during the discrimination of tactile stimuli in writer's cramp. *Brain* 129, 2697–2708.
- Perlmuter, J.S., Mink, J.W., 2004. Dysfunction of dopaminergic pathways in dystonia. *Adv. Neurol.* 94, 163–170.
- Perlmuter, J.S., Mink, J.W., 2006. Deep brain stimulation. *Annu. Rev. Neurosci.* 29, 229–257.
- Perlmuter, J.S., Thach, W.T., 2007. Writer's cramp: questions of causation. *Neurology* 69, 331–332.
- Perlmuter, J.S., et al., 1997. MPTP induces dystonia and parkinsonism. Clues to the pathophysiology of dystonia. *Neurology* 49, 1432–1438.
- Persing, J.A., et al., 1990. Blepharospasm-omandibular dystonia associated with a left cerebellopontine angle meningioma. *J. Emerg. Med.* 8, 571–574.
- Peterson, D.A., et al., 2010. Convergent evidence for abnormal striatal synaptic plasticity in dystonia. *Neurobiol. Dis.* 37, 558–573.
- Pettigrew, L.C., Jankovic, J., 1985. Hemidystonia: a report of 22 patients and a review of the literature. *J. Neurol. Neurosurg. Psychiatry* 48, 650–657.
- Pizzoli, C.E., et al., 2002. Abnormal cerebellar signaling induces dystonia in mice. *J. Neurosci.* 22, 7825–7833.
- Playford, E.D., et al., 1998. Increased activation of frontal areas during arm movement in idiopathic torsion dystonia. *Mov. Disord.* 13, 309.
- Preibisch, C., et al., 2001. Cerebral activation patterns in patients with writer's cramp: a functional magnetic resonance imaging study. *J. Neurol.* 248 17–Oct.
- Pujol, J., et al., 2000. Brain cortical activation during guitar-induced hand dystonia studied by functional MRI. *Neuroimage* 12, 257–267.
- Quartarone, A., et al., 2006. Task-specific hand dystonia: can too much plasticity be bad for you? *Trends Neurosci.* 29, 192–199.
- Quartarone, A., et al., 2008. Clinical features of dystonia: a pathophysiological re-evaluation. *Curr. Opin. Neurol.* 21, 484–490.
- Raike, R.S., et al., 2005. Animal models of generalized dystonia. *NeuroRx* 2, 504–512.
- Restuccia, D., et al., 2001. Functional changes of the primary somatosensory cortex in patients with unilateral cerebellar lesions. *Brain* 124, 757–768.
- Richter, A., Loscher, W., 1998. Pathology of idiopathic dystonia: findings from genetic animal models. *Prog. Neurobiol.* 54, 633–677.



- Rivest, J., et al., 1990. Dystonia in Parkinson's disease, multiple system atrophy, and progressive supranuclear palsy. *Neurology* 40, 1571–1578.
- Rondot, P., et al., 1991. Spasmodic torticollis—review of 220 patients. *Can. J. Neurol. Sci.* 18, 143–151.
- Rosenow, J., et al., 2002. Irving S. Cooper and his role in intracranial stimulation for movement disorders and epilepsy. *Stereotact. Funct. Neurosurg.* 78, 95–112.
- Rossi, S., et al., 2008. Cerebellar control of cortico-striatal LTD. *Restor. Neurol. Neurosci.* 26, 475–480.
- Rothwell, J.C., Huang, Y.Z., 2003. Systems-level studies of movement disorders in cases of torticollis and see-saw nystagmus. *Curr. Opin. Neurobiol.* 13, 691–695.
- Rousseaux, M., et al., 1996. Dystonie et tremblement dans une lesion bilaterale du mesencephale posterieur et du vermis. *Rev. Neurol. (Paris)* 152, 732–737.
- Rumbach, L., et al., 1995. Hemidystonia consequent upon ipsilateral vertebral artery occlusion and cerebellar infarction. *Mov. Disord.* 10, 522–525.
- Salam-Adams, M., Adams, R.D., 1997. Athetotic syndromes. In: Vinken, P.J., et al. (Ed.), *Handbook of Clinical Neurology*. : Extrapyrimal Disorders, 49. Elsevier Science Publishers, Amsterdam, pp. 381–389.
- Sano, K., et al., 1972. Stimulation and destruction of the region of the interstitial nucleus in dystonia and Parkinson's disease. *Confin. Neurol.* 34, 331–338.
- Schicatanu, E.J., et al., 1997. Animal model explains the origins of the cranial dystonia benign essential blepharospasm. *J. Neurophysiol.* 77, 2842–2846.
- Schmidt, K.E., et al., 2003. Striatal activation during blepharospasm revealed by fMRI. *Neurology* 60, 1738–1743.
- Schneider, S.A., et al., 2009. Complicated recessive dystonia parkinsonism syndromes. *Mov. Disord.* 24, 490–499.
- Schneider, S.A., et al., 2010. Modulatory effects of 5Hz rTMS over the primary somatosensory cortex in focal dystonia—an fMRI-TMS study. *Mov. Disord.* 25, 76–83.
- Scholle, H.C., et al., 2010. Kinematic and electromyographic tools for characterizing movement disorders in mice. *Mov. Disord.* 25, 265–274.
- Schols, L., et al., 2000. Extrapyrimal motor signs in degenerative ataxias. *Arch. Neurol.* 57, 1495–1500.
- Scott, B.L., Jankovic, J., 1996. Delayed-onset progressive movement disorders after static brain lesions. *Neurology* 46, 68–74.
- Sethi, K.D., Jankovic, J., 2002. Dystonia in spinocerebellar ataxia type 6. *Mov. Disord.* 17, 150–153.
- Shirley, T.L., et al., 2008. Paroxysmal dyskinesias in mice. *Mov. Disord.* 23, 259–264.
- Simonyan, K., Ludlow, C.L., 2010. Abnormal activation of the primary somatosensory cortex in spasmodic dysphonia: an fMRI study. *Cereb. Cortex* 20, 2749–2759.
- Simonyan, K., et al., 2008. Focal white matter changes in spasmodic dysphonia: a combined diffusion tensor imaging and neuropathological study. *Brain* 131, 447–459.
- Snider, R.S., et al., 1976. Cerebellar pathways to ventral midbrain and nigra. *Exp. Neurol.* 53, 714–728.
- Stein, J.F., Aziz, T.Z., 1999. Does imbalance between basal ganglia and cerebellar output cause movement disorders? *Curr. Opin. Neurol.* 12, 667–669.
- Stejskal, L., et al., 1981. Surgical possibilities for alleviation of axial dyskinesias—comparison with forced movements of the head and eyes. *Appl. Neurophysiol.* 44, 320–329.
- Stoessl, A.J., et al., 1986. PET studies of cerebral glucose metabolism in idiopathic torticollis. *Neurology* 36, 653–657.
- Suzuki, Y., et al., 2007. Glucose hypermetabolism in the thalamus of patients with essential blepharospasm. *J. Neurol.* 254, 890–896.
- Tabbal, S.D., et al., 2006. 1-methyl-4-phenyl-1, 2, 3, 6-tetrahydropyridine-induced acute transient dystonia in monkeys with low striatal dopamine. *Neuroscience* 141, 1281–1287.
- Tamburin, S., et al., 2004. Enhanced intracortical inhibition in cerebellar patients. *J. Neurol. Sci.* 217, 205–210.
- Tarsy, D., Simon, D.K., 2006. Dystonia. *N. Engl. J. Med.* 355, 818–829.
- Tellerman, K., et al., 1979. Cerebellar control of catecholaminergic activities: implications for drug therapy of movement disorders. *Int. J. Neurol.* 12, 135–155.
- Tempel, L.W., Perlmutter, J.S., 1990. Abnormal vibration-induced cerebral blood flow responses in idiopathic dystonia. *Brain* 113, 691–707.
- Teo, J.T., et al., 2009. Neurophysiological evidence for cerebellar dysfunction in primary focal dystonia. *J. Neurol. Neurosurg. Psychiatry* 80, 80–83.
- Thobois, S., et al., 2008. Globus pallidus stimulation reduces frontal hyperactivity in tardive dystonia. *J. Cereb. Blood Flow Metab.* 28, 1127–1138.
- Thompson, R.F., Steinmetz, J.E., 2009. The role of the cerebellum in classical conditioning of discrete behavioral responses. *Neuroscience* 162, 732–755.
- Tinazzi, M., et al., 2009. Sensory functions in dystonia: insights from behavioral studies. *Mov. Disord.* 24, 1427–1436.
- Tokuda, S., et al., 2007. The ataxic groggy rat has a missense mutation in the P/Q-type voltage-gated Ca<sup>2+</sup> channel  $\alpha 1A$  subunit gene and exhibits absence seizures. *Brain Res.* 1133, 168–177.
- Tolosa, E., Compta, Y., 2006. Dystonia in Parkinson's disease. *J. Neurol.* 253 (Suppl. 7), 7–13.
- Tranchant, C., et al., 1991. Angiome caverneux cerebelleux, dystonie cervicale et diaschisis cortical croise. *Rev. Neurol. (Paris)* 147, 599–602.
- Troiano, A.R., Stoessl, A.J., 2008. Neuroimaging in dystonia. In: Stacey, M.A. (Ed.), *Handbook of Dystonia*. Informa Healthcare, Inc., New York, pp. 93–106.
- Trost, M., et al., 2002. Primary dystonia: is abnormal functional brain architecture linked to genotype? *Ann. Neurol.* 52, 853–856.
- Turgut, M., et al., 1995. Acquired torticollis as the only presenting symptom in children with posterior fossa tumors. *Childs Nerv. Syst.* 11, 86–88.
- Twitcheil, T.E., 1961. The nature of the motor deficit in double athetosis. *Arch. Phys. Med. Rehabil.* 63–67.
- Valls-Sole, J., et al., 1997. Neurophysiological investigations in patients with head tremor. *Mov. Disord.* 12, 576–584.
- Vasin, N., et al., 1985. Stereotaxic destruction of the interstitial nucleus of Cajal on spastic torticollis. *Zh. Vopr. Neirokhir. Im. NN Burdenko* 3–7.
- Vercueil, L., 2003. Fifty years of brain surgery for dystonia: revisiting the Irving S. Cooper's legacy, and looking forward. *Acta Neurol. Belg.* 103, 125–128.
- Verhagen, M.M., et al., 2009. Clinical spectrum of ataxia-telangiectasia in adulthood. *Neurology* 73, 430–437.
- Vidailhet, M., et al., 1999. Dopaminergic dysfunction in midbrain dystonia. *Arch. Neurol.* 56, 982–989.
- Waberski, T.D., et al., 2007. Short-term cortical reorganization by deafferentation of the contralateral sensory cortex. *NeuroReport* 18, 1199–1203.
- Wilder-Smith, E., et al., 2003. Spinocerebellar ataxia type 3 presenting as an L-DOPA responsive dystonia phenotype in a Chinese family. *J. Neurol. Sci.* 213, 25–28.
- Wimmer, A., 1929. Le spasme de torsion. *Rev. Neurol. (Paris)* 36, 904–915.
- Winkler, C., et al., 2002. L-DOPA-induced dyskinesias in the intrastriatal 6-hydroxydopamine model of Parkinson's disease: relation to motor and cellular parameters of nigrostriatal function. *Neurobiol. Dis.* 10, 165–186.
- Woods, C.G., Taylor, A.M., 1992. Ataxia telangiectasia in the British Isles: the clinical and laboratory features of 70 affected individuals. *Q. J. Med.* 82, 169–179.
- Wu, Y.R., et al., 2004. Dystonia as a presenting sign of spinocerebellar ataxia type 1. *Mov. Disord.* 19, 586–587.
- Wu, C.C., et al., 2010. Impaired sensorimotor integration in focal hand dystonia patients in the absence of symptoms. *J. Neurol. Neurosurg. Psychiatry* 81, 659–665.
- Xiao, J., Ledoux, M.S., 2005. Caytaxin deficiency causes generalized dystonia in rats. *Brain Res. Mol. Brain Res.* 141, 181–192.
- Xie, G., et al., 2007. Forward genetic screen of mouse reveals dominant missense mutation in the P/Q-type voltage-dependent calcium channel, CACNA1A. *Genes Brain Behav.* 6, 717–727.
- Yianni, J., et al., 2005. Effect of GPI DBS on functional imaging of the brain in dystonia. *J. Clin. Neurosci.* 12, 137–141.
- Zadro, I., et al., 2008. Cervical dystonia due to cerebellar stroke. *Mov. Disord.* 23, 919–920.
- Zeman, W., 1970. Pathology of the torsion dystonias (dystonia musculorum deformans). *Neurology* 20, 79–88.